

GUIDELINES AND STANDARDS

Guidelines for the Evaluation of Valvular Regurgitation After Percutaneous Valve Repair or Replacement

A Report from the American Society of Echocardiography Developed in Collaboration with the Society for Cardiovascular Angiography and Interventions, Japanese Society of Echocardiography, and Society for Cardiovascular Magnetic Resonance

William A. Zoghbi, MD, FASE, (Chair), Federico M. Asch, MD, FASE, Charles Bruce, MBChB, FASE, Linda D. Gillam, MD, MPH, FASE, Paul A. Grayburn, MD, FASE, Rebecca T. Hahn, MD, FASE, Ignacio Inglessis, MD, Ashequl M. Islam, MD, MPH, FSCAI, Stamatios Lerakis, MD, FASE, Stephen H. Little, MD, FASE, Robert J. Siegel, MD, FASE, Nikolaos Skubas, MD, DSc, FASE, Timothy C. Slesnick, MD, FASE, William J. Stewart, MD, FASE, Paaladinesh Thavendiranathan, MD, MSc, FASE, Neil J. Weissman, MD, FASE, Satoshi Yasukochi, MD, JCC, SJSUM, and Karen G. Zimmerman, BS, ACS, RDCS, RVT, FASE, *Houston and Dallas, Texas; Washington, District of Columbia; Rochester, Minnesota; Morristown, New Jersey; New York, New York; Boston and Springfield, Massachusetts; Los Angeles, California; Cleveland, Ohio; Atlanta, Georgia; Toronto, Ontario, Canada; Nagano, Japan; Morgantown, West Virginia*

Keywords: Doppler echocardiography, Valve disease, Transaortic valve replacement, Magnetic resonance imaging, Aortic regurgitation, Mitral regurgitation

In addition to the collaborating societies listed in the title, this document is endorsed by the following American Society of Echocardiography International Alliance Partners: Argentine Society of Cardiology, Argentinian Federation of Cardiology, Asian-Pacific Association of Echocardiography, Australasian Sonographers Association, Cardiovascular Imaging Department of the Brazilian Society of Cardiology, Canadian Society of Echocardiography, Chinese Society of Echocardiography, Echocardiography Section of the Cuban Society of Cardiology, Indian Academy of Echocardiography, Indian Association of Cardiovascular Thoracic Anaesthesiologists, Indonesian Society of Echocardiography, InterAmerican Association of Echocardiography, Iranian Society of Echocardiography, Israeli Working Group on Echocardiography, Italian Association of CardioThoracic and Vascular Anaesthesia and Intensive Care, Mexican Society of Echocardiography and Cardiovascular Imaging, National Association of Cardiologists of Mexico, National Society of Echocardiography of Mexico, Saudi Arabian Society of Echocardiography, Thai Society of Echocardiography, and Venezuelan Society of Cardiology.

From Houston Methodist Hospital, Houston, Texas (W.A.Z. and S.H.L.); MedStar Health Research Institute, Washington, District of Columbia (F.M.A. and N.J.W.); Mayo Clinic, Rochester, Minnesota (C.B.); Morristown Medical Center, Morristown, New Jersey (L.D.G.); Baylor University Medical Center, Dallas, Texas (P.A.G.); Columbia University Medical Center, New York, New York (R.T.H.); Massachusetts General Hospital, Boston, Massachusetts (I.I.); Baystate Medical Center, Springfield, Massachusetts (A.M.I.); Icahn School of Medicine at Mount Sinai, New York, New York (S.L.); Emory University School of Medicine, Atlanta, Georgia (T.C.S.); Cedars-Sinai Medical Center, Los Angeles, California (R.J.S.); Cleveland Clinic, Cleveland, Ohio (N.S. and W.J.S.); University of Toronto, Toronto, Ontario, Canada (P.T.); Nagano Children's Hospital, Nagano, Japan (S.Y.); West Virginia University Heart & Vascular Institute, Morgantown, West Virginia (K.G.Z.).

The following authors reported no actual or potential conflicts of interest in relation to this document: Ignacio Inglessis, MD; Nikolaos Skubas, MD, FASE, DSc; Timothy Slesnick, MD, FASE; William J. Stewart, MD, FASE; Paaladinesh Thavendiranathan, MD; Satoshi Yasukochi, MD, JCC, SJSUM; Karen G. Zimmerman, BS, ACS, RDCS, RVT, FASE. The following authors reported relationships with one or more commercial interests: Federico M. Asch, MD, FASE and Neil J. Weissman, MD, FASE have been directors of an academic core lab providing services for Edwards Lifesciences, Medtronic, Boston Scientific/Symetis, Abbott/St Jude Medical, Neovasc, Mitraign, GDS, Caisson/Livanova, Biotronik, and DirectFlow. Charles Bruce, MBChB, FASE, consulted for Edwards Lifesciences; Linda D. Gillam, MD, MPH, FASE provided core lab services for Edwards Lifesciences and Medtronic; Paul A. Grayburn, MD, FASE, consulted for Abbott Vascular, Neochord, and Tendyne and received research support from Abbott Vascular, Tendyne, Valtech, Edwards,

Medtronic, Neochord, and Boston Scientific; Rebecca T. Hahn, MD, FASE, consulted for Abbott Vascular, Edwards Lifesciences, Medtronic, Philips Healthcare, Siemens Healthineers and Gore and Associates, serves on the speaker's bureau for Abbott Vascular, Boston Scientific, Edwards Lifesciences, Philips Healthcare, Siemens Healthineers; Ashequl M. Islam, MD, MPH, FSCAI, consulted for Edwards and Medtronic; Stamatios Lerakis, MD, FASE, consulted for Edwards Lifesciences; Stephen H. Little, MD, FASE, received research support from Medtronic and Abbott Vascular, and consulted for Abbott Vascular. Robert J. Siegel, MD, FASE, served on the speaker's bureau for Abbott Vascular and Philips; William A. Zoghbi, MD, FASE, has a licensing agreement with GE Healthcare and is on the advisory board for Abbott Vascular, GE Healthcare, and Siemens Healthineers.

Reprint requests: American Society of Echocardiography, 2530 Meridian Parkway, Suite 450, Durham, NC 27713 (Email: ase@asecho.org).

Attention ASE Members:

Visit www.aseuniversity.org to earn free continuing medical education credit through an online activity related to this article. Certificates are available for immediate access upon successful completion of the activity. Nonmembers will need to join the ASE to access this great member benefit!

0894-7317/\$36.00

Copyright 2019 by the American Society of Echocardiography.

<https://doi.org/10.1016/j.echo.2019.01.003>

Abbreviations

2D	= Two-dimensional
3D	= Three-dimensional
AR	= Aortic regurgitation
AV	= Aortic valve
CD	= Color Doppler
CMR	= Cardiac magnetic resonance
CS	= Coronary sinus
CWD	= Continuous-wave Doppler
EROA	= Effective regurgitant orifice area
LA	= Left atrium
LV	= Left ventricle
LVEDP	= Left ventricular end-diastolic pressure
LVOT	= Left ventricular outflow tract
MDCT	= Multi-detector computed tomography
MR	= Mitral regurgitation
MV	= Mitral valve
MVA	= Mitral valve area
PA	= Pulmonary artery
PASP	= Pulmonary artery systolic pressure
PR	= Pulmonic regurgitation
PVR	= Paravalvular regurgitation
PWD	= Pulsed-wave Doppler
RF	= Regurgitant fraction
RV	= Right ventricle
RVol	= Regurgitant volume
RVOT	= Right ventricular outflow tract
SAVR	= Surgical aortic valve replacement
SSFP	= Steady-state free precession
TAVR	= Transcatheter aortic valve replacement
TMVR	= Transcatheter mitral valve replacement
TPVR	= Transcatheter pulmonary valve replacement
THV	= Transcatheter heart valve
TEE	= Transesophageal echocardiography
TR	= Tricuspid regurgitation
TTE	= Transthoracic echocardiography
TV	= Tricuspid valve
VCA	= Vena contracta area
VCW	= Vena contracta width
VTI	= Velocity-time integral

TABLE OF CONTENTS

I. Introduction	3
II. General Principles	3
III. Percutaneous Aortic Valve Interventions	4
A. Balloon-Expandable vs. Self-Expanding Valves	4
B. Pre-procedural Planning for TAVR and Valve-In-Surgical Valve	5
C. Implantation Technique for Routine TAVR	5
D. TTE vs. TEE in the Catheterization Laboratory	5
E. Evaluation of Valvular Regurgitation after TAVR	6
1. Aortography	6
2. Hemodynamic Assessment in the Catheterization Laboratory	6
3. Doppler Echocardiographic Assessment of AR after TAVR	10
a. Color Doppler Jet Features	10
b. Continuous-Wave and Pulsed-Wave Doppler	14
c. Quantitative Doppler Assessment of PVR Severity	14
F. Assessing Residual AR after Percutaneous Repair of Prosthetic Paravalvular Regurgitation	16
G. Integrative Approach to Assessment of AR	16
H. Role of Cardiovascular Magnetic Resonance in Evaluating AR	17
IV. Percutaneous Mitral Valve Interventions	19
A. General Considerations in Evaluating Residual MR during MV Interventions	19
B. Mitral Leaflet Repair	20
1. Edge-to-Edge MV Repair	20
2. Evaluation of Residual MR with CD Immediately after Edge-to-Edge Repair	21
3. Interaction of Mean Transvalvular Gradient and Residual MR after Edge-to-Edge Repair	22
C. Transcatheter Mitral Valve Replacement	22
1. TMVR Implantation	22
2. Evaluation of Residual MR Immediately after TMVR	23
3. Other Considerations in TMVR	24
D. Percutaneous Mitral Annuloplasty	24
1. Percutaneous MV Annuloplasty Devices	24
2. Evaluation of MR after Percutaneous Annuloplasty	25
E. Transcatheter Repair of Paravalvular Prosthetic MR	25
1. Repair of Paravalvular MR	25
2. Evaluation of Residual MR after Repair of Paravalvular MR	25
F. Evaluation of Residual MR Outside the Catheterization Laboratory after all MV Procedures	25
1. Color Doppler Imaging	26
2. CW Doppler of MR Jet	28
3. Mitral Inflow Pattern and Pressure Gradient	29
4. Pulmonary Vein Flow Pattern	29
5. Pulmonary Artery Systolic Pressure	29
6. Regurgitant Volume and Fraction	29
7. An Integrative Approach to Assessing Residual MR	30
8. Role of CMR in the Evaluation of Residual MR after Percutaneous MV Interventions	30
a. Evaluation of Residual MR	30
b. LV and LA Reverse Remodeling	32
c. When is CMR Indicated?	32
V. Percutaneous Pulmonary Valve Replacement	32
A. Description of TPVR and Assessment of Acute Results	33
B. Evaluation of Residual Regurgitation Outside the Catheterization Laboratory	33

1. Assessment of Pulmonary Regurgitation after TPVR with Echocardiography	33
2. Role of Computed Tomography in Pulmonic Regurgitation after TPVR	33
3. Role of CMR in Pulmonary Regurgitation after TPVR	35
C. Integrative Approach to Assessing Residual Pulmonic Regurgitation after TPVR	35
VI. Percutaneous Tricuspid Valve Interventions	36
A. Tricuspid Valve Repair and Annuloplasty	36
B. Assessment of Residual TR after Tricuspid Valve Interventions	36
C. Role of CMR in Assessing Residual TR after Tricuspid Valve Interventions	37
D. Integrative Approach in the Evaluation of Residual TR	38
VII. Conclusions and Future Directions	39

I. INTRODUCTION

Valvular disease remains a major cause of cardiovascular morbidity and mortality worldwide.¹ Over the past decade, catheter-based interventions in valvular disease have evolved from balloon dilation of native stenotic valves to repair of paravalvular regurgitation (PVR) with vascular plugs and more recently to valve replacement and repair. Currently-approved interventions include transcatheter aortic valve replacement (TAVR), pulmonic valve replacement, and mitral valve repair, targeted to specific populations. Rapid technological advancements in device design are likely to improve acute and long-term results and expand current indications.

Hemodynamics of percutaneous valves have been very favorable.²⁻⁵ However, a challenging area has been the new or residual valve regurgitation that may occur either after transcatheter valve implantation or repair of a native or prosthetic valve. This condition presents a diagnostic and therapeutic challenge to the interventional and imaging cardiology team in the catheterization laboratory and to the clinician and imager in the outpatient setting. The current document addresses the challenges of assessing residual regurgitation after percutaneous valve replacement or repair and provides a guide to the cardiac team on how best to approach this condition, based on the available data and a consensus of a panel of experts. This document supplements the previous American Society of Echocardiography (ASE) guideline on the assessment of surgically implanted prosthetic valves.⁶ It does not address flow dynamics through the percutaneous prosthetic valves since, in general, the evaluation is similar to surgically implanted valves,⁶ but focuses mostly on new or residual valvular regurgitation. In addition to the use of echocardiography and hemodynamic assessment in the acute setting, the document incorporates the role of cardiac magnetic resonance (CMR) imaging. This guideline is accompanied by a number of tutorials and illustrative case-studies on evaluation of valvular regurgitation after catheter-based interventions as well as native valve regurgitation, posted on the following website (www.asecho.org/vrcases), which will build gradually over time.

II. GENERAL PRINCIPLES

In the catheterization laboratory, members of the heart team should be well versed with how to assess valve regurgitation, the language used to describe valve structure and position, as well as a clear, coordinated nomenclature as to the site of regurgitation, using a clock

depiction or anterior/posterior, medial and lateral sites in relation to the annulus. General principles for evaluating native valve regurgitation with echocardiography, Doppler, and CMR have recently been updated.⁷ The methodology of assessing regurgitation qualitatively and quantitatively with these techniques will not be reiterated in detail but summarized, with emphasis on how these parameters may be affected in the setting of transcatheter valve replacement or repair. The committee concurs with recent ASE guidelines⁷ and those of the American College of Cardiology (ACC) and American Heart Association (AHA) on valvular heart disease⁸ that valvular regurgitation should be classified as mild, moderate, or severe.

There are four main principles to the evaluation of valvular regurgitation with echocardiography: comprehensive imaging, integration of multiple parameters, individualization to the patient, and precise language to describe the findings. Comprehensive imaging by trans-thoracic echocardiography (TTE) incorporates two dimensional/three-dimensional (2D/3D) structural evaluation of the implanted device and surrounding structures, cardiac chamber size and function, flow interrogation with pulsed-wave Doppler (PWD), continuous-wave Doppler (CWD), and color Doppler (CD), and volumetric quantitation as well as assessment of additional hemodynamic parameters such as pulmonary artery (PA) pressures. Each of these methods has particular technical considerations, strengths, and limitations, which have been described in detail.⁷ Unfortunately, many of these parameters may not be available during intra-procedural transesophageal echocardiography (TEE) or TTE due to limited windows, inability to align Doppler interrogation with blood flow, and foreshortening of the apex, which may preclude accurate volumetric quantitation. Thus, intra-procedural echocardiography often relies heavily on CD jet characteristics, evaluating when possible its three components of flow convergence, vena contracta, and jet area. CD imaging of the jet in this setting can be impacted by hemodynamics, effects of sedation/anesthesia, technical factors, and attenuation by the implanted device. Because CD area is mainly determined by jet momentum ($\text{area} \times \text{velocity}^2$), the pressure gradient and therefore velocity driving the jet can greatly influence jet size. For example, mitral regurgitation (MR) jets after mitral repair or transcatheter mitral valve replacement (TMVR) can be large despite a small orifice if left ventricular (LV) pressure is high (e.g., hypertension or aortic stenosis). Conversely, a low aortic diastolic pressure after TAVR might result in a small aortic regurgitation (AR) jet with CD despite hemodynamically significant AR. To compensate for hemodynamically mediated variation inherent in CD characterization, it is common practice for the implanting physician or anesthesia team to "normalize" post-implant hemodynamics (increase or decrease heart rate and systemic blood pressure) pharmacologically prior to assessing intraoperative valvular regurgitation in the procedure room. Moreover, valve regurgitation after percutaneous procedures, in contrast to native or surgical prosthetic valves, frequently arises from multiple sites with variable severity, making CD assessment of regurgitation more difficult. All the above issues highlight the need to integrate CD information with other echocardiographic findings to determine overall severity of regurgitation. This comprehensive evaluation may be more feasible to perform after completion of the procedure, out of the catheterization laboratory setting. Intra-procedurally, the findings by echo-Doppler are complemented with invasive hemodynamic assessment to gauge the overall results of the intervention, and cineangiography may be needed in situations where the residual regurgitation is difficult to assess, inconclusive, or suspected to be more than mild (Figure 1). In the setting outside the catheterization laboratory, uncertainty regarding severity

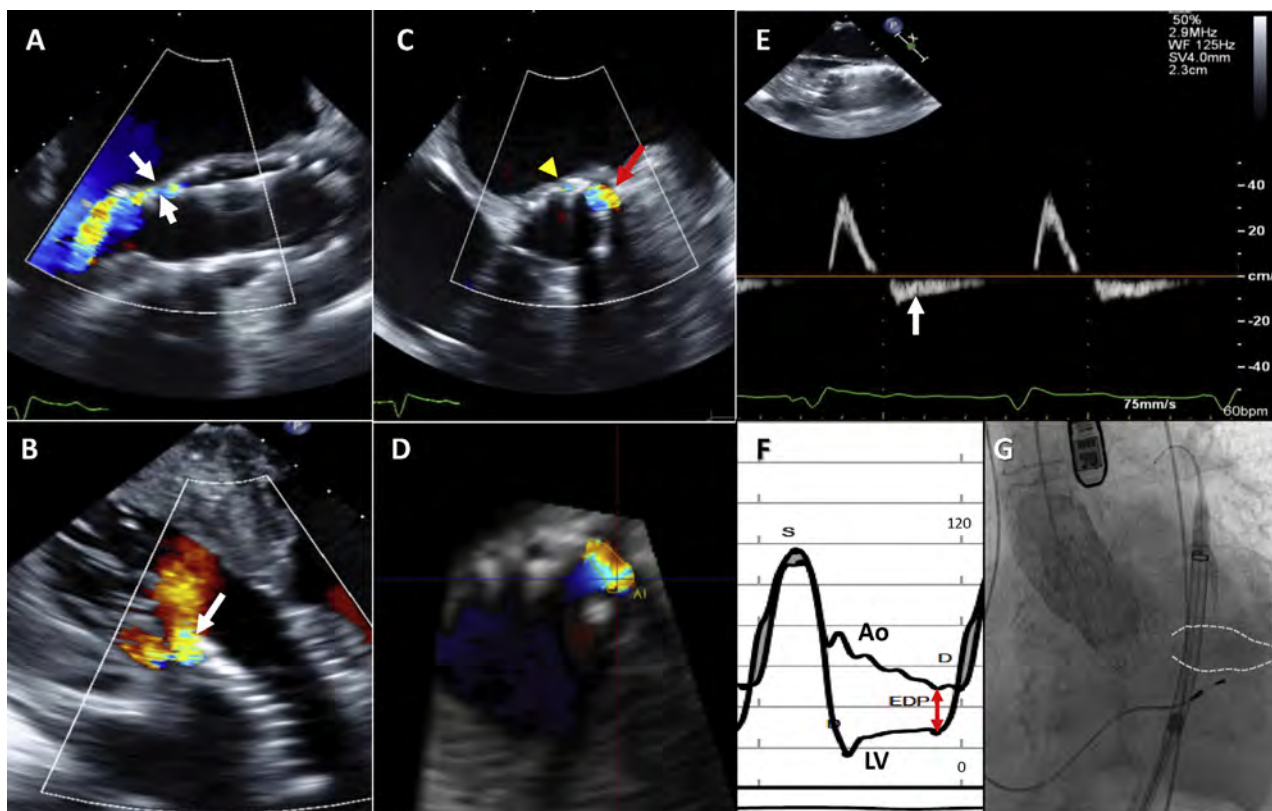


Figure 1 Tools for the intra-procedural assessment of paravalvular regurgitation following TAVR: color Doppler (2D/3D), pulsed-wave Doppler of aortic flow, aortic & LV diastolic pressures and aortography. All panels are from the same patient. The valve is a self-expanding valve. **(A)** Mid-esophageal TEE long-axis view showing paravalvular AR (*white arrows*). Off-axis imaging is frequently helpful. **(B)** Deep transgastric view showing the paravalvular jet seen in panel A. Multiple views are essential to avoid missing jets. **(C)** Mid-esophageal short-axis view showing a paravalvular jet (*red arrow*), and a pinhole jet (*arrow head*). It is important to scan the valve and image at the lower end of the valve stent to ensure that the measured jet reaches the LV. The circumferential extent of the larger jet here is 14% but the jet is relatively wide. The pinhole jet is too small to planimeter. **(D)** 3D planimetry of the same paravalvular jet yields an area of 0.22 cm². 3D echocardiography makes it possible to precisely identify the vena contracta, something that may be challenging with 2D imaging alone. **(E)** Mid-esophageal TEE images of the descending thoracic aorta showing non-holodiastolic flow reversal by pulsed-wave Doppler. Some flow reversal, usually non-holodiastolic, may be present in patients undergoing TAVR even in the absence of aortic regurgitation; Hence it is important to establish the baseline aortic flow pattern. **(F)** Simultaneous LV and aortic (Ao) pressure tracings that form the basis for the AR index. In this case, the AR index is 28%. Indices of <25% have been reported to have increased 1-year mortality. However, this value is very dependent on aortic and ventricular compliances as well as the severity of paravalvular regurgitation. *Red arrow* denotes diastolic BP – LVEDP. **(G)** Diastolic still frame from post-implantation aortogram showing 2+ paravalvular AR (*outlined area*). Ao, Aortic pressure tracing; EDP, end-diastolic pressure; LV, left ventricular pressure tracing; S, systole.

of regurgitation by echocardiography due to poor-quality data or discrepancies among parameters that cannot be resolved should be stated in the report to alert the clinician to consider other imaging modalities such as TEE, CMR or multi-detector computed tomography (MDCT), if clinically indicated, to better assess lesion severity and mechanism, particularly if it could mean the difference between another intervention and medical therapy.

III. PERCUTANEOUS AORTIC VALVE INTERVENTIONS

TAVR is an accepted alternative to surgical aortic valve replacement (SAVR) in high- and intermediate-risk as well as inoperable patients.^{2,5,9-11} Evaluation of the use of TAVR in patients with low surgical risk is ongoing. Multiple studies have shown a higher incidence of PVR in patients undergoing TAVR compared to SAVR.¹²⁻¹⁴ Residual AR is an important predictor of mortality¹⁵⁻¹⁸

and was a major impetus for recent improvements in TAVR design, such as cuffs, skirts and repositionable valves. Although early studies suggested that even mild PVR might impact outcomes,¹⁹ more recent observations in the intermediate-risk population suggest that only moderate or severe PVR increase mortality.^{2,10} Several factors may account for the varying incidence of PVR and its prognostic outcome, including prosthetic valve design, valve calcification, physiologic considerations, and difficulty in grading PVR severity.²⁰ Newer valve iterations or designs however, show very low rates of PVR (0-2%), which will likely reduce the impact of this complication on outcomes.^{10,21,22}

A. Balloon-Expandable vs. Self-Expanding Valves

While transcatheter aortic valve designs continue to evolve, devices that have the largest world-wide experience fall into two general categories: those deployed with balloon-assisted expansion and those

that spontaneously expand on release from the delivery system, the so-called self-expanding valves. Within these categories, the most widely used valves have been the Edwards SAPIEN™ family of balloon-expandable valves and the Medtronic Corevalve®/Evolut™ self-expanding valves. Within these families of valves, improvements in design have reduced the incidence and severity of PVR. The construct of these valves has been reviewed recently.²³ Although other valves have received the CE (conformité Européenne) mark in Europe and are in varying phases of clinical trials in North America, they will not be further discussed.

B. Pre-procedural Planning for TAVR and Valve-In-Surgical Valve

Pre-procedural planning for TAVR can be useful for predicting PVR following valve implantation and allows the heart team to plan for the appropriate treatment of intra-procedural PVR. Numerous studies have shown that significant under-sizing of the transcatheter heart valve (THV) will result in greater degrees of PVR.^{12,24} MDCT reconstruction-based measurements of the aortic annulus has been shown to reduce the incidence of greater than mild paravalvular AR compared to 2D TEE measurements.²⁵ The accuracy of 3D TEE for annular sizing and prediction of PVR severity has also been demonstrated.²⁶ MDCT determination of calcium location and burden is another important predictor of PVR.^{27,28} For valve-in-surgical-valve procedures, knowledge of the manufacturer's reported internal diameter of the bioprosthetic surgical valve is essential for appropriate sizing. In the absence of this information, TEE or MDCT may be used to determine the internal diameter of the valve; however, regurgitation following this procedure is rarely more than mild.²⁹

C. Implantation Technique for Routine TAVR

Although not required, the balloon-expandable THV may be pre-dilated using balloon aortic valvuloplasty, which is intended to improve the positioning process but may also decrease the number of cerebral ischemic lesions.³⁰ The SAPIEN 3 delivery system has a middle marker and two other markers to facilitate trans-annular positioning of the valve before deployment; because of stent cell design, the valve shortens from the ventricular end, engaging the surrounding tissue early in the deployment process. After obtaining a suitable coplanar angle, the Edwards SAPIEN 3 valve is deployed using rapid ventricular pacing to reduce valve motion just before balloon expansion. Medtronic's CoreValve Evolut R and Evolut Pro have a controlled and slow-release self-expanding delivery system. They do not require rapid pacing, although some interventionalists may use pacing to stabilize the valve during deployment. The valve can also be repositioned and recaptured up to a point in the unsheathing process. In addition to adequate sizing of the annulus, accurate positioning of all valves is essential to reduce post-implantation PVR and reduce post-procedural pacemaker rates.³¹ Valve positioning can be imaged by TTE and TEE as well as fluoroscopy.^{23,32} The amount and location of calcium within the landing zone of the valve also plays a major role in the incidence and severity of PVR following TAVR.^{12,28,33}

D. TTE vs. TEE in the Catheterization Laboratory

Echocardiography remains the primary imaging modality for assessing PVR immediately following TAVR. Initially, the procedure was performed under general anesthesia with TEE monitoring. Performing TAVR under local anesthesia with conscious sedation or with monitored anesthesia care has been reported recently and is increasingly

used.³⁴⁻³⁶ However, the conscious sedation approach is not universal, and conversion to general anesthesia in 10-17% of cases^{37,38} has been reported, with a more recent lower rate of conversion (5.9%) published from the National Cardiovascular Data Registry (NCDR).³⁹ TEE guidance has been associated with less contrast use,⁴⁰ lower incidence of PVR,⁴¹ and greater procedural success.³⁹ A recent study from a high-volume site performing primarily conscious sedation with TTE guidance showed that there was a higher incidence of second valve implantation (7% vs. 2%; $P = .026$) and post-TAVR balloon dilation (38% vs 17%; $P < .001$) intra-procedurally compared to the TEE approach.⁴²

Studies evaluating the clinical outcome of patients undergoing TAVR with either TEE/general anesthesia or TTE/moderate sedation have not shown consistent results favoring one or the other approach. In the Brazilian Registry,⁴³ the use of TEE to monitor the procedure compared to TTE was associated with less overall mortality (HR: 0.57) and late mortality (HR: 0.47). Recent observational studies support the safety of the "minimalist" anesthetic approach^{36,44} and the European Society of Cardiology's Transcatheter Valve Treatment (TCVT) Registry found that survival at 1 year was similar between groups.³⁵ Lastly, the observational NCDR study reported that while the conscious sedation approach had lower procedural success, it was associated with a reduced rate of in-hospital mortality (1.5% versus 2.4%, $P < .001$) and 30-day mortality after TAVR (2.3% versus 4.0%, $P < .001$), warranting formal study.³⁹ This is particularly important as the field begins to address TAVR in the lower-risk patient population who are also at lower risk for complications during general anesthesia, and whose expected outcomes are significantly better than patients treated in these registries.^{10,45}

Advantages and disadvantages of TTE and TEE as they pertain to assessing valvular regurgitation after TAVR are listed in Table 1. Using TTE, imaging from the parasternal windows requires direct placement of the probe within the fluoroscopic imaging plane with high exposure of the imager to radiation. The patient's supine position and operator avoidance of the sterile field may prohibit optimal transducer placement. The usual sources of ultrasound interference still apply, such as chest wall deformities, emphysema, obesity, etc. Intra-procedural TTE can evaluate the causes of acute hemodynamic compromise such as pericardial effusion, under-filled or dysfunctional ventricles, and severe valvular regurgitation. The assessment of PVR may be challenging unless imaging windows are ideal. On the other hand, a major advantage of intra-procedural TEE guidance is continuous imaging throughout the TAVR procedure with rapid and accurate diagnosis of complications, including PVR.^{32,46,47} Studies have shown that TEE can be safely performed in the setting of monitored anesthetic care.⁴⁸ Since CD is essential in localizing and assessing PVR severity, it is important to recognize that shadowing of the prosthetic valve may affect detection of paravalvular regurgitation by either TTE or TEE (TTE may not optimally display posterior paravalvular regurgitation whereas TEE may not optimally display anteriorly located defects; Figure 2). A combination of both techniques may be needed in situations where an AR jet is detected in the left ventricular outflow tract (LVOT) or LV and the source cannot be localized by one approach. TEE must include standard and deep transgastric views to assess both valvular/LVOT hemodynamics and detect paravalvular regurgitation that may be missed in esophageal views (Figure 2). Overall, qualitative and quantitative echo-Doppler parameters can be obtained with TTE or TEE imaging and applied to assess the severity of PVR either during or after the procedure.

Table 1 Advantages and disadvantages of TTE versus TEE imaging for assessment of aortic regurgitation during and after TAVR

Parameter	TTE	TEE
Advantages General	<ul style="list-style-type: none"> • Standard windows for assessing valvular/cardiac structure & function • Imaging anterior paravalvular regurgitation with CD • Ease of CWD interrogation of AR jet • Ease of PWD interrogation of flow in the LVOT • Can provide volumetric quantitation • Less resource intensive 	<ul style="list-style-type: none"> • Higher resolution with high frame rates for 2D and 3D imaging, and quantitation of VCA • Imaging posterior paravalvular regurgitation with CD
Advantages During TAVR	<ul style="list-style-type: none"> • Does not require intubation or general anesthesia • Superior viewing of anterior paravalvular regurgitation • May still convert to TEE approach, if needed 	<ul style="list-style-type: none"> • Continuous imaging throughout procedure, irrespective of TAVR access route • Intra-procedural imaging may help avoid complications (e.g., imaging during balloon valvuloplasty to assess risks of calcium displacement) • Immediate intra-procedural diagnosis of complications • Lower contrast use for procedure • Ability to hold respiration during general anesthesia for better 3D assessment of PVR, and aortic annular measurement (if needed)
Disadvantages General	<ul style="list-style-type: none"> • Image quality dependent on patient factors (e.g., chest morphology, lung hyperinflation, suboptimal positioning, valve calcific acoustic shadowing) • Difficulty imaging posterior paravalvular regurgitation with CD • Lower resolution of 2D and 3D imaging 	<ul style="list-style-type: none"> • Image quality dependent on patient factors (e.g., valve calcific acoustic shadowing, cardiac position relative to esophagus and stomach) • Difficulty imaging anterior paravalvular regurgitation with CD in esophageal views • Challenge in optimizing CWD recording of AR jet and CD display of AR from deep transgastric view
Disadvantages During TAVR	<ul style="list-style-type: none"> • Procedural delay during image acquisition (to minimize radiation exposure to imager) • Non-continuous imaging during procedure may delay diagnosis of complications (e.g., valve mal-positioning, annular rupture, coronary occlusion) • Limited imaging windows for non-transfemoral TAVR access routes • Difficult to perform volumetric quantitation 	<ul style="list-style-type: none"> • Requires conscious sedation or monitored anesthesia care • More resource intensive; may prolong hospitalization if requires intubation & there is difficulty extubating patient • Probe interference with fluoroscopic imaging (minimized by articulation of probe)

E. Evaluation of Valvular Regurgitation after TAVR

Assessment of the presence and severity of AR after TAVR is complex, requiring imaging and Doppler evaluation of the valve and annulus. Central valve regurgitation is far less common than paravalvular regurgitation. Evaluation and grading of PVR is complicated by the complex nature of AR jets after valve implantation and the differences in jet characteristics between valve designs. Regurgitant jets around a stented valve are due to mal-apposition of the stent and the native surrounding structures. Mal-apposition may occur for a number of reasons: 1) THV collapsible frames have empty cells between metal struts; 2) metallic stents have limited deformability, preventing complete closure of small gaps created by irregularly-calcified leaflets, protruding dystrophic calcium in the annulus or LVOT, or triangular commissural gaps; 3) mal-positioning of the THV (too high or low in the annulus); and 4) under-sizing of the THV for the native annular size.

Assessment of PVR relies heavily on CD imaging both during the procedure and in the outpatient setting, as conventional spectral Doppler parameters may have limitations.²⁰ CD evaluation has out-comes data from 2 separate trials using 2 different core laboratories.^{2,10} Spectral Doppler evaluation is particularly hampered in evaluating PVR during the TAVR procedure because of limited

windows of interrogation of flow, for either TEE or TTE. Thus, during the acute setting, hemodynamics and aortography are frequently used to complement CD imaging for a comprehensive evaluation of residual PVR (Figure 1). The current document will therefore address aortography, hemodynamic assessment, and Doppler methods that can be used in the interventional arena during TAVR (qualitative/semi-quantitative parameters) and will detail also other Doppler quantitative methods and CMR methods that can be applied outside the interventional laboratory for a more comprehensive evaluation of PVR with non-invasive techniques.

1. Aortography. Conventional cineangiography with an aortic root injection of radiographic contrast can be used for intra-procedural determination of AR severity.⁴⁹ This is usually performed during the TAVR procedure in the catheterization laboratory when AR is detected by CD and its severity needs further evaluation. This approach, however, is rarely indicated in the chronic setting or for serial follow-up. Angiographic grading, while helpful in extremes, may not correlate well with quantitative assessment of AR severity, and cannot reliably distinguish central from paravalvular regurgitation.^{20,50,51}

2. Hemodynamic Assessment in the Catheterization Laboratory. A number of investigators have attempted to use the

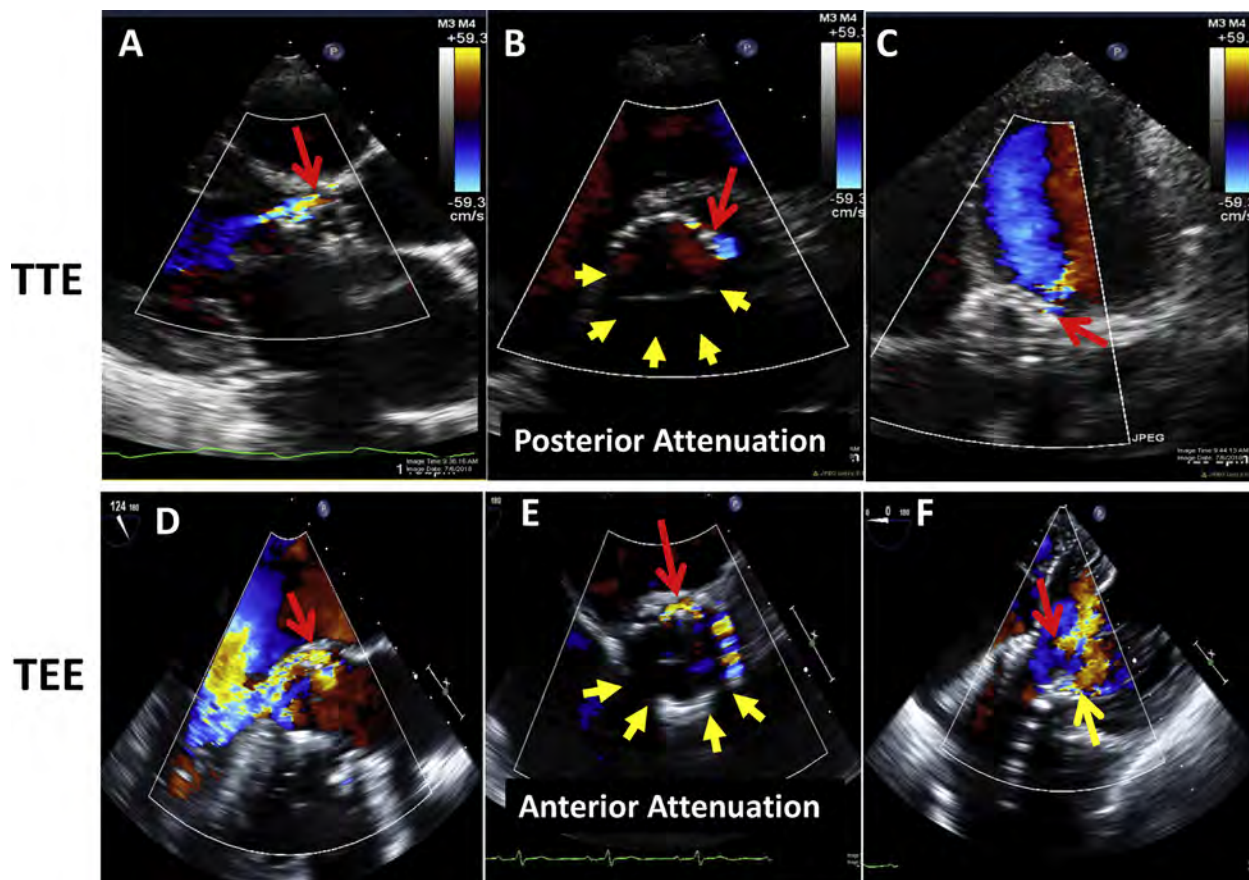


Figure 2 Demonstration of paravalvular leaks after TAVR assessed by TTE and TEE in two different patients, demonstrating ultrasound attenuation of the valve ring and adjacent structures by the prosthetic valve, and the importance of comprehensive color Doppler imaging from the apical views (apical in TTE and transgastric in TEE). Panels A to C demonstrate an anterior paravalvular leak that is identified from a parasternal long-axis view (A), short-axis view (B), and modified apical five-chamber view (C). There is posterior attenuation (yellow arrows). Panels D-F demonstrate posterior paravalvular leak on mid-esophageal 120 degrees (D) and short-axis views (E); the transgastric view (F) demonstrates two jets of paravalvular regurgitation, one jet is anterior and the other is posterior. Without careful comprehensive interrogation, the anterior leak would have been potentially missed on just mid-esophageal views because of attenuation (yellow arrows).

Table 2 Invasive hemodynamic indexes for assessing severity of AR immediately After TAVR

Author	Index	Formula	Cutoff for significance
Sinning <i>et al.</i> ⁵²	AR index	$([DBP - LVEDP] \div SBP) \times 100$	AR index <25 predicted higher mortality
Sinning <i>et al.</i> ⁵⁴	ARI ratio	Ratio of post-procedural to pre-procedural AR index	ARI ratio <0.60 improved 1-year mortality prediction of post TAVR AR Index <25
Jilaihawi <i>et al.</i> ⁵³	CHAI score	$([DBP - LVEDP] \div HR) \times 80$	<25 (denoting \geq moderate PVR), predicted higher mortality
Bugan <i>et al.</i> ⁵⁵	TIAR index	$(LV-Ao \text{ diastolic pressure time integral}) / (LV \text{ systolic pressure time integral}) \times 100$	TIAR index <80 was associated with a sensitivity of 86% and a specificity of 83% for \geq mild AR.

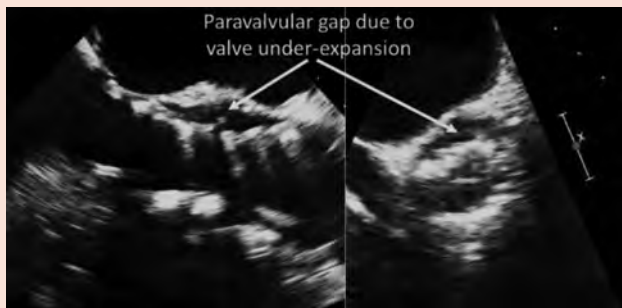AR, Aortic regurgitation; ARI, AR index; CHAI, composite heart-rate-adjusted hemodynamic-echocardiographic aortic insufficiency; DBP, diastolic blood pressure; HR, heart rate; LVEDP, left ventricular end-diastolic pressure; SBP, systolic blood pressure; TIAR, Time-integrated aortic regurgitation.

hemodynamic tracings obtained during the TAVR procedure to assess the severity of AR acutely. Several indices have been proposed, most of which use a combination of differences between aortic pressure and LV diastolic pressure (Table 2).⁵²⁻⁵⁵ The premise of these indices is that the difference between aortic and LV diastolic

pressures decreases with increasing severity of acute AR (higher LV diastolic pressure, lower aortic diastolic pressure, or a combination of the two). Despite multiple limitations of these indices, including heart rate dependence and inability to distinguish valvular from paravalvular regurgitation, they remain a helpful adjunctive tool

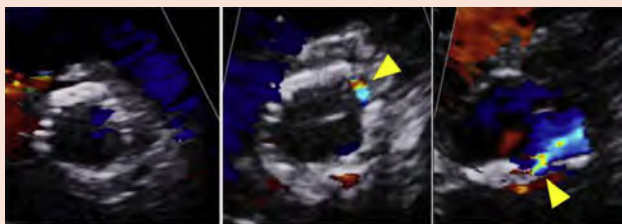
Table 3 Echocardiographic parameters (TEE/TTE) and respective comments in determining AR severity after TAVR

Parameter	Comments
Stent shape and position	Not accurate in predicting presence/severity of AR
Color Doppler	<ul style="list-style-type: none"> - Needs meticulous scanning of whole valve to identify sites of regurgitation, which are frequently multiple and eccentric - Essential to identify origin of jets, which may not all be at the same level - Short-axis imaging below the valve may overestimate AR severity in eccentric jets - Attenuation of ultrasound by prosthesis in far field may hinder visualization of regurgitation (anterior with TEE and posterior with TTE) - Deep transgastric views during TEE are essential for assessment of regurgitant jets (jet area and length are not used to assess regurgitation severity)
Vena contracta width (VCW)	VCW >0.6 cm specific for severe AR; severity of multiple smaller jets more difficult to evaluate
Vena contracta area (VCA)	<ul style="list-style-type: none"> - May allow addition of multiple jets - Prone to blooming artifacts - Accuracy limited by spatial resolution for small jets



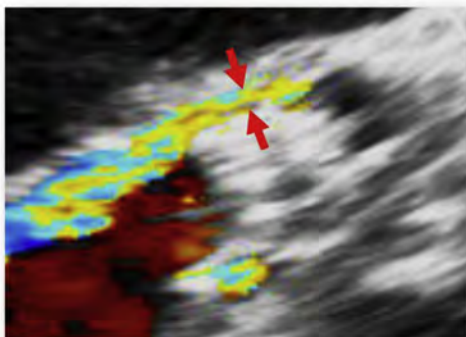
Color Doppler

Jet number, location, direction, and eccentricity

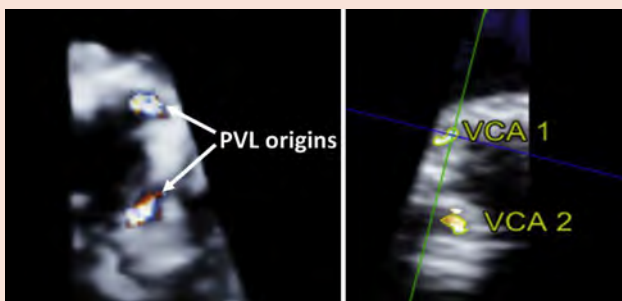


Sweeping of the aortic root to locate the PVR origin

Vena contracta width (VCW)

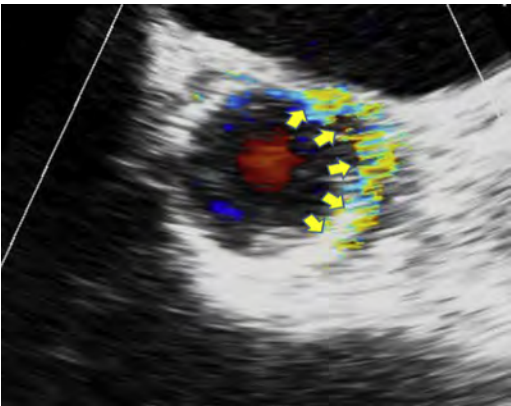

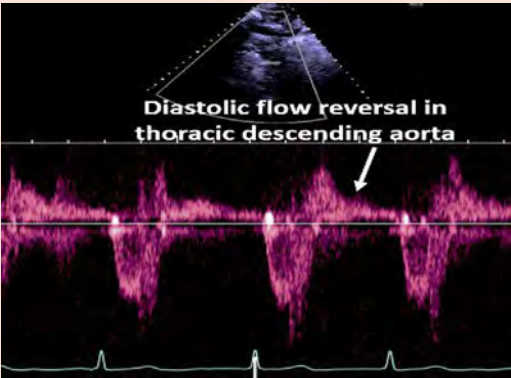


Vena contracta area (VCA)



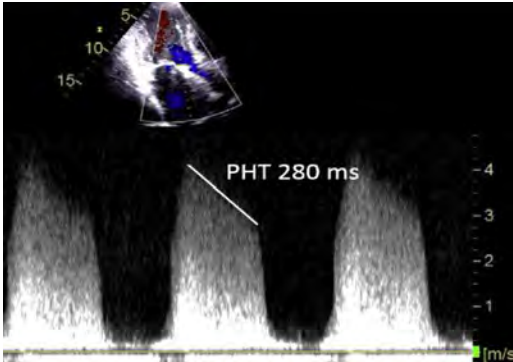
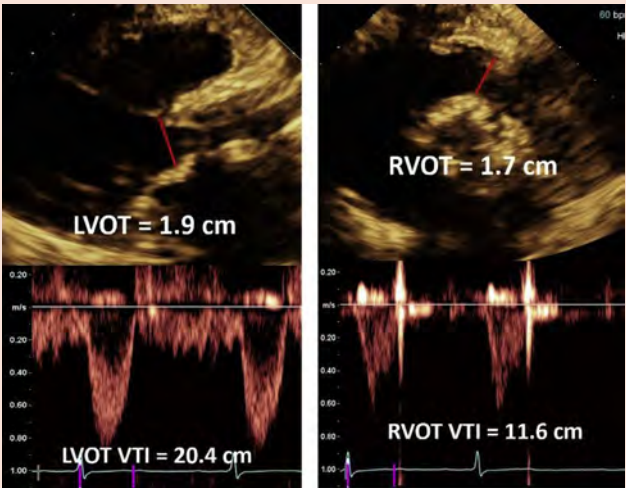
(Continued)

Table 3 (Continued)

Parameter		Comments
Circumferential extent (%)		<ul style="list-style-type: none"> - Continuous circumferential extent of AR of >30% indicative of severe AR - Circumferential extent of few, smaller discrete jets more difficult to assess
Flow convergence		Large flow convergence in aorta indicative of severe AR
Spectral Doppler		<ul style="list-style-type: none"> - Useful if new (relative to baseline) and holodiastolic, consistent with at least moderate AR; lesser aortic flow reversal is non-diagnostic - Holodiastolic flow reversal in abdominal aorta more specific for significant AR

(Continued)

Table 3 (Continued)

Parameter		Comments
CW Doppler profile of AR jet (velocity waveform density, pressure half-time)		<ul style="list-style-type: none"> - Dense velocity waveform consistent with more than mild AR - Pressure half-time in extremes (>500 or <200 ms) may be helpful acutely; influenced by LV compliance and other factors
Quantitative parameters: RVol, RF, and EROA		<ul style="list-style-type: none"> - Not feasible during TAVR procedure - Stroke volume by PWD in LVOT: particular attention must be paid to site of measurement of LVOT diameter and velocity depending on type of TAVR valve - 3D echo or contrast echo is recommended for LV volumetric quantitation of stroke volume to avoid underestimation of RVol and RF - Mitral valve annulus for calculation of systemic stroke volume has limitations in presence of mitral annular calcification; RVOT site can be used in the absence of significant pulmonic regurgitation - EROA determination (RVol/VTI_{AR}) is rarely used clinically

AR, Aortic regurgitation; EROA, effective regurgitant orifice area; LV, left ventricle; LVOT, LV outflow tract; RF, regurgitant fraction; RVol, regurgitant volume; RVOT, RV outflow tract; VTI, velocity-time integral.

immediately following TAVR to assess the acute hemodynamic severity of AR and its prognostic impact.⁵²⁻⁵⁵

3. Doppler Echocardiographic Assessment of AR after TAVR. Similar to any assessment of regurgitation, evaluation of PVR should be an integrative approach using a number of qualitative parameters as well as semi-quantitative and quantitative measurements. These Doppler parameters are, in principle, similar to those used in evaluating native or prosthetic valve AR.⁷ However, there are particular considerations related to TAVR and the TAVR population that may modulate the approach to imaging PVR, and the feasibility, applicability, and accuracy of standard Doppler parameters in assessing regurgitation severity. Table 3 details the echocardiographic parameters that may be used in the evaluation of severity of PVR after TAVR and offers technical and interpretive comments and caveats. Table 4 details the overall comprehensive evaluation of aortic regurgitation after valve implantation.

A few comments for assessing PVR severity post-TAVR should be mentioned (Table 3). First, stent shape and position may support AR Doppler findings but lack sensitivity and specificity for AR severity. Second, PVR post-TAVR frequently arises at multiple sites

in the paravalvular space, with jets having irregular shapes and trajectories, thus challenging standard CD measures of AR severity. Third, limitations of imaging AR are similar to those observed with surgical prostheses,⁶ such as acoustic shadowing of the far field (posterior paravalvular region for TTE and anterior paravalvular region for TEE; Figure 2), requiring an extensive search for jets, using multiple imaging windows (Figure 3). It is essential to use windows that not only avoid the acoustic shadowing but also image the regurgitant jets parallel to the insonation beam: in general, apical and subcostal windows for TTE, and mid-esophageal and deep transgastric for TEE. In very eccentric jets directed anteriorly or posteriorly, the parasternal window may be best for TTE. Fourth, the paravalvular jet path and number of jets are significantly affected by native calcium and leaflets, and by the discontinuous nature of the metallic stent. This is particularly important to understand when assessing the circumferential extent of the PVR. Jet length or area should not be used to grade severity, but rather to confirm the presence and location of the AR jet(s).

a. Color Doppler Jet Features.—The assessment of PVR following TAVR relies heavily on CD. It is by far the most essential Doppler modality during the TAVR intervention. A number of jet

Table 4 Evaluation of severity of prosthetic aortic regurgitation after TAVR

PVR severity	Mild	Moderate	Severe
Aortography	Contrast does not fill entire LV and clears with each cycle	Intermediate	Contrast fills LV on first beat, ending with greater density than in ascending aorta
Invasive Hemodynamic Parameters			
AR index*	≥25	<25	<25
Dicotic notch	Present	Present	Effaced or absent
Echocardiography: TTE and/or TEE			
Structural parameters			
Position of prosthesis	Usually normal	Variable	Frequently abnormal
Stent and leaflet morphology	Usually normal	Variable	Frequently abnormal
Doppler Parameters			
Qualitative			
Proximal flow convergence (CD)	Absent	May be present	Often present
AR velocity waveform density (CWD)	Soft	Dense	Dense
Diastolic flow reversal (PWD) in			
- Proximal descending aorta ^{††}	- Brief, early diastolic	- May be holodiastolic	- Holodiastolic (end-diastolic velocity ≥20 cm/s)
- Abdominal aorta	- Absent	- Absent	- Present
Semi-quantitative			
Vena contracta width (cm) (CD)	<0.3	0.3-0.6	>0.6
Vena contracta area (cm ²) [§] (2D/3D CD) [§]	<0.10	0.10-0.29	≥0.30
Circumferential extent of PVR (%) (CD) [¶]	<10	10-29	≥30
Jet deceleration rate (PHT, ms) [#] (CWD)	Variable Usually >500	Variable 200-500	Steep Usually <200**
Quantitative			
Regurgitant volume (mL)	<30	30-59 ^{††}	>60 ^{††} (May be lower in low flow states)
Regurgitant fraction (%)	<30	30-49	≥50
EROA (cm ²) ^{††}	<0.10	0.10-0.29 ^{††}	≥0.30 ^{††}

2D, Two-dimensional; 3D, three dimensional; AR, aortic regurgitation; CD, color flow Doppler; CWD, continuous-wave Doppler; EROA, effective regurgitant orifice area; LVOT, left ventricular outflow tract; PVR, paravalvular regurgitation; PHT, pressure half-time; PWD, pulsed wave Doppler; TTE, transthoracic echocardiography; TEE, transesophageal echocardiography.

*One of the hemodynamic parameters (Table 1) used in the catheterization laboratory after TAVR.

[†]More specific in peri-procedural or early post-procedural assessment. Holodiastolic flow reversal may not be seen in severe bradycardia.

[‡]Dependent on aortic compliance; limits its utility in the elderly population; influenced by heart rate.

[§]The vena contracta area is measured by planimetry of the vena contracta of the jet(s) on 2D or 3D color Doppler images in the short-axis view.

^{||}Measured as the sum of the circumferential lengths of each regurgitant jet vena contracta (not including the non-regurgitant space between the separate jets) divided by the circumference of the outer edge of the valve.

[¶]Circumferential extent of PVR best not to be used alone, but in combination with vena contracta width and/or area.

[#]Influenced by LV and aortic compliance, particularly in this population.

**May not be specific for severe aortic regurgitation in the setting of abnormal aortic or ventricular compliance.

^{††}May be functionally important at lower values depending on the acuteness of PVR, and size and function of the LV. When total stroke volume is calculated from LV volumes, use of 3D echocardiography and preferably contrast echocardiography is recommended to avoid underestimation of LV volumes, RVol, and RF.

^{‡‡}EROA is infrequently used in AR. It is derived using the volumetric approach, not PISA.

characteristics are important to assess: jet width at its origin, the number of jets, whether there is visible proximal flow convergence (usually a sign of more than mild PVR), jet path/direction, and circumferential extent of the jet. Although PVR jets may not be as wide as with surgical PVR, a single jet VC width at its origin of >6 mm is specific for severe AR. If the jet path can be imaged

tracking around the stented valve and into the LV, there is usually significant mal-apposition of the stent and more than mild PVR.⁵⁶ Because PVR jets may be re-directed by bulky calcium, it is important to note the direction of the AR; not infrequently these jets may be eccentric, going across the short-axis plane of the LV outflow tract (Figure 4). The severity of these AR jets is prone to

Detection of Paravalvular AR after TAVR with Color Doppler

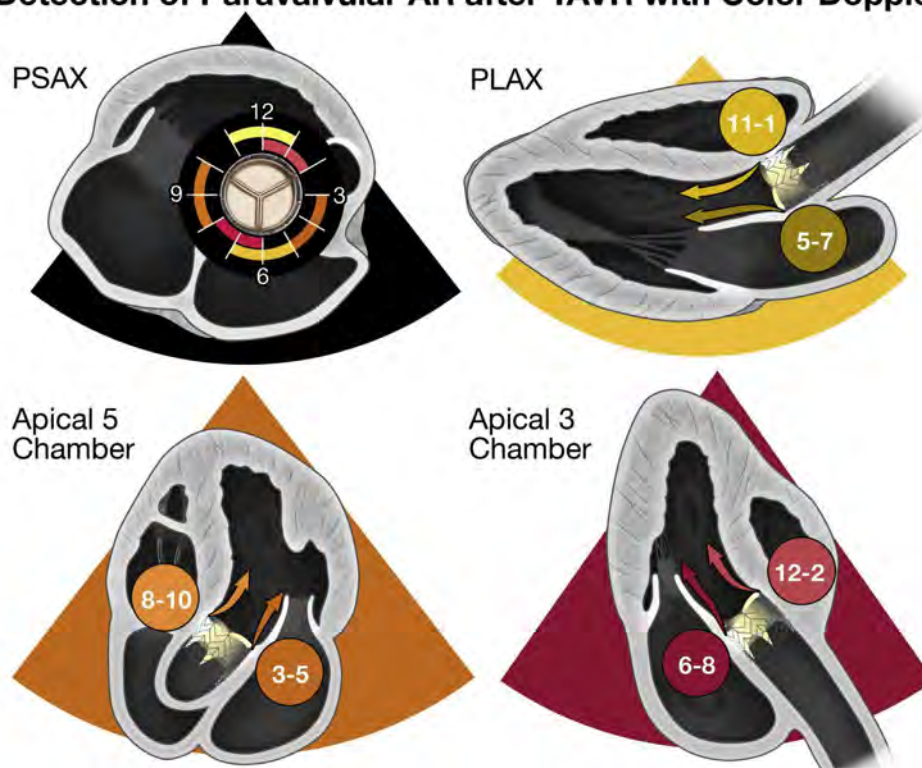

Figure 3 Standard 2D echocardiographic views depicting the detection of TAVR-related paravalvular regurgitation. Color coding delineates the regions around the prosthetic valve that can be visualized from the parasternal and apical views. With ultrasound plane rotation, tilting upward or sideways, a more complete interrogation of the valve can be accomplished. Although these unconventional planes may foreshorten cardiac structures, they are essential in detecting and localizing the residual regurgitation. The importance of apical views lies in the fact that some jets may not be detected in the parasternal views because of either shadowing from the prosthesis in parasternal short axis (PSAX; lateral, medial and posterior surfaces; see Figure 2) or are located medially or laterally to be seen in the parasternal long-axis (PLAX) view.

overestimation if assessment of the circumferential extent of the jet origin mistakenly includes this single short-axis view displaying jet eccentricity. Because the number of jets also reflects severity, an extensive search for all jets should be performed, using multiple imaging windows, biplane imaging, and subtle manipulation of the transducer within each window.

The circumferential extent of the jet is a useful parameter for assessing PVR severity; however, as with all parameters, it should not be used in isolation (Figure 5). The updated Valve Academic Research Consortium (VARC-2) criteria⁵⁷ used in the PARTNER I trial⁵⁸ recommended the following with respect to the circumferential extent of paravalvular AR in short axis: trace (pinpoint jet), mild (<10%), moderate (10-30%), and severe (>30%). Recent studies using the VARC-2 criteria, including this parameter, have shown increased mortality associated with worse PVR severity.^{10,45,59}

To assess residual AR with CD after TAVR, the following caveats should be considered:

1. The whole transcatheter valve should be scanned, from the distal (aortic) to the proximal (ventricular) end of the THV, to identify the number, location(s), and direction(s) of the AR jet(s).
2. The entire short axis of the valve should be imaged in a single view, if possible, so that the valve level imaged is the same in the far field as it is in the near field, and laterally as well as medially.
3. Central prosthetic AR jets will occur at the level of leaflet coaptation whereas PVR will be seen at the proximal (ventricular) edge of the valve.

Importantly, the jet must enter the LV to be considered true regurgitation, thus imaging just below the edge of the stent will confirm the presence of true PVR; however, the vena contracta of the jet should be measured at its narrowest region.

4. Color flow around the THV within the sinuses of Valsalva but above the annular valve skirt should not be mistaken for PVR. Flow in the sinuses has low velocity and does not connect with the LVOT in diastole. Scanning through the long axis of the valve is useful in distinguishing color flow in the sinuses from PVR.
5. Small jets of regurgitation are typically isolated to the open stent cells and not at the “nodes” of the stent frame. It is important not to include the stented frame in the measurement of the circumferential extent of the regurgitation but to integrate only the regurgitant jets when determining the circumferential extent (Figure 5).
6. In contrast to native valve AR, the ratio of jet width to LV outflow tract width or jet cross-sectional area to cross-sectional area of the valve or LV outflow tract should not be used to assess the severity of AR since regurgitant jets are frequently eccentric, constrained by and entrained within the LVOT, leading to rapid jet broadening (Figure 4).
7. Using a clock face to represent the short-axis view (placing the tricuspid valve at 9 o'clock) may be helpful for recording the jet location and number, and useful for follow-up comparisons (Figure 3).
8. Echo assessment of valve implant depth is important to assist the implanter in assessing the mechanism and potential mediation (i.e. post dilatation, valve repositioning, placement of a second valve or even possible plug placement) of significant AR when present.

Three-dimensional echocardiography with CD can be used to planimeter the vena contracta, an estimate of the regurgitant orifice

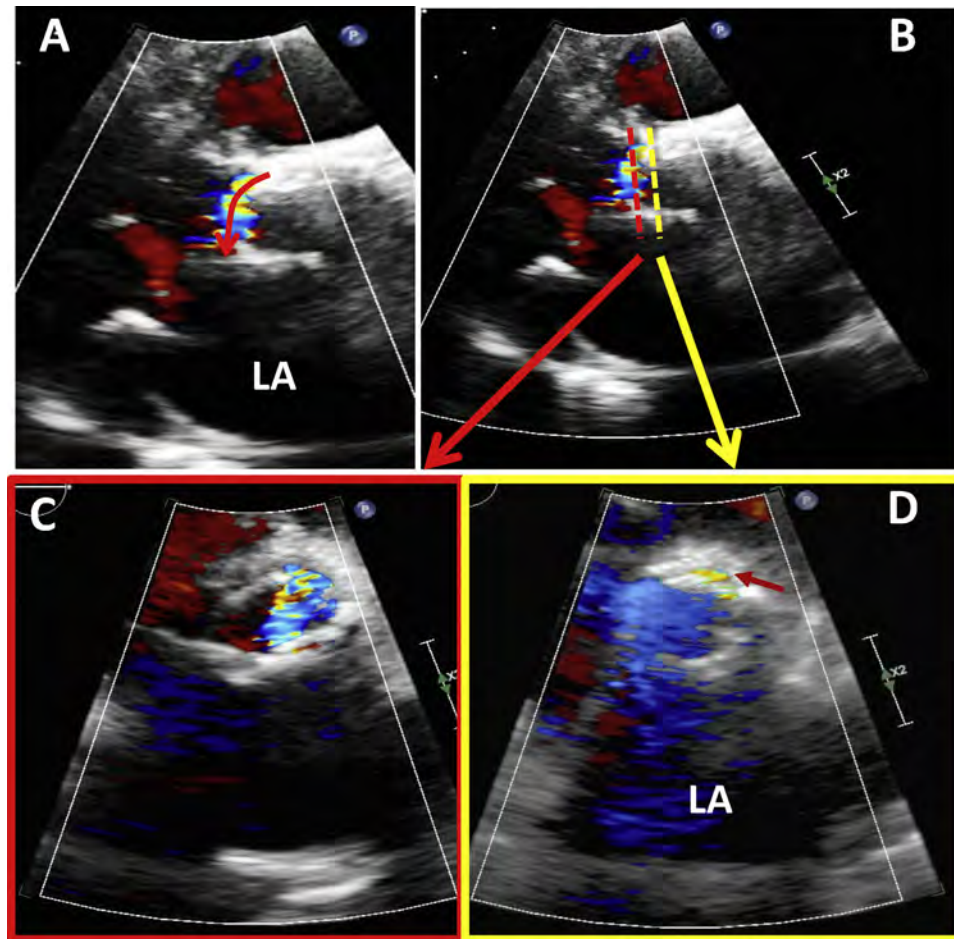


Figure 4 Effect of AR eccentricity on color Doppler jet recording in assessing PVR severity after TAVR. Scanning of the whole stented valve in short axis is needed to identify the vena contracta of the jet(s). Proper plane selection of the short axis is critical. In the case of an eccentric jet in the LVOT (**A**; *curved arrow*), the plane below the valve ring (**B**; *dashed red*) shows a large color jet as it spreads in the LVOT (**C**), overestimating AR severity. By selecting the proper short axis at the aortic annulus (**D**), the regurgitant orifice is best depicted (*small red arrow*), more consistent with mild PVR. Similarly, a high short-axis view at the aortic root level (not shown) could be misinterpreted due to normal diastolic flow in the sinuses of Valsalva or coronary arteries; flows in these locations, however, are of lower velocity and are not aliased.

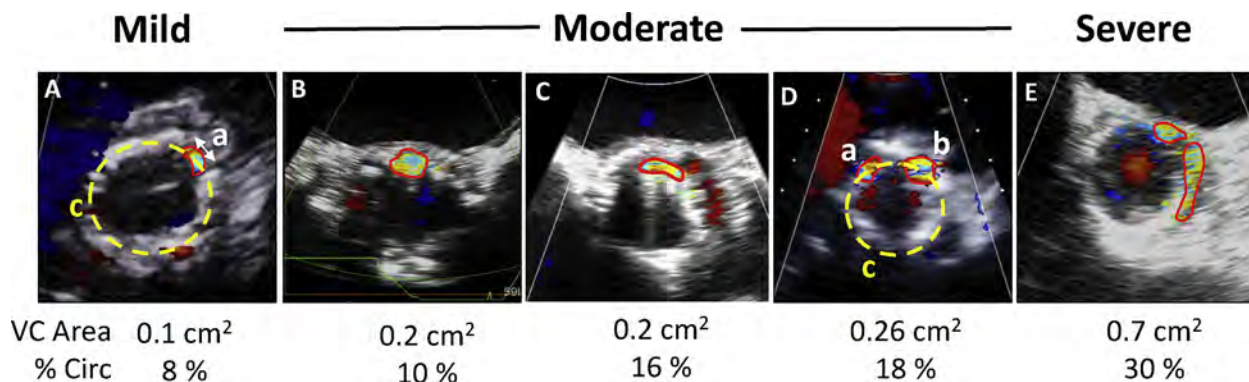


Figure 5 Examples of paravalvular regurgitation of different degrees of severity using short-axis color Doppler depicting two criteria: vena contracta area (VCA), and % circumferential (Circ) extent of the jet in relation to the total circumference of the prosthetic valve ring. % Circ is calculated as the length of the jet along the valve curvature (“a” in Panel **A**) divided by the total perimeter (“c” in panel **A**) as: $(a/c) \times 100$. In the case of two jets (**D**), % Circ would be $[(a + b)/c] \times 100$. As the VCA and circumferential extent of the jet increase, AR severity is more significant. However, VCA in TAVR is affected by both circumferential extent and thickness of the PVR, i.e., separation of the valve from the aortic wall. As shown in Panels **A** and **B**, the circumferential extent may at times be similar to those of mild regurgitation but the thickness of the PVR is large, leading to a larger VCA (**B**). Similarly, Panels **B** and **C** depict two lesions of similar moderate severity by VCA but different circumferential extent. These considerations are very important in assessing mild and moderate AR severity and multiple jets (**A-D**). Once circumferential extent exceeds 30%, PVR is usually severe.

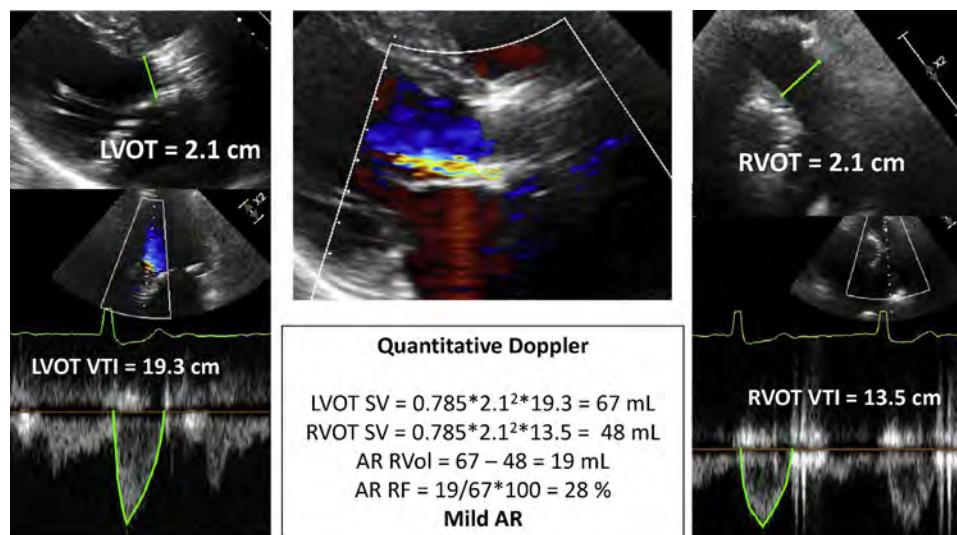


Figure 6 Quantitative Doppler for assessing regurgitant volume (RVol) and regurgitant fraction (RF) in a patient with AR after TAVR. Stroke volume (SV) is calculated at the LVOT and RVOT in this patient with mitral annular calcification. Flow quantitation complements other assessments of AR severity.

area.⁶⁰⁻⁶² Studies have shown the feasibility of measuring AR 3D vena contracta area (VCA) in native valves^{61,63-65} as well as post-TAVR.⁶² The primary pitfalls of this technique at this time are low frame rates and color blooming artifacts, which may be resolved with more advanced 3D technology.

b. Continuous-Wave and Pulsed-Wave Doppler.—Classically, two parameters from CWD recordings have been used in the evaluation of AR: velocity waveform density and the deceleration rate (pressure half-time). These may have limited applicability in the TAVR population. The common occurrence of multiple PVR jets limits the utility of CWD spectral density from a single jet; however, a very dense velocity waveform recording may signal at least moderate AR. In the current elderly patient population undergoing TAVR, ventricular and aortic compliance abnormalities may limit the use of pressure half-time for assessing the severity of PVR. A recent computational modeling study confirmed that increasing LV and/or aortic stiffness led to faster decay of the transvalvular pressure gradient and, therefore, to a faster decrease of diastolic flow velocity across the aortic valve compared with normal stiffness with the same regurgitant orifice. This faster decay led to both a shorter pressure half-time (simulating greater AR severity) and a lower regurgitant fraction (indicating less AR severity).⁶⁶

Flow reversal in the descending aorta recorded with pulsed-wave Doppler may similarly be of limited value in the setting of abnormal aortic or ventricular compliance. A number of studies in patients with hypertension have shown some flow reversal in the descending aorta in the absence of AR.^{67,68} Thus, in order to use this parameter for assessing post-TAVR regurgitation severity, a pre-TAVR assessment of descending aortic flow is essential. In the absence of baseline flow reversal, a new holodiastolic reversal of flow in the descending thoracic aorta is consistent with at least moderate AR,⁵⁶ and likely severe if the end-diastolic velocity is >20 cm/s at a normal heart rate.⁶⁹ In severe bradycardia, holodiastolic flow reversal may not be seen, despite the presence of severe AR. Flow reversal in the abdominal aorta is a more specific indication of significant regurgitation.⁷⁰

c. Quantitative Doppler Assessment of PVR Severity.—Quantitation of prosthetic AR involves the calculation of regurgitant volume (RVol), regurgitation fraction (RF), and less often, effective regurgitant orifice area (EROA; **Figure 6**). The methods for calculating these parameters are well described in prior guidelines.⁶ However, it is important to highlight a few issues that may be encountered in the TAVR population that can modulate the approach to quantitation, the accuracy of the derived parameters, and their clinical implications in assessing PVR severity.

Methodology: RVol in aortic regurgitation is derived as total LV stroke volume minus systemic stroke volume. LV stroke volume is quantitated with either pulsed-wave Doppler at the LVOT site or with a volumetric approach (the difference between LV end-diastolic and LV end-systolic volumes). There are challenges to calculation of LV stroke volume in the LVOT by PWD in the TAVR population. This stems from the measurement of LVOT diameter in the presence of the prosthetic valve as it protrudes into the LVOT (in contrast to a sutured surgical valve at the aortic annulus). The core lab methods for calculating LVOT stroke volume and aortic valve area following implantation of the balloon-expandable and self-expanding valve have been recently published.⁷¹ It is important to match the location of the PWD sample volume with the location of diameter measurement of the THV for accurate stroke volume calculations (**Figure 7**). The preferred approach is to measure the LVOT diameter from the outer-to-outer border of the stented valve at its ventricular tip, with the corresponding PWD sample volume just apical to the valve stent (**Figure 7**, upper panels). In the case where the prosthesis is positioned too deep into the LVOT, encroaching on the anterior leaflet of the mitral valve, an in-stent diameter measurement is performed at the mid-stent level (level of leaflets), with the PWD sample volume positioned into the stent but proximal to the valve (**Figure 7**, lower panels).⁷¹ In cases of technical difficulty, the LV volumetric method is used, provided there is no significant mitral regurgitation.

For LV volumes measurements to derive SV, avoidance of LV foreshortening is essential. In general, 3D volumes are preferred to 2D

Stroke Volume Measurement in LV Outflow in TAVR

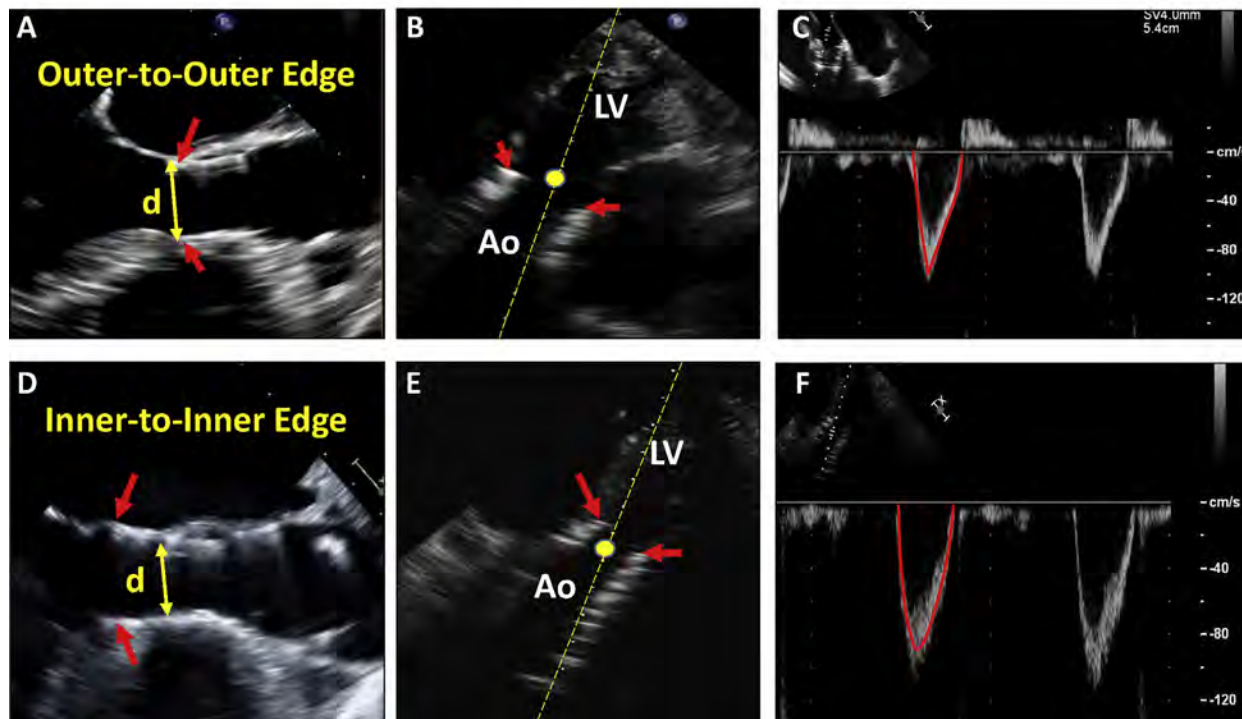


Figure 7 Calculation of stroke volume in the LVOT in transcatheter aortic valves. The default approach is to measure the LVOT diameter using the outer edge-to-outer edge diameter at the lower (ventricular) end of the valve stent (**A**, arrow). The pulsed-wave Doppler (PWD) sample volume is placed immediately proximal to the site of flow acceleration at the inlet to the stent (**B**). Stroke volume is then calculated as usual, assuming a circular LVOT geometry as: $0.785 \cdot d^2 \cdot \text{VTI}$. In instances where a self-expanding valve is placed low in the LV, particularly if the lower end of the stent is not in close proximity to the anterior mitral leaflet and interventricular septum, an alternative approach is to measure the inner edge-to-inner edge diameter of the valve stent immediately proximal to the cusps (**D**). The PWD sample volume should be placed just inside the stent but proximal to the site of flow acceleration at the cusps (**E**). Note that with transcatheter valves there is flow acceleration at the inlet to the stent and again at the cusps. Red arrows point to the lower end of the stent. Panels **C** and **F** show the respective PWD recordings in the LVOT.

determinations. In studies with suboptimal endocardial definition, contrast-echo enhancement is recommended to avoid underestimation of ventricular size and thus underestimation of all measurements of total SV, RVol, and RF. Lastly, for determination of systemic stroke volume, the usual mitral valve (MV) site with PWD used for mitral inflow volume may be problematic in this population, as the mitral annulus is frequently calcified, hindering the measurement of mitral annular diameter and derivation of accurate annular area. The mitral annulus site may also be problematic in the presence of more than mild mitral regurgitation. In these circumstances, the pulmonic annulus is an alternative site to calculate systemic stroke volume (Figure 6).

Lastly, EROA can be derived from the ratio of RVol to the velocity time integral of the AR jet, obtained by CWD. This is rarely performed in clinical laboratories. EROA using the proximal isovelocity surface area (PISA) method is usually not feasible because the flow convergence from the apical window is shadowed frequently by the prosthesis and its shape is typically non-hemispheric.

Severity of PVR using quantitative criteria: Whereas quantitative grading schemes have been advocated for the evaluation of prosthetic valve regurgitation, there is little data to support the use of these quantitative parameters in the context of acute PVR, shortly after TAVR. The PARTNER IA study reported a mean LVOT Doppler stroke volume in patients with \geq mild AR following TAVR of 68 ± 20 mL,¹⁴

which has been supported by larger studies.⁷² The usual cut-off for severe chronic native AR (RVol of >60 mL) seems inappropriate early after TAVR in this population with LV hypertrophy, smaller LV cavity size, and abnormal ventricular compliance. The effect of relatively small RVols on patients with abnormal ventricular and aortic compliances could explain why even mild regurgitation may have a significant impact on clinical outcomes post-TAVR.^{12,19}

Regurgitant fraction may be a more physiologically important parameter that normalizes for the lower stroke volumes seen in this population. In fact, CMR grading of PVR relies on RF and is discussed below. According to ASE guidelines, mild AR has a RF $<30\%$, moderate AR, a RF of $30\text{--}50\%$, and severe AR a RF of $>50\%$.^{6,7} Data in the TAVR population using CMR measures of PVR severity showed a reduced survival with a regurgitant fraction of 30% ,⁷³ supporting the use of this cutoff for moderate AR post-TAVR. Harmonizing grading schemes between imaging modalities may minimize discordance between the two techniques.

Continued follow-up of patients following TAVR is recommended, particularly in the setting of recent data suggesting PVR may improve over time^{74,75} and because of the unclear long-term durability of these valves. Patients with uncomplicated THV implantation should undergo a comprehensive TTE soon after implantation to establish baseline valvular function, and subsequently at

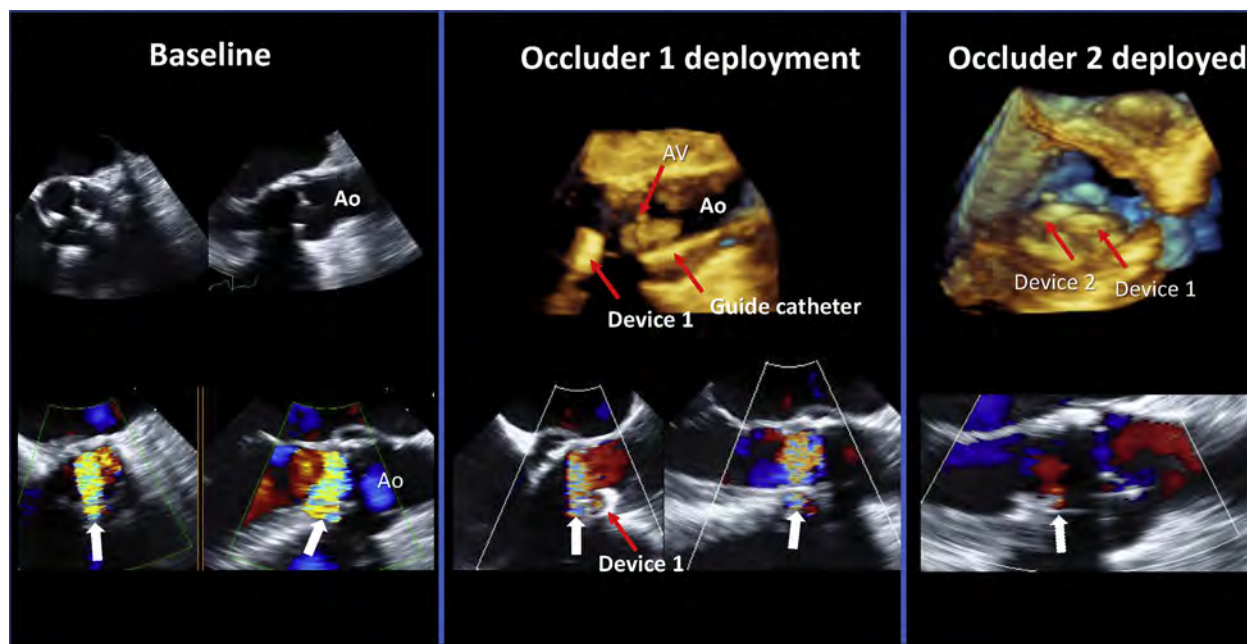


Figure 8 Repair for bioprosthetic aortic paravalvular regurgitation. At baseline: 2D color Doppler depicts very eccentric paravalvular AR evident in both short-axis (*left*) and long-axis (*right*) TEE views (*arrows*). An occluder device is deployed with reduction of color Doppler intensity but with significant residual PVR noted medial to device #1 (*white arrows* in center image, bottom). Occluder device #2 was deployed medial to occluder device #1 with immediate reduction in PVR severity to trace (*white arrow*).

1-3 months and 1 year. Studies should also be performed if unexpected clinical deterioration or new murmurs occur after THV. TTE is used to identify complications of the procedure, especially PVR, and changes in LV or RV function, assess aortic root structure and valvular function, and measure PA pressure. The baseline post-TAVR TTE is integral to accurate follow-up, since changes in baseline hemodynamics (increase in mean gradient of ≥ 10 mm Hg or 1 grade in AR) are an indication of possible valve deterioration or complication.⁷⁶

F. Assessing Residual AR after Percutaneous Repair of Prosthetic Paravalvular Regurgitation

The recently published Paravalvular Leak Academic Research Consortium Expert Statement reviews the technical aspects of performing PVR closure after SAVR or TAVR.⁷⁷ The document also defines the clinical endpoints reflecting safety and effectiveness of transcatheter devices, as well as the single and composite clinical endpoints for clinical trials. The therapeutic endpoint should be understood prior to the procedure. If the procedure is being performed to address heart failure, any reduction in RVol is desirable. If, on the other hand, the procedure is to address hemolysis, then complete or near obliteration of the leak should be the objective. In deciding when and how to address PVR after SAVR or TAVR, it is important for the imaging physician to understand the underlying mechanism of the paravalvular regurgitation; this should guide the treatment approach and may also predict whether a transcatheter closure device will be successful in treating the regurgitation.

Localization and grading of residual AR after repair is assessed primarily with TEE or TTE as described for acute intra-procedural TAVR assessment (Figure 8). In addition to grading of the regurgitation, an assessment of the effects of regurgitation in the chronic setting should include an evaluation of change in LV size and function, PA pressures,

and the effect of high pulmonary pressures on right ventricular size and function.

G. Integrative Approach to Assessment of AR

The evaluation of AR by Doppler echocardiography after percutaneous interventions on the aortic valve should be a comprehensive and integrative process, based on all the information collected during the examination, since each of the parameters used in this evaluation has advantages and limitations. In all cases, one should routinely perform a comprehensive sweep of the implanted valve by 2D and CD echocardiography, which includes an assessment of LV size and function, as well as velocity recordings in the LV outflow tract, mitral and pulmonic valve annuli, and in the proximal descending aorta and/or abdominal aorta. CW Doppler of the AR jet should also be routinely recorded but only utilized if a complete signal is obtained. Recordings of CD and pulsed-wave Doppler of prosthetic valve AR are more challenging compared to native AR due to the valve structure and mechanism of residual AR after aortic valve interventions.

Based on data in the literature and a consensus of the committee members, the Writing Group proposes a scheme for evaluation of patients with AR (Figure 9). It is in a similar format to the scheme recently proposed for native valve AR, but differs in the incorporation of VCA and % circumferential extent of VC, the removal of the conventional AR jet width/LVOT diameter ratio because of AR jet eccentricity, and the consideration of LV size and function.⁷ In applying this scheme, it is the consensus of the committee members that the process of grading AR should be comprehensive, using a combination of signs and measurements obtained by Doppler echocardiography. If the AR is definitely determined as mild or severe using these specific signs, no further measurement is required, particularly for mild lesions. If there are only a few parameters consistent with mild or severe AR, and the quality of the primary data lends itself to quantitation, it is

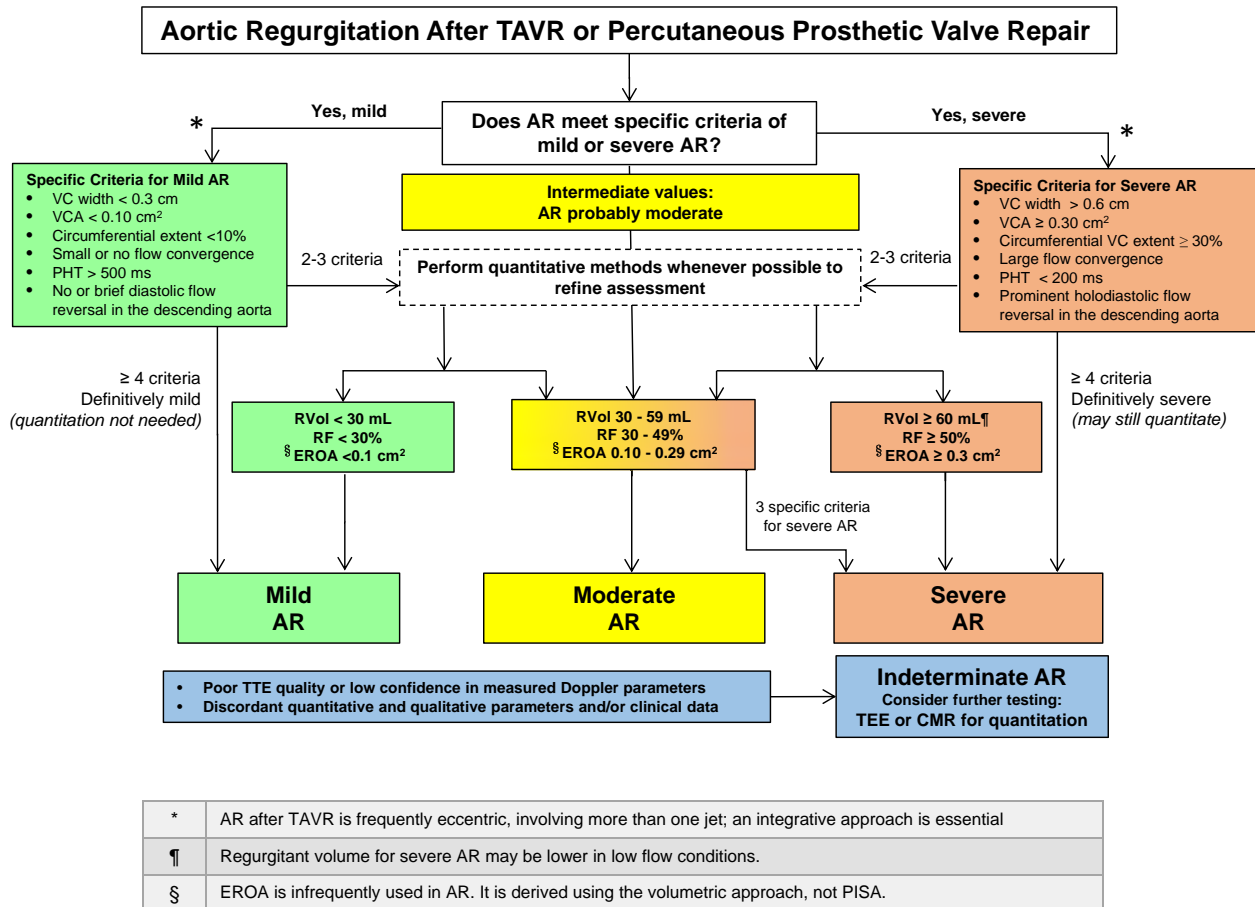


Figure 9 Suggested algorithm to guide implementation of integration of multiple parameters of AR severity after TAVR or prosthetic aortic valve repair. Good-quality echocardiographic imaging and complete data acquisition are assumed. If imaging is technically difficult, consider TEE or CMR. AR severity may be indeterminate due to poor image quality, technical issues with data, internal inconsistency among echo findings, or discordance with clinical findings.

desirable for echocardiographers with experience in quantitative methods to measure quantitatively the degree of AR, including the regurgitant volume and fraction as descriptors of volume overload. The effective regurgitant orifice area, a descriptor of lesion severity, is less frequently used after aortic valve interventions. As previously mentioned, quantification of EROA via PISA is limited in TAVR; hence quantification via the volumetric approach is recommended. Grading of AR in this population is more challenging than in native AR and for this reason and the errors involved in quantitation, a three-grade system is proposed (mild, moderate, and severe). When the evidence from the different parameters is congruent, it is easier to grade AR severity. When parameters are contradictory, one must look carefully for technical and physiologic reasons to explain these discrepancies and rely on the components that have the best quality of the primary data and that are the most accurate considering the underlying clinical condition. In situations where the assessment is difficult and indeterminate, provides contradicting echo/Doppler data that cannot be resolved or conflicts with the clinical presentation, further testing is advised with either TEE or CMR. TEE in this scenario can provide the mechanism of AR and quantitation of VC area and circumferential extent. CMR, on the other hand, can provide quantitation of RVol and RF (see below).

H. Role of Cardiovascular Magnetic Resonance in Evaluating AR

A few studies have demonstrated the feasibility of CMR for evaluation of PVR after TAVR.⁷⁸⁻⁸¹ There are a number of advantages of CMR for assessing PVR in this setting, including the ability to measure RVol irrespective of the number of regurgitant jets or their morphology,⁸² the high reproducibility of measurements,⁸³ and the ability to measure RVol for multiple valve lesions.^{80,81,84} LV volumes and function can also be assessed using standard cine CMR sequences. Few pitfalls of the technique exist, and the cost, access to scanners, and expertise with valve disease continue to be barriers to widespread use.

The direct measurement of forward and reverse flow volumes in the aortic root by CMR facilitates the calculation of aortic RF for assessment of PVR severity (Figure 10). PVR can be visualized in the cine CMR three-chamber view using the steady-state free precession (SSFP) technique. Due to intra-voxel spin dephasing, a regurgitant jet causes a signal change that is either bright or dark depending on the direction of phase encoding. However, due to susceptibility artifact from the valve frame, identification of regurgitant flow can often be challenging (Figure 10). Alternatively, phase-contrast imaging in a CMR three-chamber view using in-plane phase

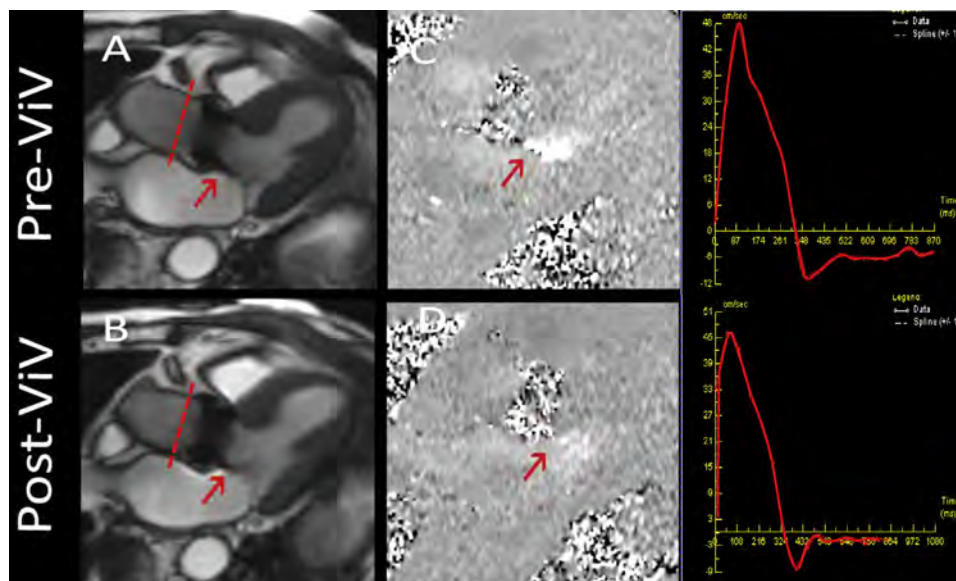


Figure 10 CMR for evaluation of PVR after TAVR and subsequent valve-in-valve (ViV) implantation for treating residual AR. Three-chamber cine view showing the PVR jet (red arrow) after TAVR (A). (B) shows the decreased severity of PVR after ViV placement. Phase-contrast imaging of the flow through the prosthetic valve (C and D) shows the PVR jet, which has decreased significantly after ViV. The right panels show the flow-volume curves through the aortic valve (plane of acquisition in A & B) before and after ViV placement. Significant backward flow was seen due to PVR with a RF of 36% (moderate severity). After ViV placement, regurgitation was reduced and the RF decreased to 12% (mild severity).

encoding can be used to more reliably visualize the jet. Given the 2D nature of both SSFP and phase-contrast imaging, eccentric regurgitant jets may be missed. The major advantage of CMR in the characterization of PVR is the ability to quantify regurgitant flow regardless of whether a regurgitant jet has been visually identified. This is accomplished via through-plane phase-contrast imaging acquired at the level of the aortic root immediately above the transcatheter heart valve. This allows the direct measurement of forward stroke volume and RVol, and subsequent calculation of regurgitant fraction (Figure 10). Contrary to TTE, this technique is not affected by potential variability in the shape of the regurgitant orifice during the cardiac cycle. Furthermore, the quantitative approach by CMR has very low observer variability compared to either 2D or 3D TEE.^{82,85,86} Preliminary data have shown that paravalvular AR severity grading with TTE may be underestimated compared to quantitative CMR.⁷⁹ Limitations of the phase-contrast technique include signal loss due to complex flow, velocity encoding choices in stenosis/regurgitation, temporal and spatial resolution, and that reverse flow by CMR includes coronary flow in addition to AR,⁸⁷ partially explaining the variable cutoffs for mild AR in previous studies. Alternatively, the indirect method can be used to calculate RVol and RF. This involves comparison of total LV stroke volume derived in the aorta with phase contrast or from LV volumes, to stroke volume in the pulmonary artery or from the right ventricle (in the absence of significant tricuspid or pulmonic regurgitation), which reflect systemic stroke volume.⁷

Similar to native valve disease, when the clinical presentation and TTE results do not concur, CMR at centers with appropriate expertise should be considered for further evaluation of PVR, especially when a therapeutic intervention is under consideration.⁷ CMR-based phase-contrast imaging provides direct, accurate, and reproducible quantification of valvular regurgitation.⁸⁸⁻⁹⁰ AR quantification is more reproducible by CMR compared to echocardiography in native valve disease.^{83,91,92} CMR-derived quantitative findings also have

been shown to have prognostic value in native AR⁹³ as well as in post-TAVR patients.⁷⁸

A number of different cutoffs for defining severity of aortic regurgitation after TAVR have been used, adding to the confusion in the literature. RF cut-offs for severe AR after TAVR in small populations ranged between >30% and >40%,⁸⁵ and quantitative RF values of AR severity obtained by phase-contrast imaging were lower than those obtained by echocardiography.^{94,95} However, strong outcomes evidence from recent trials using TTE grading suggests that this may not be the case and that TTE can accurately assess severity.^{2,10} Gelfand *et al.*⁹⁵ have shown that the CMR cutoffs that optimized the correlation with integrative echocardiographic grades were similar to those recommended for both native and surgical prosthetic AR in guidelines published by the American Society of Echocardiography: mild <30%, moderate 30-50%, and severe >50%.^{6,7} Developing a unified grading scheme would help determine the true differences between imaging techniques, since obtaining a routine CMR in this elderly population with high prevalence of pacemakers is frequently not possible.

Key Points

Assessment of paravalvular regurgitation after aortic valve interventions

- Paravalvular regurgitation (PVR) is a complication of transcatheter aortic valve replacement (TAVR). Recent observations with newer valve designs suggest that the incidence of PVR is low (0-2%) and that mild or lesser PVR does not affect outcomes.
- Imaging prior to TAVR (echocardiography and multi-detector computed tomography) and intra-procedural imaging (echocardiography and fusion imaging) can predict and reduce the risk of PVR following TAVR. The predictors of PVR include:

under-sizing the transcatheter heart valve (THV), severe valve/annular calcification and inappropriate positioning of the valve.

- Intra-procedural echocardiography may be performed using transesophageal (TEE) or transthoracic (TTE) imaging; each approach has its advantages and limitations in assessing TAVR results and severity of PVR. Because echocardiographic views and availability of Doppler parameters are limited during the procedure (color Doppler and flow pattern in descending aorta), confirming the severity of PVR with aortography and invasive hemodynamics may be needed if echocardiographic imaging is non-diagnostic.
- Color Doppler is the first-line method for detecting and assessing severity of aortic regurgitation (AR) after TAVR. However, the limitations of echocardiography and characteristics of PVR jets both introduce challenges: 1) From parasternal or esophageal views, there is ultrasound attenuation from the valve in the far field, necessitating the use of multiple imaging windows to detect all AR jets, including apical views (for TTE) and deep transgastric views (for TEE); 2) AR after TAVR frequently arises from multiple jets that are often eccentric; 3) In the setting of stent frame non-conformability, intact calcified leaflets, and open THV cells, there are frequently multiple small PVR jets traveling in atypical directions; 4) Conventional AR jet width/LVOT diameter ratio cannot be used to assess AR severity because of jet eccentricity.
- Evaluation of residual AR after TAVR should be comprehensive and include assessment of: 1) THV shape and position; 2) The number and location of the regurgitant jets; 3) Vena contracta width and area; 4) Circumferential extent of the regurgitant jets (with careful consideration of non-contiguous, small, discrete jets); 4) Duration of diastolic flow reversal by PWD in the descending and/or abdominal aorta; 5) Continuous-wave Doppler velocity waveform density and pressure half-time; 6) Methods for quantifying regurgitant volume, regurgitant fraction, and, less often, effective regurgitant orifice area.
- When more than mild AR is suspected but the data are equivocal, CMR should be performed (at centers with appropriate expertise) to quantitate aortic regurgitant volume and fraction, as well as LV chamber volumes.

IV. PERCUTANEOUS MITRAL VALVE INTERVENTIONS

There are 4 major categories of percutaneous mitral valve interventions aimed at reducing MR: mitral valve leaflet repair (edge-to-edge clip, and placement of artificial chords), transcatheter mitral valve replacement, mitral annuloplasty, and catheter-based plugging of paravalvular leaks. Among these, edge-to-edge repair is the only catheter-based MV intervention approved by the United States Food and Drug Administration (USFDA) for commercial use and thus will be detailed in this document. Each intervention has unique issues regarding both intra-procedural and post-procedural assessment of residual MR. However, the general principles of assessing residual MR with Doppler echocardiography after percutaneous mitral interventions are similar to those recently published in detail for native and prosthetic valves.⁷ The current document will focus on

the 4 categories of percutaneous MV interventions with comments and caveats for assessing residual MR during the procedure, followed by an overall evaluation of MR outside the catheterization laboratory common to these interventions. TEE (2D & 3D) is the main imaging modality for guiding the procedures and evaluating their immediate success, while TTE is the main initial modality outside the catheterization laboratory. Similar to all regurgitant lesions, an integrative approach using various parameters is essential in the overall evaluation of the severity of residual MR.

A. General Considerations in Evaluating Residual MR during MV Interventions

Unlike PVR after TAVR for aortic stenosis, which represents a new lesion, residual MR after most mitral interventions involves assessment of the reduction in MR severity from baseline, as most current MV interventions are aimed at reducing MR. An assessment of changes in both hemodynamics and Doppler echocardiographic parameters is important in the overall evaluation of acute changes in MR severity during MV repair or replacement. Table 5 depicts the hemodynamic and Doppler parameters that can be evaluated with TEE during the procedure and their implications for severity of MR. CD is the main Doppler modality for assessing MR (site, number of jets, eccentricity, vena contracta, and flow convergence) prior to and during the procedure, with special considerations and limitations depending on the type of MV intervention (see text below and Table 5). The pulmonary vein flow pattern is used together with other findings in an integrated fashion to assess residual MR; it should be meticulously interrogated in all patients before and during the procedure. Patients with severe MR have either systolic blunting or systolic flow reversal in one or more pulmonary veins. Normalization of pulmonary vein flow after MV interventions strongly suggests that MR has been reduced to mild, with normalization of left atrial (LA) pressure (Table 5). Failure of pulmonary vein velocity pattern to improve suggests insufficient MR reduction. Recently, these intra-procedural changes in pulmonary vein flow patterns have been shown to predict re-hospitalization and mortality after the procedure.⁹⁶ Appearance of spontaneous contrast in the LA after MV intervention also suggests significant reduction in MR severity. The mitral inflow velocity pattern [(decrease in mitral E velocity and velocity time integral (VTI)] may be helpful in assessing reduction of MR, particularly in procedures that do not change actual MV structure (annuloplasty and repair of PVR). A change from an E-wave-dominant to an A-wave-dominant pattern suggests mild residual MR. Furthermore, measurement of velocity in the LVOT with TEE from deep transgastric views, while challenging, may be helpful in demonstrating an increase in velocity and thus systemic flow. Lastly, a decline in LV ejection fraction after MV intervention suggests significant MR reduction because of increased afterload, absent other causes (ischemia, pacemaker-related, etc.).

Hemodynamically, the resolution of a regurgitant v wave and reduction of left atrial or pulmonary pressures provide important clues to improvement in MR severity that might be particularly helpful when residual MR severity is difficult to assess with color Doppler. It is also common to observe a 10-15 mm Hg increase in systolic blood pressure immediately after a successful reduction in severe MR, reflecting an increase in forward stroke volume. On the other hand, it is important to note that MV interventions are performed under general anesthesia, which may alter hemodynamics in a way that can reduce the severity of MR. Consequently, assessment of MR severity before and immediately after mitral interventions should be

Table 5 Hemodynamics and TEE parameters useful in determining residual MR severity during MV interventions in the catheterization laboratory

Parameter	Assessing severity of residual MR
Invasive hemodynamics	Decrease in regurgitant <i>v</i> wave, LA pressure, and pulmonary pressures are specific signs of reduction in MR severity; Consider effects of general anesthesia on MR severity
General echocardiographic findings	
Spontaneous echo contrast in LA	Appearance of spontaneous contrast after MV intervention suggests significant reduction in MR severity
LVEF	Decline in LVEF after MV intervention suggests significant MR reduction in the absence of other causes (ischemia, pacemaker-related, etc.)
Color Doppler	
Color Doppler jet (size, number, location, eccentricity)	<ul style="list-style-type: none"> - Easy to obtain with a comprehensive, systematic approach - Difficult to assess multiple and eccentric jets - Jet area affected by eccentricity, technical and hemodynamic factors (especially driving velocity)
Flow convergence	<ul style="list-style-type: none"> - Large flow convergence denotes significant residual MR whereas a small or no flow convergence suggests mild MR - Difficult to use in presence of multiple jets or very eccentric jets, or may be masked by the device
Vena contracta width	<ul style="list-style-type: none"> - VCW ≥ 0.7 cm specific for severe MR - Difficult to use in presence of multiple small jets or very eccentric jets for which orifice shape is not well delineated
Vena contracta area (3D planimetry)	<ul style="list-style-type: none"> - Allows better delineation of eccentric orifice shape and possibly the addition of VCA of multiple jets - Prone to blooming artifacts
Spectral Doppler	
Pulmonary vein flow pattern	<ul style="list-style-type: none"> - Systolic flow reversal in >1 vein specific for severe MR - Increase in forward systolic velocity after MV intervention helps confirm MR reduction
MR jet profile by CWD (contour, density, peak velocity)	<ul style="list-style-type: none"> - Dense, triangular pattern suggests severe MR - May be hard to line up CWD properly in flail leaflet or very eccentric jet after intervention
Mitral inflow pattern	<ul style="list-style-type: none"> - In sinus rhythm, mitral A-wave-dominant flow excludes severe MR - Decrease in mitral E velocity and VTI suggests reduction in MR severity
Pulsed Doppler of LVOT (deep transgastric view)	Increase in LVOT velocity and VTI after procedure suggests MR reduction
Quantitative parameters	In general, more difficult to perform; some procedure-specific limitations in quantitation
EROA by PISA	<ul style="list-style-type: none"> - Not recommended after edge-to-edge repair because assumption of hemispheric proximal flow convergence is violated by the device. - PISA often underestimates MR severity in the presence of multiple jets or markedly eccentric jets. - Not feasible in PVR of mechanical prosthetic MV or possibly TMVR (flow masking in LV by TEE)
Regurgitant volume	- Difficult to perform volumetric RVol with pulsed Doppler by TEE

CWD, Continuous-wave Doppler; EROA, effective regurgitant orifice area; LA, left atrium; LVEF, left ventricular ejection fraction; LVOT, left ventricular outflow tract; PISA, proximal isovelocity surface area; PVR, paravalvular regurgitation; TEE, transesophageal echocardiography; TMVR, transcatheter mitral valve replacement; VCW, vena contracta width; VCA, vena contracta area; VTI, velocity-time integral.

performed under similar loading conditions. Phenylephrine or intravascular volume expansion may be given to adjust systolic blood pressure or filling pressures to physiologic levels prior to final assessment of MR severity during the procedure.

B. Mitral Leaflet Repair

Edge-to-edge mitral leaflet repair is the only USFDA-approved percutaneous therapy and will be discussed in detail. Artificial chords are in

early feasibility trials and will not be discussed separately. It is expected that residual MR assessment after the latter procedure will be similar to surgical MV repair with valve preservation techniques.

1. Edge-to-Edge MV Repair. The MitraClip (Abbott Vascular Structural Heart, Santa Clara, CA) is a chromium cobalt device with two polyester-covered clip arms designed to grasp both MV leaflets in a similar fashion as edge-to-edge surgical repair. A similar device (PASCAL, Edwards Lifesciences, Irvine, CA) is in early feasibility

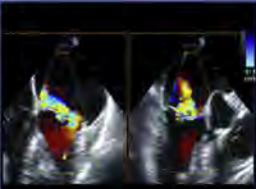
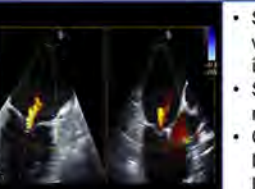
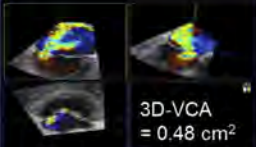
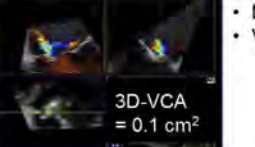

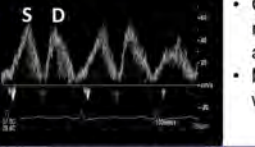

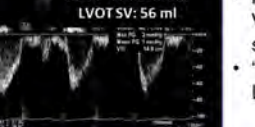
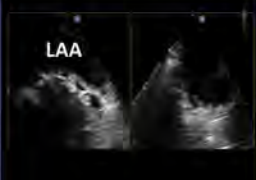
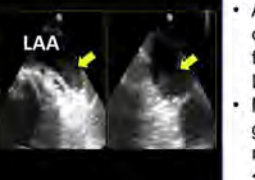
Findings of \leq Mild Residual MR	Baseline	After Edge-to-edge Repair	Specific Features
Significant reduction in color Doppler jet features			<ul style="list-style-type: none"> • Small vena contracta width (< 0.3 cm) of individual MR jets • Small flow convergence radius (≤ 0.3 cm) • Central MR jet with limited penetration into LA
Significant reduction in VCA by 3D color Doppler	 3D-VCA = 0.48 cm ²	 3D-VCA = 0.1 cm ²	<ul style="list-style-type: none"> • More tedious to perform • VCA < 0.2 cm²
Improvement or normalization of pulmonary vein flow	 D S	 S D	<ul style="list-style-type: none"> • Change from S-wave reversal or blunting to antegrade flow • Marked reduction in D-wave velocity
Improvement of forward stroke volume (Deep transgastric LVOT VTI); often with decrease in LVEF	 LVOT VTI: 9.12 cm LVOT SV: 35 ml	 LVOT VTI: 14.8 cm LVOT SV: 56 ml	<ul style="list-style-type: none"> • Marked increase in PWD VTI in LVOT and derived systemic stroke volume • "paradoxical" decrease in LVEF by 5-10%
New onset spontaneous contrast within LA or LA appendage	 LAA	 LAA	<ul style="list-style-type: none"> • Associated with low flow conditions including atrial fibrillation, and/or severe LV systolic dysfunction • Mean diastolic MV gradient may not be markedly elevated (e.g. < 7 mmHg)

Figure 11 Illustrative echocardiographic parameters of reduction of MR severity to mild after edge-to-edge mitral valve repair.

trials.⁹⁷ These devices are implanted via a transcatheter delivery system that is inserted into the LA from the femoral vein via transseptal puncture. TEE (2D and 3D) is used to guide the transseptal puncture and to steer the device to the appropriate MV pathology. A key part of the procedure is to visualize the stable capture and insertion of both leaflets into the clip arms. Once anterior and posterior leaflet insertion is verified, the clip is then closed more fully while TEE color flow imaging is used to assess MR reduction. This is typically done in the commissural view (mid-esophageal between 60-90 degrees) because it allows imaging of MR jets on both sides of the clip and across the entire coaptation plane of the MV. After confirmation of leaflet insertion, demonstration of MR reduction and a non-significant mitral pressure gradient post-clip implant, the clip is detached from the delivery system and permanently deployed. If needed, a second, or less frequently a third clip can be placed for further MR reduction. The decision to proceed with a second clip is complex and based on the degree of reduction of MR with the first clip, residual MR, mean mitral gradient and valve area, improvement in hemodynamics, and the technical feasibility of placing a second clip. Regardless of whether 1 or more clips are deployed, evaluation of the degree of MR reduction, the severity of residual MR, and the trans-mitral mean gradient are key components of the decision-making process and are predominantly guided by intra-procedural TEE. Table 5 and Figure 11 detail the echocardiographic parameters that are assessed

during edge-to-edge device deployment to evaluate the severity of residual MR. CD evaluation pertaining to edge-to-edge repair is further discussed below.

2. Evaluation of Residual MR with CD Immediately after Edge-to-Edge Repair.

CD allows rapid assessment of the presence or absence of MR. Despite its limitations,⁷ CD is the mainstay of intra-procedural TEE because of its simplicity. It is important to maintain the same ultrasound settings pre- and post-procedure. In vitro experiments have shown that when there are two or more MR jets, they tend to merge together and overestimate the severity of MR.⁹⁸ MR jets after clip deployment can be multiple, in different planes, of different severity, and may crisscross and merge, thus adding to the complexity of assessment of residual MR severity (Figure 12). Two or three small, thin jets emanating after deployment of a single clip resemble the washing jets from a bi-leaflet mechanical MV and are usually no more than mild MR. Factors indicative of at least moderate MR after edge-to-edge repair include a wide vena contracta or a prominent proximal convergence zone on the LV side. Because proximal convergence is constrained by the presence of the clip itself, angle correction would be required for the calculation of EROA by PISA.⁷ However, the requirement for angle correction and the frequent presence of 2 or more jets makes PISA less reliable and therefore, it is not recommended for flow quantitation and

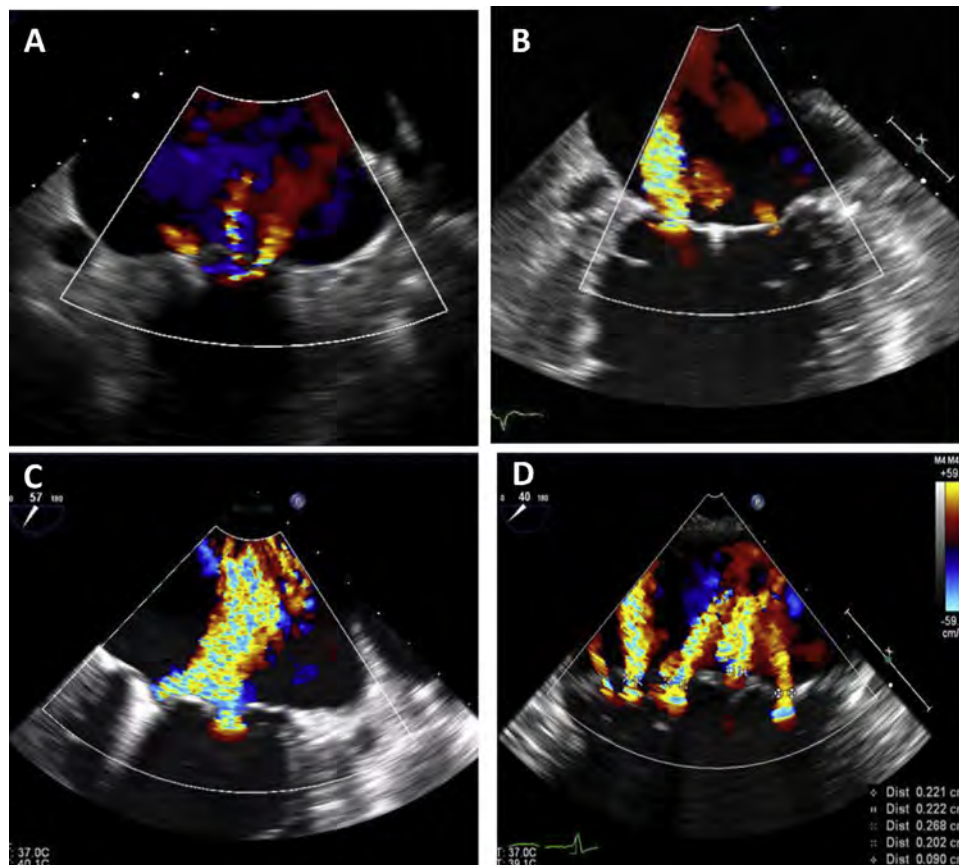


Figure 12 Challenges of multiple MR jets after edge-to-edge mitral valve repair. Transesophageal echocardiographic images from a mid-esophageal level. **(A)** Three separate, small jets are seen. **(B)** A large jet with a wide orifice is seen medial to the device with a very small jet laterally. **(C)** Two separate large jets, crisscrossing with a confluence close to the valve. **(D)** Five different residual jets of variable severity seen after deployment of a single clip.

derivation of EROA. 3D imaging of the vena contracta area(s) of the MR jet(s) after valve repair shows promise because of its quantitative nature and good correlation with CMR.⁹⁹⁻¹⁰¹ Each jet that is deemed significant would need to be analyzed separately for VCA, since they are often in different planes and with different orientations, and their VCAs are added (Figure 13). Further experience and validation is needed with this approach. Multiplying the velocity time integral of the CWD jet of MR by the total VCA provides, in principle, the RVol; however this has not been validated.⁷ 3D color can help identify, assess, and localize residual eccentric or wall-hugging MR jets not seen by 2D color flow imaging.

3. Interaction of Mean Transvalvular Gradient and Residual MR after Edge-to-Edge Repair. Mitral valve edge-to-edge repair causes a reduction in MV area (MVA). Reduction in MR after a first clip may reduce mitral E velocity but narrowing of the MV orifice may have an opposing effect. In the EVEREST I and II trials, an initial maximal MVA in early diastole was empirically chosen to ensure that clip placement did not cause mitral stenosis. Lubos *et al.*¹⁰² showed that a baseline MVA ≤ 3.0 cm² and a mean gradient ≥ 4 mm Hg were associated with a high risk of an aborted procedure due to potential mitral stenosis. Altiok *et al.*⁹⁹ found that mitral stenosis is unlikely to occur if the MVA is at least 4.1 cm² by 3D TEE. Further, a post-procedure mean gradient of ≥ 5 mm Hg is predictive of elevated mean gradient at discharge.¹⁰³ Thus, the MV gradient is always measured after clip implantation and is considered along with the re-

sidual MR grade in determining the need for and advisability of a second clip. On the other hand, residual moderate or greater MR can augment the diastolic gradient across the MV when a clip is present, which should also be taken into account when considering placement of an additional clip. In such a setting, an additional clip may reduce the transmitral diastolic gradient if the MR is effectively reduced.

C. Transcatheter Mitral Valve Replacement

1. TMVR Implantation. A few TMVR designs have been developed and successfully implanted in patients.¹⁰⁴⁻¹⁰⁸ None of these valves are currently US FDA-approved for commercial use. At this time, the Edwards SAPIEN 3 is US FDA-approved only in the setting of valve-in-bioprosthetic mitral valve. The valves specifically designed for TMVR share common requirements, including a proper seal at the mitral annulus, an anchor to the native structures, and avoidance of LVOT obstruction. The approach to implantation has initially been primarily trans-apical. However, transvenous transseptal implantation has also been successfully performed and will likely be the primary implant approach in the future.

Fluoroscopic imaging planes for the MV are well-defined,¹⁰⁹ and pre-procedural imaging planes for TMVR can be determined by multi-detector computed tomography.^{110,111} MDCT is particularly useful to comprehensively evaluate the entire MV landing zone, choose the appropriate device size, and evaluate the predicted neo-

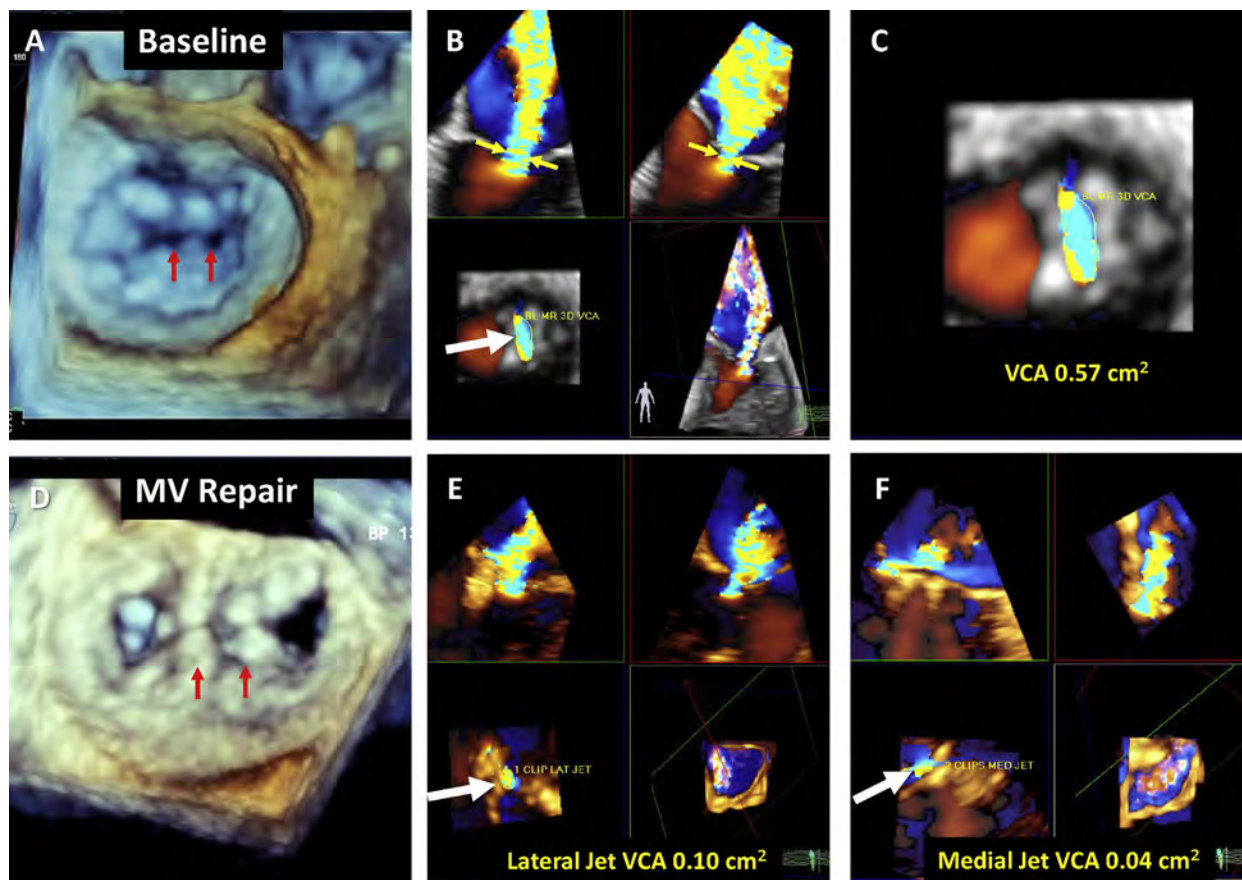


Figure 13 3D vena contracta area measurements by TEE during MitraClip implantation. **(A)** Baseline 3D en face view from the left atrium. Both leaflets were restricted with coaptation defects (*arrows*). **(B)** 3D quad images showing vena contracta width (*yellow arrows*) that is wider in bi-commissural view (*top left*) than long-axis view (*top right*). 3D vena contracta area (VCA, *bottom left*) is elliptical, seen in magnified view in **(C)**, measuring 0.57 cm². **(D)** 3D en face view from left atrium after placement of two MitraClips (*arrows*). **(E)** 3D vena contracta measurements after placement of two MitraClips orienting cut planes to lateral jet with VCA of 0.10 cm². **(F)** 3D vena contracta measurements orienting cut planes to medial jet with VCA of 0.04 cm². The combined VCA is 0.14 cm², consistent with mild MR.

LVOT after valve deployment.¹¹¹ For trans-apical implantation, the location of the apical puncture can be determined pre-procedurally by MDCT and confirmed during the procedure by TEE. Each device has unique aspects to implantation, but they all require TEE guidance to ensure that the guide wire and subsequent device delivery system are centrally located in the chord-free space between the middle segments of the valve (A2 and P2 segments) to avoid chordal rupture. During the TMVR procedure, the device can interfere with anterior leaflet closure and create transient acute severe MR. Prompt recognition of this problem by TEE and redirection of the delivery system is important. After deployment of the device, 2D and 3D imaging are used to confirm appropriate device seating, stability, orientation, and function (transvalvular gradient and the determination of central or paravalvular regurgitation). LVOT obstruction after TMVR may occur either due to the MV prosthesis itself or displacement of the anterior mitral leaflet into the LVOT. In addition to TMVR per se, implantation of TAVR valves in the mitral position in patients with native mitral annular calcification, complete annuloplasty rings, or prior bioprosthetic valves has been reported in large registries.^{112,113} The same principles of evaluating MR severity after such procedures is applicable.

2. Evaluation of Residual MR Immediately after TMVR.

Because the TMVR orifice is smaller than that of the native mitral valve, devices typically rely on skirts or flanges to seal off the native valve lines of coaptation to both competitive antegrade flow and PVR. As with all bioprostheses, there is a risk of central MR due to cusp malfunction, which is readily identified by CD. Acute central valvular regurgitation is uncommon, and may occur due to inadequate initial cusp motion, theoretically as a result of collapsing the valve or damaging the leaflets during delivery.

Early feasibility trials indicate that PVR occurs infrequently after TMVR.^{114,115} However, identification and localization of PVR after TMVR may be difficult, in contrast to central MR (Table 5). The valve flange or skirt causes acoustic shadowing, which may make it difficult to discern if the color jets that are seen moving across the annular plane are contained within the flange/skirt or enter the LA, causing MR. PVR may occur at any point along the perimeter of the valve; it is essential therefore to interrogate the valve systematically with multiple views and imaging angles and is best performed with 3D TEE. PVR following TMVR may result from suboptimal valve sizing that may leave native commissures/lines of coaptation exposed, which then can interfere with the seating of the valve and flange.

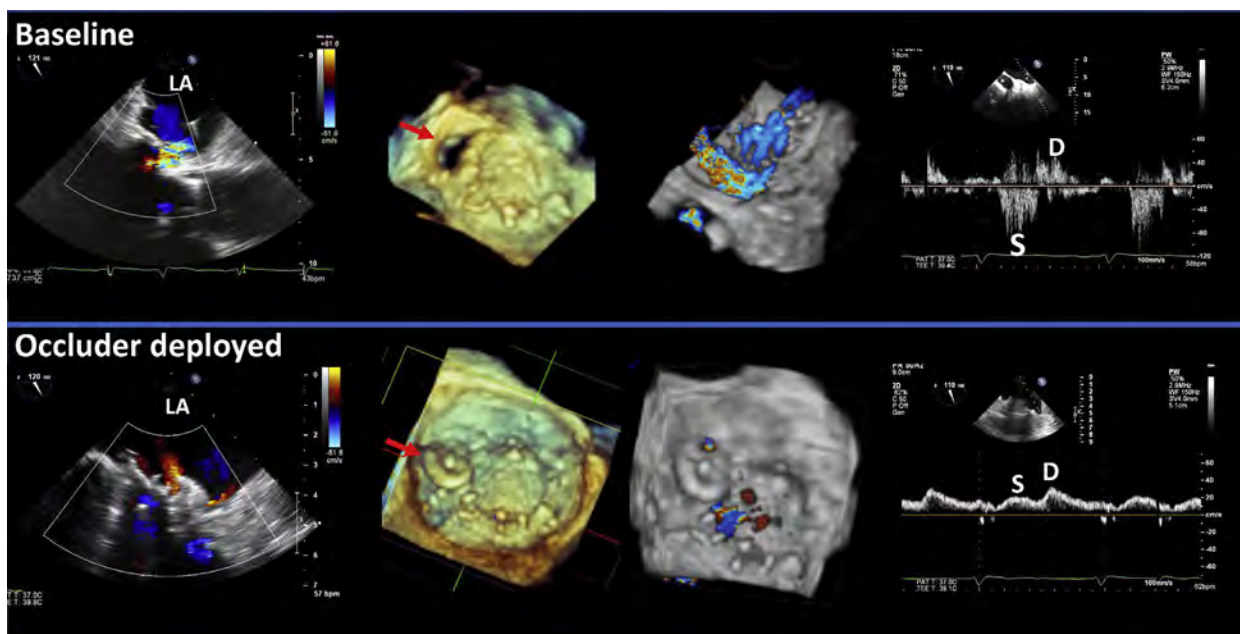


Figure 14 Plug repair for mechanical MV paravalvular regurgitation. At baseline: 2D color Doppler depicts paravalvular MR with a vena contracta diameter of 7 mm. A large paravalvular defect is noted at the 10 o'clock location (*arrow*). 3D color Doppler depicts a large paravalvular MR jet. The left upper pulmonary vein demonstrates systolic flow reversal (S). After deployment of an occluder: 2D color Doppler depicts two very small MR jets on either side of the repair device. The device is appropriately deployed within the paravalvular defect (*arrow*). 3D color Doppler depicts a very small residual paravalvular MR jet at the superior margin of the occluder device. Left upper pulmonary vein flow demonstrates systolic blunting but no reversal of flow.

This may also be exacerbated because of native annular or valvular calcification. Even with appropriate sizing, there may be inadequate seating due to insufficient capture of the native valve elements to which the prosthetic valve is anchored. This may be associated with excessive systolic movement of the valve, which may result in permanent or intermittent displacement of the valve flange/skirt into the LA. In extreme cases, complete valve dislodgement will result in severe MR.

Since experience with TMVR is limited, the approach to evaluating the severity of MR is extrapolated from that used for surgical mitral prostheses⁶ or native MR.⁷ CD is used to identify and localize the jet(s). Although jet dimensions may provide semi-quantitative information as to the degree of regurgitation, it should be noted that there has been no validation of jet dimensions in the setting of TMVR. Theoretically, measurement of VCW or VCA for discrete jets may be helpful but lacks validation after TMVR. Application of the PISA approach to PVR with TEE has significant limitations, as the PISA shells are rarely hemispheric, are usually truncated by adjacent walls, and are frequently shadowed by the prosthetic valve (Table 5). Non-holosystolic MR jets that typically are not associated with severe MR may be encountered post TMVR. Therefore, it is important to verify MR jet duration with CWD and/or color M-mode.

3. Other Considerations in TMVR. Many of the current TMVR prostheses have structural elements that may project toward the interventricular septum and predispose to LVOT obstruction. The orientation of valvular elements relative to the septum should be carefully assessed and LVOT pressure gradients recorded from the transgastric approach during TEE. While the relationship between LVOT gradients and MR is uncertain, there is a theoretical possibility that interac-

tion of the valve with the septum may interfere with the stability of the implanted valve.

D. Percutaneous Mitral Annuloplasty

1. Percutaneous MV Annuloplasty Devices. Mitral annuloplasty is a critical component of most surgical MV repairs for both primary and secondary MR with annular dilatation. Accordingly, there is a significant interest in the development of percutaneous mitral annuloplasty. Indirect annuloplasty refers to the deployment of a device within the coronary sinus, taking advantage of the vicinity of the coronary sinus to the posterior and lateral aspects of the mitral annulus.^{116,117} None of the devices listed below are approved for clinical use in the US. The Carillon device (Cardiac Dimensions Inc., Kirkland, WA) is currently approved in Europe and works by pulling together the distal and proximal coronary sinus to reduce the mitral valve orifice area.^{118,119} The role of intra-procedural echocardiography is to evaluate MR severity before and after deployment, and to detect complications such as pericardial effusion (due to coronary sinus laceration or perforation) and LV lateral wall ischemia from acute compression of the left circumflex coronary artery. Direct annuloplasty consists of the re-shaping of the mitral annulus by cinching it through different mechanisms that approach the annulus itself rather than the coronary sinus. Mitralign (Mitralign Inc., Tewksbury, MA) consists of 2 pairs of pledgets deployed in the posterior annulus.¹²⁰ Each pledget of the pair is implanted by perforation of the annulus with radiofrequency wires from the LV to the LA. Cinching and locking the pledgets together reduces the annular dimension. As this procedure is performed in the P1 (lateral) and P3 (medial) segments, the antero-posterior dimension is reduced, therefore improving leaflet

coaptation. This procedure requires TEE guidance for precise positioning of the guiding catheters near the commissures and for subsequent safe crossing of the radio frequency wires into the LA. The Cardioband system (Edwards Lifesciences, Irvine, CA) uses TEE and fluoroscopic guidance to anchor a band directly to the annulus from the lateral to the medial trigones.^{121,122} The band is then adjusted in the beating heart to cinch the annulus until maximal MR reduction is obtained. 3D TEE has demonstrated acute reduction of annular dimensions with associated MR reduction.¹²³

2. Evaluation of MR after Percutaneous Annuloplasty. The evaluation of MR after any of the annuloplasty procedures is the least challenging of all MV percutaneous interventions, as the MV still consists of a single orifice, with an anatomy predictably similar to a native valve. Evaluation of MR severity should be performed according to the recent ASE recommendations for native MR.⁷ Importantly, all Doppler measurements pre-intervention can be compared after the procedure (CD, PWD, CWD) for a comprehensive assessment of changes in MR severity. If the anchors detach, the shape of the annulus may be altered, allowing for unusual MR jet location posterior to the annuloplasty device, possibly resulting in worse MR severity. In general, the expected result of all these annuloplasty procedures is that mitral annular dimensions and tenting area decrease, and coaptation length increases, resulting in a decrease in MR severity, and subsequently in LV dimensions and volumes over time.

E. Transcatheter Repair of Paravalvular Prosthetic MR

1. Repair of Paravalvular MR. TEE with 3D imaging and CD is the imaging technique of choice for the localization and anatomic analysis of prosthetic paravalvular MR and for guidance during the procedure (Figure 14). There is, however, an increasing interest in integrating and co-registering MDCT imaging with real-time fluoroscopy in the catheterization laboratory. The localization and image display of the PVR jets should be done to facilitate the communication between the echocardiographer and the interventionalist. The standard approach is to use the “surgeon’s view” from the LA, whereby the aortic valve is at the top (12 o’clock), the medial commissure/annulus is to the right (3 o’clock), and the lateral commissure/annulus and neighboring LA appendage are to the left (9 o’clock). Most para-prosthetic MR defects are in the anteromedial or posterolateral locations. Evaluation of the size and shape of the defect(s) is important for procedural planning. In the rare cases of PVR repair of TMVR, the skirts/flanges of the prosthesis pose challenges to transcatheter approaches of valve repair not encountered with surgical MV replacement; 3D TEE imaging is an essential component of pre-procedural planning and intra-procedural monitoring.

Knowledge of the 2D echocardiographic appearance of the expanded occluder device is important for proper positioning, stability, and potential for impacting prosthetic valve function and leaflet motion. 3D echocardiography of the MV from the LA provides excellent visualization of the occluder device, extent of overlap (if any), and the need for repositioning or deployment of additional occluders to successfully obliterate the defect. Assessment should be performed from both an LA and LV perspective. CD is used to identify and confirm defects and differentiate them from dropout or artifact secondary to acoustic shadowing from the mitral prosthesis. Doppler assessment of antegrade mitral flow and calculation of the mean mitral valve pressure gradient should be undertaken to screen for possible prosthetic valve obstruction. Occluder devices may also

interfere with the prosthetic valve leaflets during systole, preventing proper closure. This complication can be more difficult to recognize, and frequently the only sign is an abrupt increase in valvular regurgitation that is greater than the normal closing volume.¹²⁴ Other potential complications include device embolization, thrombus formation, and compromise of the circumflex coronary artery (typically with posterolateral defect targets) manifesting as a new lateral regional wall motion abnormality.

2. Evaluation of Residual MR after Repair of Paravalvular MR.

In assessing residual MR by TEE, a remaining defect versus an echo dropout around the occluder(s) should be confirmed by the presence of a PVR jet. Multiplane TEE imaging with CD (often with off-axis views) is used to visualize the PVR defect. CD is used to localize the PVR jet as well as assess its severity. Visualization of the post-repair residual PVR jet and its area in the receiving chamber can provide a rapid screening of the presence and direction of the jet and a semi-quantitative assessment of its severity (Figure 14). Larger jet areas represent more significant residual PVR. However, eccentric, wall-impinging jets appear smaller than centrally directed jets of similar hemodynamic severity, leading to underestimation of PVR by CD.

Key Points

TEE guidance of mitral valve interventions

- Most mitral valve interventions are designed to reduce MR severity, so comparison of baseline to peri-interventional measures are paramount.
- Each device has unique characteristics that require device-specific imaging protocols for successful and safe deployment, as well as for evaluating residual MR severity.
- Color Doppler is a convenient first-line method for detecting the presence of residual MR, determining the number, location, and direction of MR jets, and for estimating MR severity using jet characteristics of flow convergence, vena contracta, and jet area. However, determinations of severity of MR using color Doppler alone can be misleading, so integration with other parameters is necessary.
- A change in pattern from systolic flow reversal in more than one pulmonary vein to a normal pattern is strongly suggestive of mild residual MR.
- A change from an E-wave-dominant mitral inflow pattern to an A-wave-dominant pattern is consistent with mild residual MR.
- 3D TEE measurement of MR vena contracta area(s) may be useful in determining residual MR severity but requires further validation.
- Integration of echo/Doppler measures with invasive hemodynamics can help determine residual MR severity.
- In addition to assessment of residual MR severity, trans-mitral pressure gradient, mitral valve area, and potential LVOT obstruction should be evaluated.

F. Evaluation of Residual MR Outside the Catheterization Laboratory after all MV Procedures

Follow-up echocardiographic evaluation after MV interventions should be a comprehensive study that includes qualitative, semi-quantitative, and quantitative analysis when possible, using color

Table 6 Echocardiographic parameters and related comments in the assessment of MR severity with TTE after transcatheter MV interventions

Parameter	Assessing residual MR after MV interventions
Color Doppler	
Color Doppler MR jet(s)	<ul style="list-style-type: none"> • Multiple jets can lead to overestimation of MR severity • MV device artifacts/shadowing may mask MR jet (TTE) or flow convergence (TEE). • PVR often difficult to identify, localize and quantify by TTE; TEE often needed • Eccentric jets difficult to evaluate and harder to detect (out of imaging plane)
Flow convergence	<ul style="list-style-type: none"> • Small, suggests mild MR; large suggests significant MR
Vena contracta width	<ul style="list-style-type: none"> • Often better defined with TEE • Not validated for multiple jets or various interventions
Vena contracta area (3D)	<ul style="list-style-type: none"> • Better defined with TEE • May be useful after edge-to-edge repair; likely a preferred method for CD quantitation but limited studies available
Spectral Doppler	
CW Doppler of MR jet	<ul style="list-style-type: none"> • Parabolic contour and soft density suggest mild MR • Dense and triangular velocity waveform suggests significant MR
Pulmonary vein flow pattern	<ul style="list-style-type: none"> • Systolic flow reversal specific for severe MR • Flow pattern influenced by multiple factors: LA pressure, LV filling pressure, atrial fibrillation • Difficult to record with prosthetic mitral valves
Mitral inflow pattern	<ul style="list-style-type: none"> • Mitral E-wave dominance affected by multiple factors: increased MR severity, LV filling pressure, and relative MV obstruction from implanted MV devices • Mitral A-wave dominance suggests mild MR
Quantitative parameters	
EROA and RVol by PISA	<ul style="list-style-type: none"> • Not recommended in the presence of MV devices, including edge-to-edge repair (not validated for multiple jets, double orifice MV, or eccentric jets)
Volumetric RVol and RF	<ul style="list-style-type: none"> • Requires excellent LV endocardial definition to quantitate LV stroke volume; best used with 3D echo or contrast echo so as not to underestimate LV stroke volume and hence RVol/RF • Cannot use mitral annulus site for flow because of MV devices (except MV annuloplasty) • Multiple measurements may compound errors • Not accurate if >mild aortic regurgitation or VSD present

VSD, Ventricular septal defect.

Other abbreviations as stated earlier.

and spectral Doppler. Patients who have undergone a transcatheter MV intervention should typically receive TTE one day, 30 days, and 6-12 months after the procedure. Additional TTE studies should be performed sooner if clinically indicated. Echocardiograms on day 1 and 30 are primarily for assessing complications and acute results. The study at 6-12 months is performed to determine primary effectiveness of the device, including favorable reverse remodeling of the LV and LA (important indicators of MR reduction), and possible decrease in elevated pulmonary artery pressure. The post-procedure TTE is more informative if comprehensive echocardiograms are performed before, during, and immediately after the procedure and are available for comparison. At the time of the follow-up TTE, it is important to document any changes in medical therapy or clinical condition, measure blood pressure and heart rate, and assess cardiac rhythm to determine if the pre- and post-procedure studies are performed under similar clinical and hemodynamic conditions. Following reduction of MR, the precise timing of LV reverse remodeling is unclear, but it appears that at 6 months, assessment with TTE is reasonable to determine if there has been a reduction in LV size; changes in LA size are less prominent.^{125,126}

More data is available regarding MR assessment after edge-to-edge repair than for the other MV procedures. With little information on the assessment of MR severity after TMVR, most investigators have assumed that evaluation of residual MR should be similar to that

used for surgical mitral prostheses.⁶ There is little data validating MR assessment after any of the annuloplasty procedures. However, since these procedures result in a valve similar to a native MV with a surgical ring annuloplasty, assessment of residual MR would be similar to native MR.⁷ Lastly, evaluation of residual MR after PVR closure has similar complexities and limitations as after TMVR because of the presence of the prosthetic MV and shadowing of the Doppler signal. Defining PVR often requires TEE, especially if the regurgitant orifice is small or eccentric. Thus, if there is clinical suspicion of PVR because of a systolic murmur, hemolysis, or congestive heart failure, a TEE, preferably with 3D capability, should be performed.

The following details all echocardiographic parameters used in the evaluation of residual MR severity after MV interventions, along with pertinent issues with the TTE approach (Table 6). Table 7 summarizes all Doppler and echocardiographic parameters used in assessing severity of residual MR with either TTE or TEE, as these approaches are complementary in evaluating post-procedural MR.

1. Color Doppler Imaging. General consideration: CD is essential in detecting residual MR after MV interventions and identifying several characteristics of the regurgitation (number of jets, site, direction, eccentricity). It is important to identify the three components of the MR jet (flow convergence, vena contracta, and jet area in the LA), using traditional parasternal long-axis, apical, and off-angle views;

Table 7 Echocardiographic and Doppler parameters for grading MR severity by TEE or TTE after transcatheter MV interventions*

Parameter	Mild	Moderate	Severe
Structural			
Morphology	Device appropriately positioned/expected or normal valve motion	No specific criteria	Abnormal device position/flail valve (single leaflet detachment, dehiscence, incomplete TMVR expansion etc.)
LA and LV volumes	Reduction in size from baseline or normalization	Minimal change	Enlarged with no change/worsening from baseline, particularly in primary MR
Qualitative			
Color Doppler jet (size, number, eccentricity)	One or two small, narrow jets	More than mild but does not meet severe criteria	Large central jet/multiple jets/eccentric jet(s) of any size wrapping around LA
Flow convergence size [†]	None or small	Intermediate	Large
Mitral inflow pattern	A-wave dominant	No specific criteria	No specific criteria
Pulmonary vein flow pattern [‡]	Normal	Blunted systolic flow	Systolic flow reversal
CW Doppler of MR jet (density, contour)	Faint, parabolic contour	No specific criteria	Dense, triangular contour
Semi-quantitative			
Vena contracta width (cm)	Single jet with VCW ≤ 0.3	Single jet with VCW 0.4-0.6	Any jet with VCW ≥ 0.7 or ≥ 2 moderate jets
Quantitative			
Vena contracta area by 3D planimetry (cm ²) [§]	Single jet with VCA < 0.2	Single jet with VCA 0.2-0.39	Any jet with VCA ≥ 0.4 or ≥ 2 moderate jets
EROA by PISA (cm ²)	< 0.2 Not recommended after edge-to-edge repair or in PVR	0.2-0.39 Not recommended after edge-to-edge repair or in PVR	≥ 0.4 Not recommended after edge-to-edge repair or in PVR
Regurgitant volume (mL)	< 30	30-59	≥ 60 (May be lower in low flow states)
Regurgitant fraction (%)	$< 30\%$	30-49	$\geq 50\%$

CW, continuous-wave; EROA, effective regurgitant orifice area; LA, left atrium; LV, left ventricle; MR, mitral regurgitation; PISA, proximal isovelocity surface area; PVR, paravalvular regurgitation; TMVR, transcatheter mitral valve replacement; VCA, vena contracta area; VCW, vena contracta width.

*All parameters have limitations and an integrated approach must be used that weighs the strength of each echocardiographic measurement. All signs and measures should be interpreted in an individualized manner that accounts for body size, hemodynamics, and other patient characteristics.

[†]Flow convergence is usually small with a PISA radius ≤ 0.3 cm and large with a radius ≥ 1 cm at a Nyquist limit 25-40 cm/s.

[‡]Influenced by many other factors (LV diastolic function, atrial fibrillation, LA pressure).

[§]by Color Doppler; further validation is needed.

^{||}Total stroke volume (inclusive of the RVol) is calculated from LV volumes. Use of 3D echocardiography and preferably contrast echocardiography is recommended to avoid underestimation of LV volumes, RVol, and RF.

parasternal short-axis views at the level of the valve may identify the number of residual jets. Despite all these manipulations, the 3 components may not be seen in the same plane. It is also important to acknowledge three areas of challenge for CD in assessing MR severity after MV interventions:

- 1) There is frequently more than one MR jet;
- 2) MR jets are often eccentric and wall-hugging, and may crisscross;
- 3) A variable degree of shadowing of MR jets occurs, depending on the procedure/MV structure, is worse in the presence of a prosthetic MV (e.g., TMVR and repair of PVR), and occurs to the least extent with MV annuloplasty.

Nonetheless, CD is useful as a first-line approach to identify and localize the site or origin of MR jet(s). In general, small thin jets with

no or little flow convergence denote mild MR (Figure 15); large jets or eccentric jets that track along the LA wall to the pulmonary veins with a large VC or proximal flow convergence are typically severe. CD should always be coupled with other supportive PWD and CWD parameters of MR, using an integrative approach, particularly when limitations with CD are suspected (Figure 16).⁷ If there is suspicion for significant residual MR, further evaluation is needed with other parameters and/or TEE with 3D capabilities. The utility of 3D CD to assess MR severity has been reported but is not yet fully validated.⁹⁹

Vena contracta: There is a paucity of data on vena contracta width and area in evaluating severity of residual MR after MV interventions. VCW is generally not recommended unless limited to a single jet

Mild MR after Edge-to-Edge MV Repair

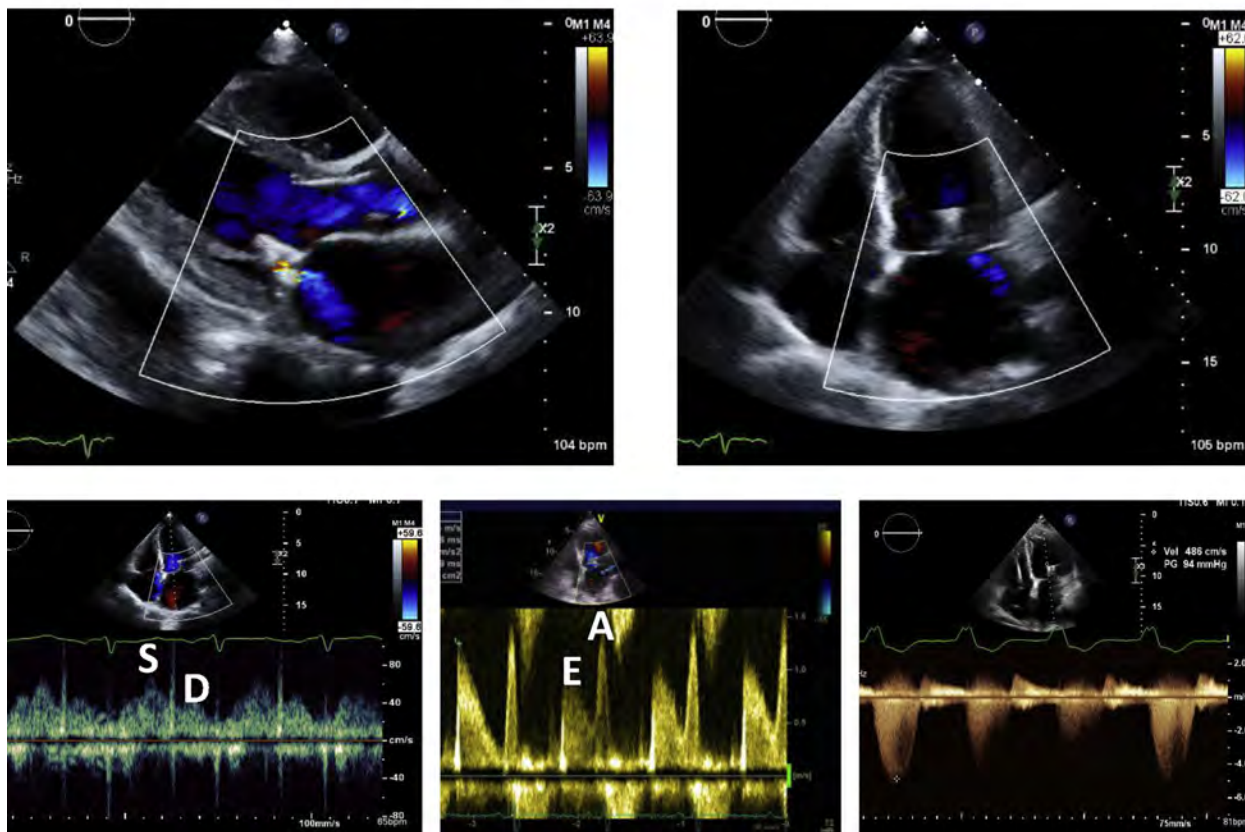


Figure 15 Echocardiographic features of mild residual MR after edge-to-edge mitral valve repair. The MR jet is narrow, small, and of low velocity (minimal aliasing), with a small VC and no flow convergence. Pulmonary venous flow shows normal systolic dominance. There is A-wave dominance of mitral inflow and the CWD recording of the MR jet has a faint spectral display with a parabolic profile.

within the native valve after annuloplasty, provided that the origin of the MR jet is well identified in a zoomed view and preferably in an imaging plane in the axial resolution of ultrasound, thus optimizing resultant measurement accuracy.⁶ There is controversy as to whether to add VCW of multiple jets, or ignore the very small ones (VCW ≤ 2 mm). MR is severe in the presence of a single jet with a VCW ≥ 0.7 cm, as well as two or more moderate (VCW 0.4-0.6 cm) jets.

3D TEE allows measurement of VCA, although data with this parameter is still scant. Altiok *et al.*⁹⁹ measured VCA with 3D TEE after MitraClip placement and found that patients with improved NYHA functional class at 6 months had a greater reduction in VCA when compared to patients without improvement. Moreover, they found that the reduction in LA and LV volumes were significantly greater in patients who had more than a 50% reduction in VCA after repair. 3D TEE has the unique advantage of allowing for the analysis of MR severity from each orifice of the double-orifice mitral valve after edge-to-edge repair. There is less experience with VCA in other residual MR conditions, but it is expected that such measurements would also be applicable, given good quality of the acquired data. The proposed thresholds for MR severity using VCA are detailed in [Table 7](#); with increasing experience in mitral interventions and 3D TEE, further validation and refinement will be forthcoming.

Flow convergence: PISA has been traditionally used to assess the severity of native or prosthetic MR in conjunction with TTE and

TEE. These same parameters should in principle also apply to other MV procedures. For central jets and at a Nyquist limit of 30-40 cm/s, mild MR is associated with a minimal flow-convergence radius of ≤ 0.3 cm, and severe MR is characterized by a large flow-convergence radius of ≥ 1 cm. After edge-to-edge device implantation, flow convergence can be used qualitatively, however PISA is unsuitable for MR quantification due to multiple MR jets or because the clip may obscure the flow-convergence zone or truncate it, making angle correction necessary and difficult. Similar limitations may be present with the other prosthetic MV repair devices/replacement, and there are little data on these newer devices.

2. CW Doppler of MR Jet. Density of the spectral display of the MR jet relates to the severity of MR. A soft parabolic MR waveform is consistent with mild MR ([Figure 15](#)). However, a dense velocity waveform is associated with greater severity, but cannot differentiate moderate from severe MR ([Figure 16](#)). An early peaking, triangular waveform contour denotes a large regurgitant pressure wave in the LA and significant MR. If early-peaking of the MR jet is present prior to the procedure, the contour of the MR velocity waveform changes from early-peaking to parabolic, with reduction in MR severity. Occasionally a bimodal, early and late systolic flow pattern of MR is seen. When severe MR persists after the procedure, the MR CWD signal is holosystolic, dense, with similar density to the mitral inflow Doppler signal.

≥ Moderate MR after Edge-to-Edge MV Repair

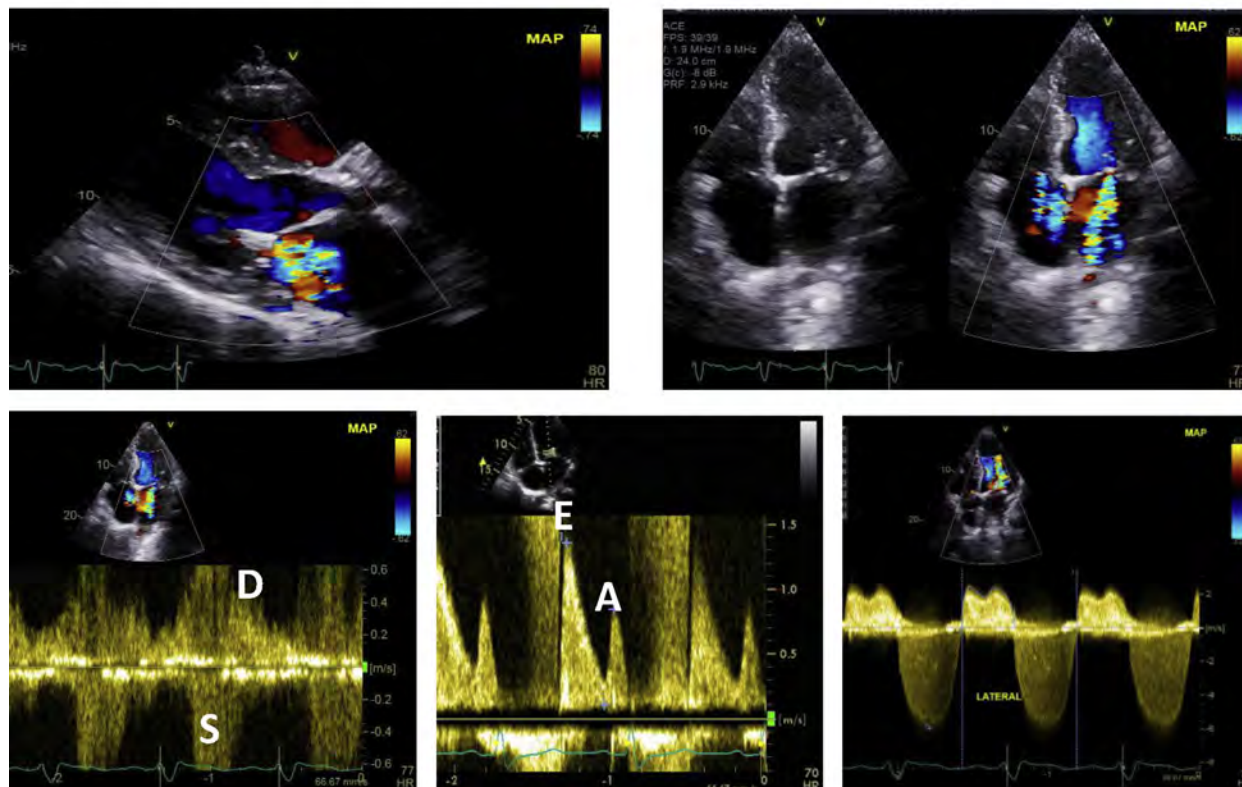


Figure 16 An example of significant residual MR after edge-to-edge mitral valve repair. The severity from the above views is likely moderate but would need to be substantiated further with either quantitative LV volumes/Doppler (see example in [Figure 17](#)), TEE or CMR. The color Doppler jet is aliased and large in the left atrium; however, flow convergence is not prominent. There is aliased systolic flow reversal in the pulmonary vein but this may be contaminated with the MR jet being directed into the interrogated pulmonary vein. Mitral E wave-dominance is sensitive but not specific for significant MR as it is load dependent and also related to the residual valve area after repair. The CWD velocity waveform is of moderate density and still parabolic.

3. Mitral Inflow Pattern and Pressure Gradient. After edge-to-edge MV repair, TMVR, annuloplasty ring insertion, or catheter-based plugging of paravalvular leaks, the mitral inflow velocity pattern is assessed using CWD to determine the peak mitral E velocity, its deceleration rate, and the mean mitral pressure gradient. The heart rate should be noted. Anatomic assessment of mitral valve openings after edge-to-edge repair or residual paravalvular leaks is best assessed with 3D TEE.¹²⁴ After edge-to-edge repair, a mean mitral valve gradient of <5 mm Hg at a normal heart rate is considered acceptable. An elevated pressure gradient in the presence of a large valve opening may be an important clue to the presence of significant MR. A change from an E-wave-dominant mitral inflow pattern at baseline to an A-wave-dominant pattern after the intervention is indicative of significant reduction in MR and non-severe residual MR, provided the patient is in sinus rhythm. In contrast, a mitral E-dominant inflow pattern is not diagnostic of significant MR, as it is influenced by many factors, including the new relative valve stenosis after the MV intervention, and LV filling pressures ([Figures 15 and 16](#)). On the other hand, an increase in mitral E velocity and velocity-time integral with a decrease in LVOT velocity over time may indicate worsening severity of MR.

4. Pulmonary Vein Flow Pattern. Pulmonary venous flow velocities can be a useful indicator of LA pressure and MR severity. Improvement in or normalization of systolic pulmonary vein flow

strongly suggests that MR has been reduced ([Figures 11 and 14](#)). Diastolic dominance may persist if MR is still significant, or in the presence of elevated LV diastolic pressure or atrial fibrillation.¹²⁷ With worsening of MR, pulmonary vein systolic flow reversal may develop.

5. Pulmonary Artery Systolic Pressure. Pulmonary artery systolic pressure (PASP) is an adjunctive measurement because it may be normal or elevated at rest in patients with moderate-to-severe MR; elevated PASP may also be due to intrinsic pulmonary vascular disease rather than MR. In one study, the PASP fell from 36 ± 4 to 29 ± 7 mm Hg after MitraClip placement.¹²⁸ The fall in PASP was primarily seen in patients with elevated values at baseline.¹²³

6. Regurgitant Volume and Fraction. Evaluation of RVol and RF by volumetric echo/Doppler is a useful method to assess MR post-intervention. This is feasible unless more than mild AR or a significant ventricular septal defect is present. Because MV anatomy is usually abnormal after MV percutaneous interventions (edge-to-edge repair, prosthetic valve), determination of stroke volume with PWD at the MV annulus is not feasible. Thus, total LV stroke volume is determined from the difference between LV end-diastolic and end-systolic volumes from TTE apical images. It is preferable to use 3D or contrast echo so as not to underestimate LV volumes and thus stroke volume

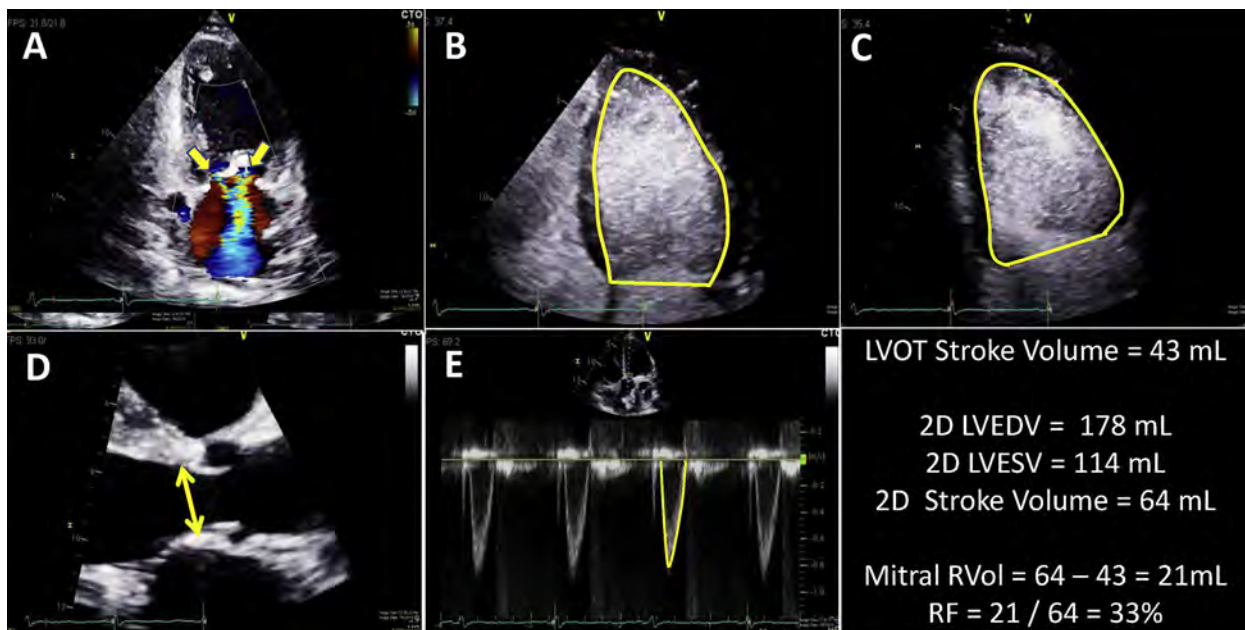


Figure 17 Quantification of mitral regurgitation using a combination of total LV stroke volume (from contrast-enhanced bi-plane LV volume measurements) and LVOT stroke volume (from diameter and velocity measurements). (A) Apical two-chamber view shows two jets of MR and the MitraClip; (B) Apical four-chamber contrast-enhanced image; (C) Apical two-chamber contrast-enhanced image; (D) LVOT diameter measurement, (E) LVOT pulsed-wave Doppler velocity waveform.

and RVol (Figure 17).⁶ Systemic stroke volume is most often estimated with PWD at the LVOT.⁶ Foster *et al.*¹²⁷ analyzed the RVol and RF before and after MitraClip placement and demonstrated that RVol fell from 50.3 ± 21.5 mL at baseline to 27.5 ± 18.6 mL ($P < .0001$). RF also fell from 44.6 ± 13.6 % to 28.9 ± 15.3 % ($P < .0001$) at 6 months. Hamilton-Craig *et al.*¹²⁹ compared Doppler echocardiography and CMR grading of MR severity in patients after MitraClip placement. RF by Doppler quantification exhibited significantly better reproducibility than expert readers' subjective assessment. CMR quantitation demonstrated excellent reproducibility. Altiok *et al.*⁹⁹ showed that during TEE, 3D quantitation of mitral RVol before and after MitraClip placement have lower intra- and inter-observer variability as compared to 2D techniques.

Lastly, the ratio of velocity-time integral of mitral inflow to LV outflow (VTI_{MV}/VTI_{LVOT}) has been used in prosthetic mitral valves to assess function of the prosthesis and detect MR.⁶ An elevated VTI_{MV}/VTI_{LVOT} ratio (>2.2 in mechanical bileaflet valves; > 2.3 in bioprosthetic pericardial; > 2.6 in porcine valves) suggests significant MR in the presence of a normal pressure half-time.^{6,130} Conceptually, this ratio could be used after TMVR and catheter-based plugging of PVR of prosthetic mitral valves. However, a cut-off value has not been validated for TMVR and requires further study.

7. An Integrative Approach to Assessing Residual MR. Similar to all valvular regurgitation, an integrative approach is needed in the overall evaluation of residual MR after interventions on the MV. Table 7 lists the various parameters that may be helpful in this evaluation and Figure 18 provides an algorithm using these parameters to help facilitate the overall assessment of residual MR. These suggestions are based on clinical expert opinion, available data, and a consensus of the Writing Group members. All patients should have blood pressure, heart rhythm and rate, and medications (e.g., pressors, inotropes, vasodilators) recorded at the time of study, as these may influence MR severity. These parameters are predominantly based on recent guidelines pertaining

to native valve regurgitation⁷ but with several modifications. These recommendations have not been extensively validated and further studies are needed to test and refine these criteria singularly and in combination.

As stated, MR grading may be difficult due to the complexity of its mechanisms after MV repair or replacement, the frequent multiple eccentric jets of variable size, shadowing from devices, mitral annular calcium, or the hemodynamic conditions that may affect some of these parameters. For these reasons and because of the errors involved in quantitation, a three-grade system is proposed (mild, moderate, and severe). Nevertheless, if the preponderance of the data favors mild or severe regurgitation, the assessment is most likely accurate and further quantitation may not be needed, at least for the mild lesions. However, if the data are of suboptimal quality and possibly conflicting, quantitation is advised; if not possible, additional evaluation with TEE or CMR should be undertaken.

8. Role of CMR in the Evaluation of Residual MR after Percutaneous MV Interventions. CMR has a role in the evaluation and quantitation of residual or paravalvular MR after MV interventions. However, since there are currently no published data on the use of CMR in this clinical setting, potential approaches for quantification are extrapolated from the literature of native MR or surgical prosthesis.^{131,132} Furthermore, it is essential to first ensure that the implanted device is CMR-safe prior to performing the study.

a. Evaluation of Residual MR.—Qualitative assessment of regurgitation based on SSFP cine images may not be reliable in the presence of implanted valves, clips, or annuloplasty rings due to susceptibility artifacts from the valve frame, ring, or clip itself (Figure 19). In addition, the atypical regurgitant patterns due to valve flange/skirt from TMVR may make visual assessment of regurgitation challenging. The use of phase-contrast imaging with through-plane phase-encoding may provide better visual assessment of the regurgitation as opposed to SSFP cine images; this however remains to be studied.

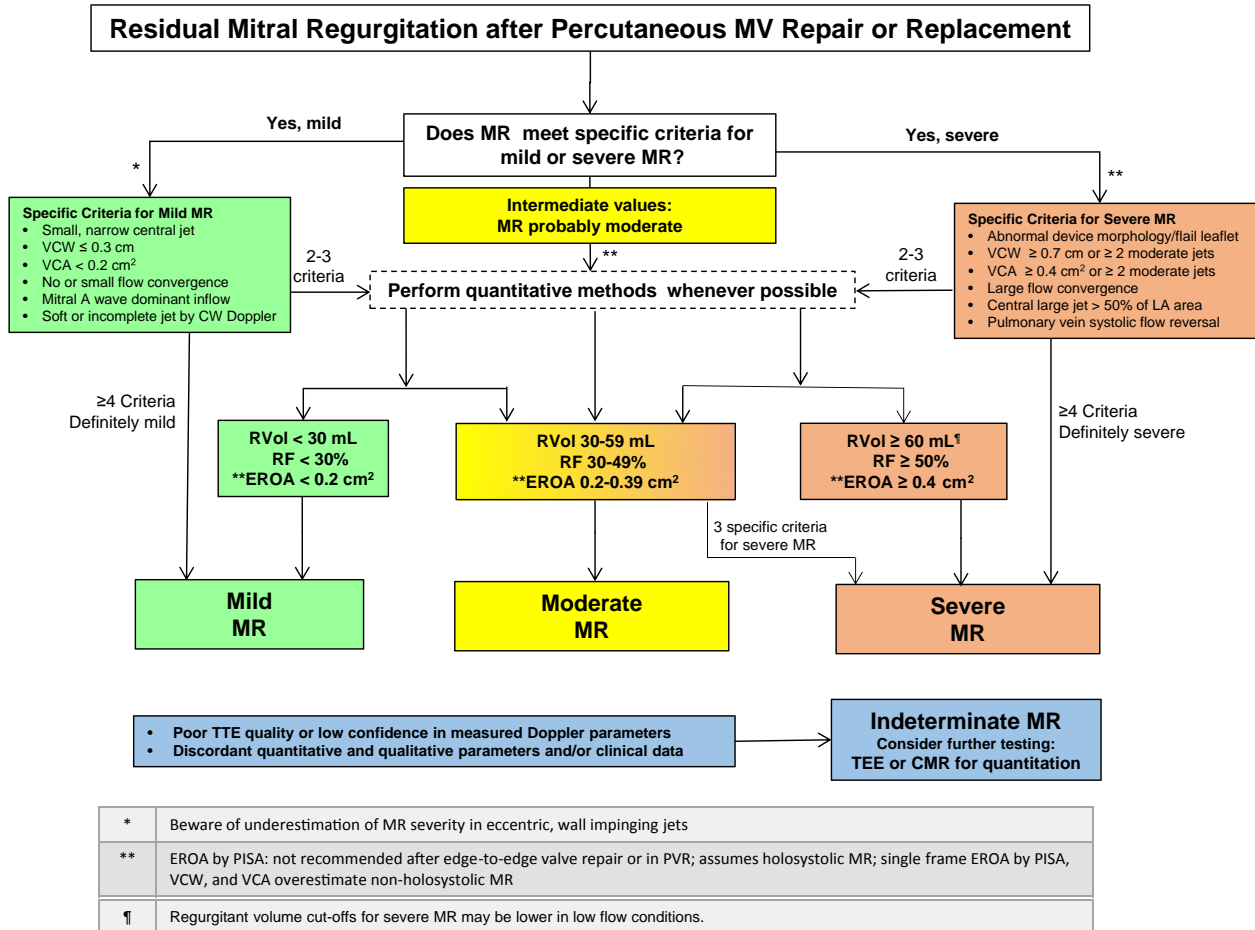


Figure 18 Suggested algorithm to guide implementation of integration of multiple parameters of MR severity after mitral valve percutaneous interventions. Good-quality echocardiographic imaging and complete data acquisition are assumed. If imaging is technically difficult, consider TEE or CMR. MR severity may be indeterminate due to poor image quality, technical issues with data, internal inconsistency among echo findings, or discordance with clinical findings.

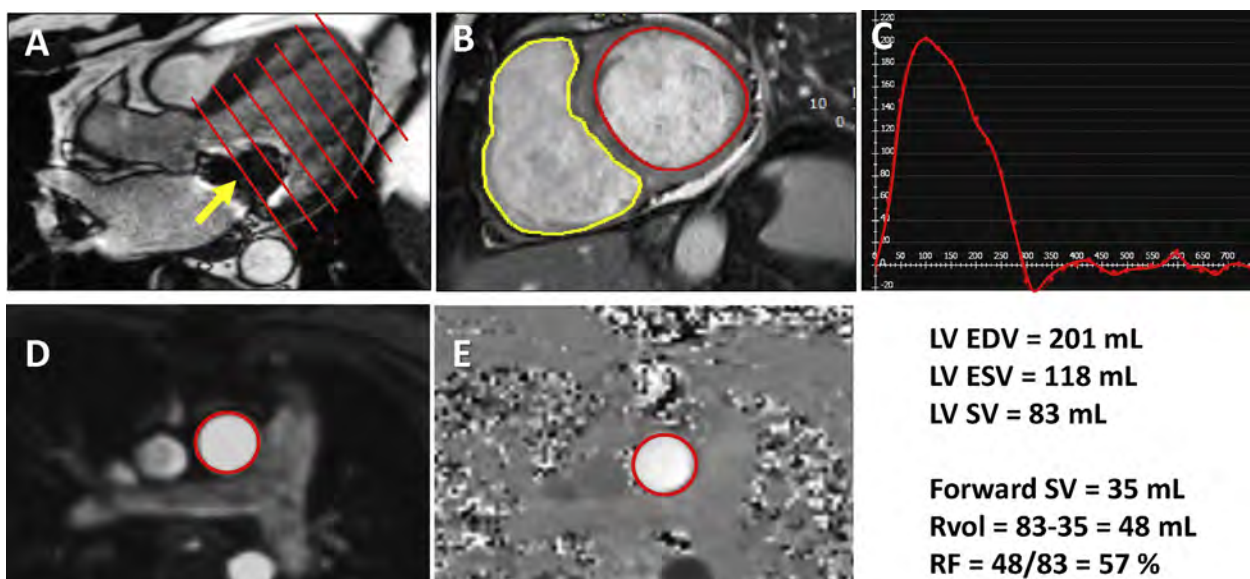


Figure 19 Quantitation of mitral regurgitant volume and regurgitant fraction with CMR in a patient after edge-to-edge mitral valve repair. The “indirect” method is used: total LV stroke volume is calculated from LV end-diastolic volume (LVEDV) and end-systolic volume (LVESV) using a short axis stack of the LV (A and B). The susceptibility artifact from the MitraClip is shown by the arrow in panel A. Forward stroke volume is derived from phase-contrast flow through the aortic valve (C: flow curve; D and E depict in red the regions of anatomic and phase-contrast flow in the aorta, respectively).

Quantitative assessment of residual mitral RVol and RF¹³³⁻¹⁴¹ may be useful in the context of percutaneous MV interventions.¹²⁹ Available CMR techniques can be divided into direct and indirect methods, which have been discussed in detail.⁷ The direct method uses short-axis phase-contrast imaging with through-plane velocity encoding to measure RVol directly.¹³³ The use of this direct technique is less feasible in the case of percutaneous annuloplasty ring implantation and edge-to-edge repair,¹²⁹ and is limited in the setting of TMVR or post-paravalvular leak closure due to significant susceptibility artifacts. Indirect techniques are likely more appropriate for the quantification of MR. This includes calculation of RVol using: (1) the difference between LV stroke volume using planimetry of short-axis cine images and aortic stroke volume obtained by phase-contrast images (Figure 19)¹³⁵⁻¹³⁷; and (2) the difference in left and right ventricular stroke volumes by endocardial contouring of left and right ventricular cine images.^{133,138-140} The regurgitant fraction can be calculated by dividing the RVol by the LV stroke volume. Careful attention to the basal LV slice is important in calculating LV volumes as this slice is most likely to be affected by susceptibility artifact from the implanted device (Figure 19). If susceptibility artifact significantly affects the delineation of endocardial borders, then LV volume, RVol, and RF measurements will be less reliable, and this should be stated in the report.

Currently there are no published data validating partition values of RVol or RF by CMR to classify patients into degrees of MR severity in the context of percutaneous MV intervention. Previous data suggested grading MR using the following RF values: Mild $\leq 15\%$, moderate 16-25%, moderate-to-severe 26-48%, and severe $>48\%$;⁹⁵ clinical outcome was differentiated at a cut-off of 40%.¹⁴² More recently, the partition values used with echocardiography were suggested as appropriate thresholds with CMR to grade MR severity.^{7,143} It is the consensus of the Writing Group that these partitions for MR severity also be used for both echocardiography and CMR after percutaneous MV interventions, until further data are available specific to the population of percutaneous MV interventions (Table 7).

b. LV and LA Reverse Remodeling.—CMR can also have a role in assessing reverse remodeling of the LV or LA after percutaneous MV interventions.^{144,145} LV volumes and function are measured using a stack of SSFP short-axis cine images based on existing recommendations.^{146,147} As stated earlier, careful attention to the basal slice is important as it is the most affected by susceptibility artifact, which would affect measurements of LV volumes and LVEF. All measurements should be indexed to body surface area.^{143,148-151} Similarly, accurate measurement of LA volumes would require acquisition of multiple cine planes through the LA, allowing quantification without geometrical assumptions.¹⁵² Since this will require additional dedicated imaging and analysis, it can be time intensive. Left atrial area and dimension based on standard two- and four-chamber cine images indexed to body surface area can also be used to assess atrial remodeling.^{151,152}

c. When is CMR Indicated?.—The primary indication for CMR in the assessment of residual MR or paravalvular MR after percutaneous MV intervention is when Doppler echocardiographic assessment is unsatisfactory or inconsistent with the clinical findings. Another potential role of CMR is in determining the physiologic consequences of MR on the LV and LA, with more accurate and reproducible measurements of volumes and ejection fraction. The major limitations in using CMR for regurgitation quantification include: 1) CMR compatibility of the implanted device, 2) susceptibility artifacts, 3) underlying arrhythmia in patients undergoing these procedures and, 4) lack of validated partition values specific for CMR to grade severity of the regurgitation. It is

important to note that while the use of gadolinium contrast is contraindicated in patients with significant renal dysfunction, quantitation of valve regurgitation can still be performed in these patients as phase-contrast and SSFP cine images do not need contrast administration.

Key Points

Assessment of residual MR after percutaneous MV interventions

- Imaging after MV interventions includes careful evaluation of device integrity, position, stability, and interaction with adjacent structures.
- Color Doppler is the first-line method to assess residual MR with TTE. It is reliable for excluding or detecting mild MR. For more severe lesions, color Doppler assessment of MR severity with TTE is challenging due to interaction of the device or adjacent structures with the MR jets, and the frequent presence of multiple MR jets, often crisscrossing and in different planes.
- Evaluation of residual MR requires careful integration of multiple parameters, as no single parameter is sufficiently accurate to assess MR severity. These parameters include assessment of color Doppler components of MR jets (flow convergence, VC, jet area and direction), regurgitant volume by volumetric methods, mitral inflow pattern, pulmonary vein flow pattern, CWD jet density and contour, and forward stroke volume [LVOT or right ventricular outflow tract (RVOT)]. The PISA method for MR quantitation is not advised after edge-to-edge MV repair or in paravalvular regurgitation.
- It is important to compare post-procedural parameters to pre-procedural baseline images, which can help evaluate the change in MR severity and reverse remodeling of the LV or LA.
- When more than mild MR is suspected, but the data are uncertain, this should be communicated so that further imaging with either TEE or CMR is performed.
- CMR offers the advantage of quantitation of mitral regurgitant volume and fraction, comparing total LV stroke volume to systemic stroke volume in the aorta by phase contrast or derived from the right heart. Depending on the MV device, a variable amount of artifact around the device is seen.

V. PERCUTANEOUS PULMONARY VALVE REPLACEMENT

Initial repair of tetralogy of Fallot often involves surgical disruption of the pulmonary valve with resultant pulmonary regurgitation (PR). In addition to patients with tetralogy, several other forms of congenital heart disease require placement of a right ventricle-to-pulmonary artery (RV-PA) conduit to establish reliable pulmonary blood flow, such as truncus arteriosus, pulmonary atresia with ventricular septal defect, and some forms of double-outlet right ventricle (RV). Over time, dysfunction of the native RVOT or RV-PA conduit leads to varying degrees of stenosis and regurgitation. Progressive pulmonary insufficiency with resultant RV dilation and dysfunction has been shown to lead to decreased exercise tolerance, increased arrhythmia burden, and sudden cardiac death.^{153,154} In these patients, specific criteria for re-intervention are used to guide placement of a competent pulmonary valve including moderate to severe pulmonary valve/RV-PA

conduit regurgitation in combination with clinical symptoms, severe RV dilatation, and depressed RV function.¹⁵⁵⁻¹⁶⁰ Traditionally, surgical pulmonary valve replacement was undertaken, but over the last 15 years, transcatheter techniques for pulmonary valve replacement have become widely available.

The Melody valve (Medtronic Inc., Minneapolis, MN) and the Edwards SAPIEN XT valve (Edwards Lifesciences, Irvine, CA) are the only FDA-approved valves for transcatheter pulmonary valve replacement (TPVR) in the United States.¹⁶¹⁻¹⁶³ To date, more than 6000 patients worldwide have received TPVR for a variety of underlying congenital heart abnormalities.¹⁶⁴ Currently, TPVR is only USFDA-approved for placement of a competent valve within an RV-PA conduit, although trials are now underway assessing devices designed for native outflow tracts in these patients.^{165,166} As an adjunct to this therapy, some centers also perform bare-metal stenting of a native outflow tract to serve as a conduit, and then implant a transcatheter pulmonary valve within the stent.¹⁶⁷

A. Description of TPVR and Assessment of Acute Results

Prior to implantation, CMR or MDCT imaging allows 3D multiplanar reconstruction and provides accurate delineation of anatomy, size, and geometry of the RVOT and pulmonary arteries (with or without an existing RV-PA conduit or bioprosthetic valve).¹⁶⁸ This information is crucial in pre-procedural assessment for TPVR, as certain anatomic criteria must be met before valve implantation.^{162,163,169} Ensuring that the outflow tract/conduit is of an appropriate size to accept a TPVR valve (not too small or too large) and that there is an appropriate "landing zone" to seat the valve are both critical. Delineation of the coronary artery course is also essential prior to any RVOT intervention, as a subset of these patients have a coronary branch crossing the RVOT, which may complicate the interventions.¹⁷⁰⁻¹⁷³ Additionally, for some patients the left anterior descending coronary artery and conal branches arise normally, but lie directly posterior/inferior to the RVOT in the area of proposed valve deployment. In these cases, coronary compression from valve expansion is a rare but potentially catastrophic complication.

TPVR is performed via femoral or jugular venous access. The currently available valve platforms require large delivery systems (up to 22 French in size), which are relatively rigid, making navigation through the right-sided heart chambers occasionally challenging, particularly in smaller children. Presently, there are two available platforms that can be used for TPVR in the United States. In addition to the Melody valve, the Edwards SAPIEN valve has been successfully used in the pulmonary position during the multicenter COMPASSION trial,¹⁷⁴ and also received FDA approval. As opposed to aortic and mitral valve interventions, TPVR is primarily guided by fluoroscopy rather than echocardiographic imaging. Due to the anterior location of the pulmonary valve, both TEE and TTE guidance have proven less helpful than in TAVR. Recently, rotational angiography with acquisition of MDCT-like 3D volume imaging or fusion with pre-existing MDCT images is gaining popularity for intra-procedure guidance and may improve accuracy in sizing and positioning. Acute valve performance is primarily evaluated by catheter-measured pressure gradients and pulmonary angiography, although some operators use intracardiac echocardiography as well.^{175,176}

B. Evaluation of Residual Regurgitation Outside the Catheterization Laboratory

To date, TPVR has proven to be very successful at reducing PR acutely and over the medium term. In the most recent update for the US

Melody Valve Investigational Device Exemption Trial, among the 113 patients who were alive and free from re-intervention at medium-term follow up (average 4.5 years), 97 had no or minimal PR, 15 had mild, and only 1 had moderate PR.¹⁶¹

1. Assessment of Pulmonary Regurgitation after TPVR with Echocardiography.

Compared to the evaluation of percutaneous aortic and MV interventions, there is a paucity of consensus and recommendations regarding the echocardiographic evaluation of patients after TPVR.¹²⁶ Evaluation of PR by TTE most commonly utilizes a combination of techniques, including color and spectral Doppler interrogation of the RVOT/conduit and the main and branch pulmonary arteries, extrapolating traditional assessment of PR in native valves.^{7,177} In the US Melody Valve Investigational Device Exemption Trial,¹⁷⁸ PR was graded via a composite scale based on the width of the regurgitant jet by CD in relation to either the conduit or pulmonary annulus diameter (Figure 20) as well as the extent of diastolic flow reversal in the pulmonary artery (Table 8). For this trial, both pre- and post-TPVR studies were assigned a PR value corresponding with the greater value between PR jet width and extent of diastolic flow reversal. This technique, however, yielded only modest correlation with CMR-derived pulmonary RF,¹⁷⁸ suggesting that TTE evaluation of PR in this patient population remains challenging. It is important to note that in severe PR with normal pulmonary artery pressures, the color jet can be difficult to detect as the PR jet velocities are low and brief in duration due to rapid equalization of pulmonary and RV diastolic pressures. Though not validated in patients who have undergone TPVR, additional Doppler indices have been reported for assessment of severity of PR. Rapid deceleration of the PR CW Doppler velocity waveform with a pressure half-time of <100 ms has been shown to have good sensitivity and specificity for predicting severe PR (Figure 20).^{179,180} Pressure half-time, however, is also influenced by the diastolic pressures in both the pulmonary arteries and the RV, such that a non-compliant RV with restrictive physiology will demonstrate a shorter pressure half-time. Similarly, a period of time in late diastole with no regurgitation indicates rapid equilibration of the RV and PA diastolic pressures, and in cases with severe PR and poor RV compliance, there may in fact be antegrade flow in late diastole into the main PA.¹⁸¹ The density of the CWD signal relates to severity of regurgitation but does not differentiate moderate from severe PR (Figure 20). Finally, flow convergence quantitative methods such as PISA, though theoretically applicable to pulmonary valve assessment, are difficult to record in the presence of prosthetic material and have not been validated for either native or transcatheter pulmonary valves to date.¹⁸² However, flow convergence can be used qualitatively in the evaluation of PR (Figure 20). The use of TEE in TPVR patients is not widely employed to assess severity of PR, as visualization of the RVOT and pulmonary valve replacement is limited.

2. Role of Computed Tomography in Pulmonic Regurgitation after TPVR.

MDCT offers excellent spatial resolution and rapid acquisition times. However, the lack of flow data limits its utility in assessing patients who have undergone TPVR for residual valve regurgitation. MDCT can provide excellent assessment for stent fracture as well as delineation of the valve orientation and eccentricity index, which may be helpful in predicting valve dysfunction (Figure 21) since stent and valve distortion have been shown to impact valve function.¹⁸³⁻¹⁸⁵ These factors may be important in TPVR, particularly in patients with post-operative pectus deformities, as the

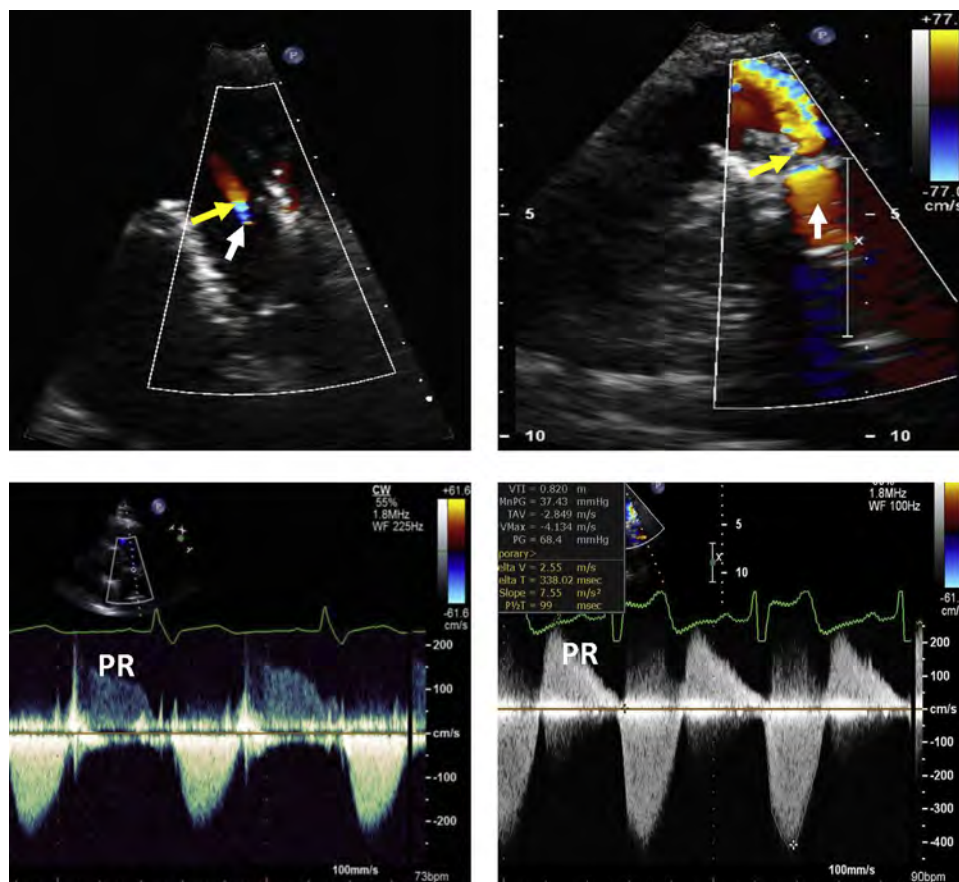


Figure 20 Examples of patients with mild (left panels) and severe (right panels) pulmonary regurgitation (PR) after TPVR are shown. The width of the color jet is depicted by the *yellow arrows*. Note also the difference in flow convergence (*white arrows*). Lower panels show examples of CWD recordings of mild and severe PR. The density of the spectral Doppler waveform (faint versus dense, particularly in relation to systolic flow) and the slope of the decrease in velocity in diastole (long vs. short pressure half-time) are apparent.

Table 8 Echocardiographic and Doppler parameters useful in grading pulmonary regurgitation severity after TPVR

Parameter	Mild	Moderate	Severe
Jet width in relation to pulmonary annulus or conduit (CD)*	<20%	20-40%	>40%
Site of diastolic flow reversal in PA/conduit (PWD)	Proximal half of the main PA/conduit	Distal main PA/conduit	Extends into PA branches
PR velocity waveform density and contour (CWD)	Soft	Dense; early termination of diastolic flow possible (depending on RV compliance)	Dense; early termination of diastolic flow
PR pressure half-time (CWD)			<100 ms [†]
Regurgitant fraction [‡]	<20%	20-40%	>40%

CD, Color Doppler; CWD, continuous-wave Doppler; PA, pulmonary artery; PR, pulmonary regurgitation; PWD, pulsed wave Doppler; RV, right ventricle.

*At a Nyquist limit of 50-60 cm/s.

[†]Not reliable in the presence of high RV end-diastolic pressure.

[‡]Regurgitant fraction data primarily derived from CMR with limited application with echocardiography.

position of the RVOT often lies directly posterior to the sternum. Additionally, with retrospective electrocardiographic gating, multi-phase MDCT imaging can provide functional imaging to calculate ventricular volumes. In the absence of other concomitant valve regurgitation, comparison of the right and left ventricular stroke volumes

can provide an estimate of pulmonary RVol and RF with reasonable correlation to values obtained by CMR.¹⁸⁶ This, however, comes at the cost of increased radiation exposure and may only be indicated in the context of non-diagnostic echocardiography and contraindications to CMR.

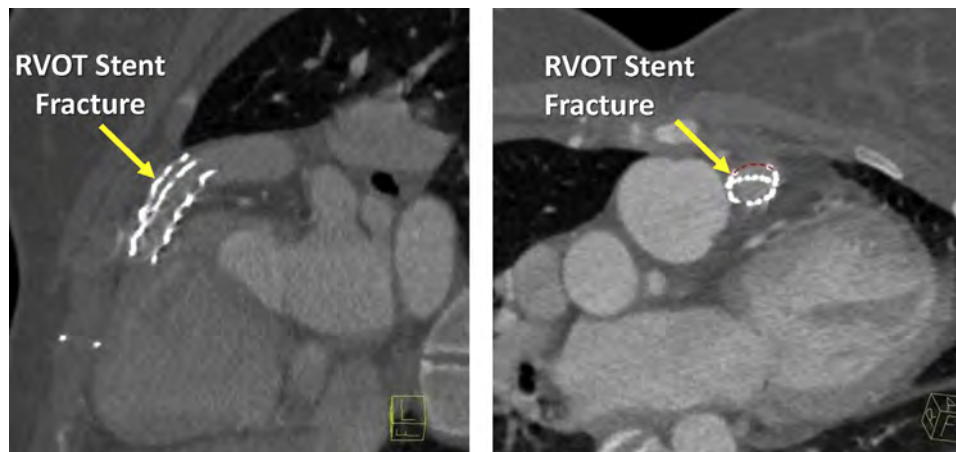


Figure 21 Value of CT angiography in evaluating the mechanism of significant PR after TPVR. Longitudinal and cross-sectional images of a fractured RVOT stent are depicted, showing discontinuity of the stent circumference (*red dotted line*) and collapse of the fractured stent into the vessel lumen.

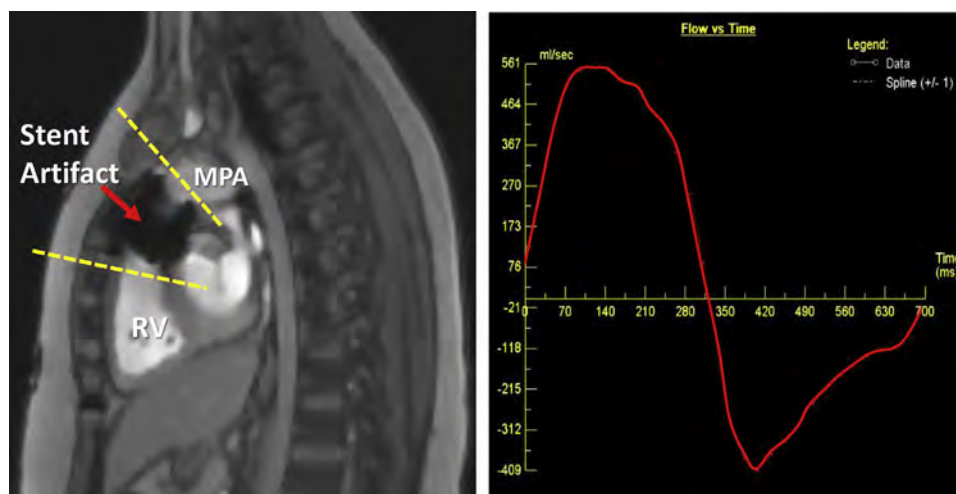


Figure 22 CMR phase-contrast analysis of a patient with severe pulmonary regurgitation, as demonstrated on the flow curve. Quantitation shows a regurgitant fraction of 63%. The left panel shows the stent artifact usually seen with CMR. The *dashed lines* depict the plane where phase-contrast data are obtained for flow quantitation, to avoid the artifact.

3. Role of CMR in Pulmonary Regurgitation after TPVR. CMR imaging allows quantification of PR and assessment of its hemodynamic effects. The methods have been described in detail for native valves.⁷ For patients who have undergone TPVR, this can be done similarly, either directly through flow quantitation in the main PA (Figure 22) or indirectly by several methods, including calculating the differences between right and left ventricular stroke volumes, as described earlier and for native PR.¹⁸⁷ With isolated PR (assuming no other valve regurgitation and no intracardiac shunts), the difference in stroke volumes between the ventricles reflects the RVol.

As is the case for other valve replacement, a significant challenge in this patient population are the imaging artifacts imposed by pre-stenting the RV-PA conduit prior to insertion of the valve. These stents create susceptibility artifacts throughout their length, limiting CMR's ability to fully visualize the RVOT and measure phase-contrast stroke volumes within the conduit itself (Figure 22). In the COMPASSION Trial, only 50% of the initial cohort had complete, interpretable ventricular volumes and phase-contrast data on post-intervention CMR,¹⁷⁴ although

other centers have reported more consistent results with placement of the phase-contrast imaging plane more distal (or proximal) to the stent artifact (Figure 22).¹⁸⁷ In the context of stent artifacts, indirect techniques may be of greater value to quantify regurgitation.

C. Integrative Approach to Assessing Residual Pulmonic Regurgitation after TPVR

TTE is the first-line imaging modality after TPVR to assess prosthetic valve function, the presence and severity of any residual PR, changes in right heart size and function, and PA pressure. If color and spectral Doppler demonstrate no evidence of PR or mild PR, no further imaging is needed. If PR is suspected to be moderate, severe, or indeterminate, CMR is indicated for further quantitation of the regurgitation, and right heart size and function. MDCT, TEE, and catheterization are reserved for patient-specific situations to assess the mechanism of valve dysfunction and/or associated hemodynamics.

There are presently no consensus guidelines for the timing of routine follow-up of patients after TPVR. The trials to date have

performed TTE evaluations at discharge, 1 month, 3 or 6 months, 1 year, and then annually thereafter, with a follow-up CMR at 6 months.¹⁷⁴ In clinical practice many centers roughly follow these early imaging recommendations, but often forego the 3-month TTE and perform the first post-implant CMR either 6 months or one year after TPVR. Follow-up after 1 year post-implant is based predominantly on TTE, but most centers apply the more generalized multimodality imaging guidelines for tetralogy of Fallot,¹⁵⁵⁻¹⁶⁰ which encompass the majority of patients with TPVR, for mid- and long-term follow up. Routine follow-up for asymptomatic patients usually includes TTE every 1-2 years and CMR every 3 years.

Key Points

Assessment of residual PR after pulmonic valve interventions

- Pulmonary regurgitation (PR), when greater than mild in severity, occurs most frequently in patients with palliated or repaired congenital heart disease.
- Experience with grading and, in particular, with quantification of PR after transcatheter pulmonary valve replacement (TPVR) is limited.
- Similar to recommendations for native PR, a combination of Doppler and 2D echocardiographic parameters are needed to grade PR severity. When multiple parameters agree, PR grade can be determined with a high degree of certainty (occurring most often with mild or severe regurgitation).
- Jet width, extent of diastolic flow reversal, pressure half-time, PR duration, and regurgitant velocity waveform density all lend insight into the severity of regurgitation.
- Reverse remodeling of RV volume after intervention should be considered over time as it does not occur immediately after TPVR.
- MDCT plays a role, particularly in assessing valve position and orientation, as well as in evaluating stent fracture. Cardiac CT can be used to quantify pulmonary insufficiency by comparison of ventricular stroke volumes with retrospective gating; this comes at the cost of increased radiation dose.
- CMR provides good quantification of RV volumes and regurgitant fraction. CMR imaging in this patient group is impaired, however, by susceptibility artifact from the TPVR, as well as from any bare metal stents that may be in the RVOT.

VI. PERCUTANEOUS TRICUSPID VALVE INTERVENTIONS

Interest in the tricuspid valve (TV) has increased in recent years with the recognition of the impact of secondary TR on outcomes.¹⁸⁸⁻¹⁹¹ A number of approaches and devices to address symptomatic severe TR are in early development stage or trials.¹⁹² None however, as of the date of this publication, have received FDA approval for this clinical indication. Tricuspid repair devices currently under investigation can be generally divided into those targeting coaptation of the leaflets with edge-to-edge repair and those treating annular dilatation. Individualized valve-in-valve and valve-in-ring procedures are also performed, off-label, in patients who previously underwent TV surgery. TV replacement devices are still in very early stages of development. Since catheter-based intervention on the TV is still an evolving field, a brief overview is presented along with challenges and proposals to the assessment of residual TR.

A. Tricuspid Valve Repair and Annuloplasty

TV repair with the edge-to-edge approach has been recently used to treat severe TR. As stated, this technique is not approved in the US for treatment of TR. A recent registry of 64 cases performed in Europe showed feasibility, an effective reduction in various parameters of TR severity, and an improvement in functional status.¹⁹² Vismara *et al.* developed an ex vivo model of functional TR and showed that grasping the septal and anterior leaflets allowed for the best post-procedural outcome.¹⁹³ In the registry, the most common location of implanted clips was anteroseptal (78%). Although technical success was high (97%) and reduction in at least 1 grade of TR was seen in 91% of patients, 13% of patients had residual severe TR.

In the setting of functional TR, the annulus dilates laterally. The most common surgical tricuspid repair is a ring annuloplasty.¹⁹⁴ Numerous transcatheter tricuspid annular repair devices are currently being investigated, attempting either to reduce the size of the annulus or to replicate the results of the Kay bicuspidization surgical procedure.¹⁹⁵ Practically, all these interventions rely significantly on echocardiography for device placement and assessment of results.¹⁹⁶

B. Assessment of Residual TR after Tricuspid Valve Interventions

The assessment of native TR with echocardiography relies predominantly on TTE, using an integration of information from qualitative and semi-quantitative parameters of color and spectral Doppler.⁷ These include CD evaluation of flow convergence, VC size, and jet behavior/extent in the right atrium, spectral density and contour of the regurgitant velocity waveform by CWD, and assessment of hepatic flow pattern by PWD. Patients undergoing TV interventions to reduce severe TR present particular challenges, at least at this juncture:

1- Lack of well-validated quantitative parameters of TR severity. Evaluation of TR has been traditionally less quantitative than other regurgitant lesions. EROA, RVol, and RF by echocardiography are rarely performed, partly because of technical challenges of quantitation of EROA, RV volumes, or Doppler flow through the TV annulus.

2- Wide range of severe TR. Patients with severe TR are intervened upon currently late in their course, usually when edema and ascites become unresponsive to diuretics. Thus, patients undergoing percutaneous procedures frequently have a markedly dilated valve annulus, right atrium, RV, as well as RV dysfunction. In these patients, the regurgitant orifice can be exceedingly large, 3-4 times the cut-off for severe TR, with obvious non-coaptation of the valve leaflets. In contrast to MR, this wide-open TR is compatible with life. Thus the range within the severe TR category can be very wide, prompting a proposal to extend the current ASE guidelines severity scheme⁷ to include grades of "massive" and "torrential" TR using both semi-quantitative and quantitative methods.¹⁹⁷ This is for the purpose of recording the change in TR following device therapy, as patients may benefit from reduction in TR severity, although residual TR may still be in the moderate or severe range. The clinical significance of this approach and its impact on outcome however, still needs to be evaluated.

3- The type of intervention on the TV may complicate the assessment of residual TR. Challenges of CD evaluation are more likely after edge-to-edge repair, similar to the mitral valve, where multiple jets can be seen, going in different directions. The flow-convergence method in these situations is difficult to apply

Table 9 Proposed grading of the severity of residual tricuspid regurgitation by echocardiography after tricuspid valve interventions

Parameters	Mild	Moderate	Severe
Qualitative			
Color jet area*	Small, narrow, central	Moderate central	Large central jet or eccentric wall-impinging jet(s) of variable size swirling in RA
Flow-convergence zone [†]	Not visible or small	Intermediate in size	Large
TR CW Doppler velocity waveform (density and shape)	Faint/partial/parabolic	Dense, parabolic or triangular	Dense, often triangular
Tricuspid inflow	A-wave dominant	Variable	E-wave dominant ^{‡§}
Semi-quantitative			
VC width (cm)*	<0.3	0.3-0.69	≥0.7 or ≥2 moderate jets
PISA radius (cm) [†]	≤0.5	0.6-0.9	>0.9
Hepatic vein flow [‡]	Systolic dominance	Systolic blunting	Systolic flow reversal
Quantitative			
EROA (cm ²)	<0.20	0.20-0.39	≥0.40
RVol (mL)	<30	30-44	≥45

CW, Continuous-wave; EROA, effective regurgitant orifice area; RA, right atrium; RVol, regurgitant volume; TR, tricuspid regurgitation; VC, vena contracta.

*With Nyquist limit >50-60 cm/s.

[†]Not well-validated for quantitation; best used after interventions that leave the valve intact; baseline Nyquist limit shift to 25-35 cm/s.

[‡]Non-specific, influenced by other factors (RV diastolic function, atrial fibrillation, RA pressure).

[§]Not suitable in procedures intervening with valve leaflets (e.g., edge-to-edge repair).

^{||}EROA from 2D PISA is not suitable in patients with edge-to-edge valve repair because of multiplicity of jets and non-hemispheric shape of flow convergence. Needs further validation of cut-offs by either PISA or volumetric methods.

quantitatively; the VCA method using 3D CD would be likely more appropriate for quantitation, although is not yet well-validated.

There is scant data on how to evaluate residual TR after TV interventions. In the registry of tricuspid edge-to-edge repair,¹⁹² a number of methods to assess regurgitation were used. The vena contracta and PISA-derived EROA and RVol were calculated and summed from the multiple jets. These methods require further validation in view of previous studies showing the limitations of both CD jet characteristics and quantitative methods in assessing MR after edge-to-edge repair.¹²⁹

In the early experience with tricuspid annuloplasty,¹⁹² residual TR was assessed using multiple quantitative methods, including PISA and RVol. Systemic stroke volume was measured using LVOT or RVOT forward flow, and stroke volume across the TV was calculated using annular diameters from orthogonal planes (ellipse formula for annular area), and velocity-time integral (PWD at the annulus). A reduction in tricuspid EROA by quantitative Doppler from 0.9 ± 0.2 to 0.6 ± 0.3 cm² was associated with an increase in LVOT stroke volume, and improvement in functional status. Although the PISA method is simple and easy to perform,¹⁹⁸ the complex relationship of the isovelocity shell to the often elliptical^{199,200} shape and large size of the TR EROA resulted in significant underestimation of volumetric EROA.²⁰¹ Importantly, the SCOUT trial showed that PISA EROA underestimates the quantitative EROA by >50%.²⁰² Other possible novel quantitative methods have been recently reviewed¹⁹⁶ and include quantitative Doppler (using either biplane or 3D annular area) and 3D color Doppler VCA; further validation, however, is needed.

Against this backdrop, and with the current knowledge of assessing TR severity, the Writing Group proposes a few parameters in evalu-

ating TR after interventions on the TV apparatus (Table 9), modified from those previously published for native TR.⁷ These proposed recommendations take into consideration variables that are no longer applicable in assessing TR severity such as right heart chamber size and function, or are less accurate because of the intervention (EROA by 2D PISA after edge-to-edge valve repair). Examples of changes in parameters of TR severity after edge-to-edge repair are shown in Figure 23. The Writing Group acknowledges that the field is evolving and there is a need for further validation of proposed quantitative parameters against independent standards. Irrespective, and as is the case for all valvular regurgitation, an integrative approach to overall evaluation of TR severity is needed to complement any quantitative parameter of residual valve regurgitation.

C. Role of CMR in Assessing Residual TR after Tricuspid Valve Interventions

CMR assessment of TR is less established compared to other regurgitant valvular lesions. A few indirect quantitative techniques have been used, since direct measurement of tricuspid inflow is of limited value.^{7,203} Regurgitant volume can be calculated by subtracting the pulmonic forward stroke volume from the RV stroke volume, from which regurgitant fraction can be derived. Alternatively, in the absence of AR, aortic forward stroke volume can be subtracted from RV stroke volume. Lastly, in the absence of other regurgitant lesions, LV stroke volume can also be subtracted from RV stroke volume to obtain tricuspid regurgitant volume. These methods have significant limitations since the shape of the RV and RVOT present significant problems for short-axis planimetry. A recent study evaluating methods of assessing TR with CMR and comparing them to echocardiographic CD showed that the standard velocity-encoded

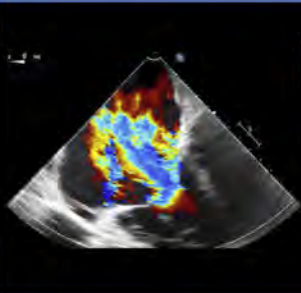
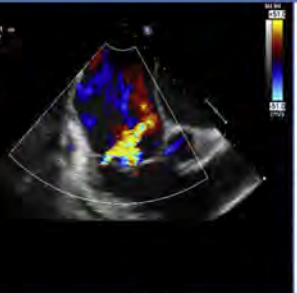
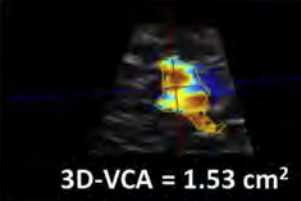
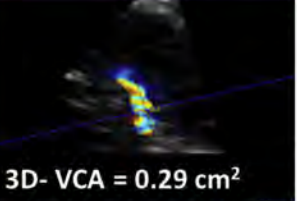
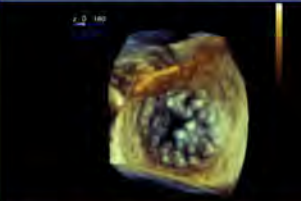
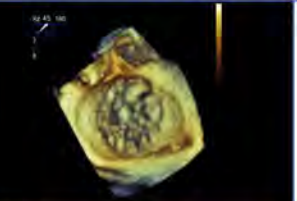

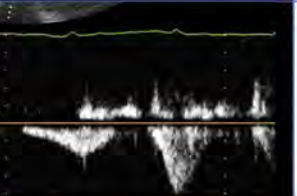
Findings of Reduction in Severe TR	Baseline	After Edge-to-Edge Repair	Specific Features
Significant reduction in color Doppler jet features			<ul style="list-style-type: none"> • Small vena contracta width (< 0.3 cm if mild) of individual TR jets • Small flow convergence radius • Central TR jet with limited penetration into RA
Reduction of 3D VC Area	 3D-VCA = 1.53 cm ²	 3D-VCA = 0.29 cm ²	<ul style="list-style-type: none"> • In TR, VCA can be very large at baseline. A reduction in VCA is expected • Experience with VCA is currently limited
Reduction of systolic anatomic regurgitant orifice area			<ul style="list-style-type: none"> • Clearly evident reduction of anatomic regurgitant orifice area at end-systole
Improvements in hepatic vein PWD profile			<ul style="list-style-type: none"> • Reduction of hepatic vein systolic flow reversal or systolic blunting, with reduction of diastolic forward flow velocity

Figure 23 Illustrative echocardiographic parameters of reduction in severe TR after percutaneous tricuspid repair.

methods had only moderate agreement with echocardiography.²⁰⁴ These issues may be magnified after catheter-based TR interventions, as susceptibility artifacts may invariably occur in the RV base depending on the type of device, hindering visualization of the basal short-axis slice and interfering with RV volumetric measurements. As the field advances, both the methods of quantitation and the grading schemes will require validation.

D. Integrative Approach in the Evaluation of Residual TR

The approach to the evaluation of TR severity is to integrate multiple parameters rather than emphasize or depend on a single measurement; this helps mitigate the effects of technical or measurement errors inherent to each method discussed earlier. Evaluating reduction in TR after catheter-based interventions is an evolving field. While research is progressing, and further validation of quantitative methods are needed, the Writing Group proposes an approach to TR evaluation that would assess first whether there are a majority of signs that would point toward severe regurgitation—the underlying indication for TR interventions (Table 9). A significant reduction in CD jet parameters (flow convergence, VC, and jet area), an improvement in TR jet CWD features toward mild, and

normalization of the hepatic venous flow pattern would point to a significant reduction in TR severity to mild (Table 9 and Figure 23). In less impressive scenarios, one needs to evaluate whether minimal or moderate improvement in parameters has occurred, with more confidence achieved if most of the signs and indices are concordant. While quantitation may be feasible, it is more challenging at this time as the various methods proposed by echocardiography and CMR need further validation and experience.

Key Points

Assessment of residual TR after tricuspid valve interventions

- Tricuspid regurgitation (TR) is most often secondary (functional) due to lateral dilation of the annulus. Primary causes such as flail leaflet are less common.
- Currently, there are no catheter-based devices approved for TV repair. Early experience has been with edge-to-edge repair in the setting of secondary TR; alternative catheter-based approaches are being developed.
- As is the case for native TR, an integrated approach is used to assess severity of residual TR. However, the presence of

multiple jets as commonly seen after edge-to-edge repair, and the limited experience and validation of quantitative parameters complicate this assessment.

- Key elements of evaluating residual TR severity include color jet characteristics, flow convergence, 2D vena contracta, CWD jet waveform density/shape, and hepatic venous flow. 3D VCA may be helpful but needs further experience and validation.
- PISA-derived EROA and regurgitant volume have been used but are less helpful following edge-to-edge repair.
- Quantitative pulsed-wave Doppler approaches are limited after repair.
- While devices may reduce TR and favorably affect clinical status, residual TR with current attempts is frequently moderate or severe using the conventional scoring system. Expanding the grading scheme to include categories of “massive” and “torrential” TR has been suggested to capture the impact of devices. However, this approach and its clinical outcome need further evaluation.
- The use of CMR for quantitation of residual TR after catheter-based interventions is feasible using the indirect method. However, this approach needs further validation as TV devices may create artifacts that can interfere with accuracy of volume calculations.
- As devices evolve, so will approaches to quantitation.

VII. CONCLUSIONS AND FUTURE DIRECTIONS

Catheter-based interventions to repair or replace heart valves have progressed exponentially over the past few years. From early applications in high-risk patients with aortic valve stenosis, catheter-based technology has evolved to address the pulmonic, mitral, and more recently the tricuspid valve. Issues with valve stenosis early after deployment are rare, except after edge-to-edge MV repair with multiple devices, hence the emphasis of the current document on new or residual valve regurgitation. Such an evaluation after valve repair or replacement is important for both guidance of the intervention in the catheterization laboratory and for the overall outcome of patients after the procedure. Thus, the imager is an integral member of the heart valve team. In general, these regurgitant lesions present a challenge to the imager as their mechanism, number, direction, hemodynamics, and underlying cardiac physiology is frequently different from regurgitant native valves. The assessment of regurgitation acutely in the catheterization laboratory frequently requires evaluation of echocardiographic, angiographic, and/or hemodynamic parameters, depending on the valve position. In the outpatient setting, an integrative transthoracic echocardiographic approach is always needed as a first-line assessment. Further imaging with TEE, CMR, and occasionally MDCT may be needed, depending on the initial study and remaining question(s). As more clinical experience is acquired with these interventions, further data on validation, comparative accuracy, and prognostic impact are needed in echocardiography as well as CMR to identify the most optimal quantitative approach and enhance the accuracy and confidence of evaluation of valve regurgitation after catheter-based interventions.

NOTICE AND DISCLAIMER: This report is made available by ASE as a courtesy reference source for members. This report contains rec-

ommendations only and should not be used as the sole basis to make medical practice decisions or for disciplinary action against any employee. The statements and recommendations contained in this report are primarily based on the opinions of experts, rather than on scientifically-verified data. ASE makes no express or implied warranties regarding the completeness or accuracy of the information in this report, including the warranty of merchantability or fitness for a particular purpose. In no event shall ASE be liable to you, your patients, or any other third parties for any decision made or action taken by you or such other parties in reliance on this information. Nor does your use of this information constitute the offering of medical advice by ASE or create any physician-patient relationship between ASE and your patients or anyone else.

Reviewers: This document was reviewed by members of the 2018–2019 ASE Guidelines and Standards Committee, ASE Board of Directors, ASE Executive Committee, and designated representatives from the Japanese Society of Echocardiography, Society for Cardiovascular Angiography and Interventions, and Society for Cardiovascular Magnetic Resonance. Reviewers included Bonita Anderson, MAPPLSC, DMU, AMS, FASE, ACS, Alicia Armour, BS, MA, RDCS, FASE, Azin Alizadehasl, MD, FASE, Scott D. Choyce, RDCS, RVT, RDMS, FASE, Craig Fleishman, MD, FASE, Benjamin Freed, MD, FASE, Mark K. Friedberg, MD, FASE, Edward Gill, MD, FASE, Suzanne Golz, MS, RDCS, FASE, Yuchi Han, MD, MMSc, FASE, FSCMR, Renuka Jain, MD, FASE, Pei-Ni Jone, MD, FASE, James N. Kirkpatrick, MD, FASE, Judy Mangion, MD, FASE, Anuj Mediratta, MD, FASE, Satoshi Nakatani, MD, PhD, Andy Pellett, PhD, RCS, RDCS, FASE, Dermot Phelan, MD, PhD, FASE, Geoffrey A. Rose, MD, FASE, Michael H. Salinger, MD, FSCAI, Stanton Sherman, MD, FASE, Mark Taylor, MD, FASE, David H. Wiener, MD, FASE, and Megan Yamat, RDCS, RCS, FASE.

REFERENCES

1. Nkomo VT, Gardin JM, Skelton TN, Gottdiener JS, Scott CG, Enriquez-Sarano M. Burden of valvular heart diseases: a population-based study. *Lancet* 2006;368:1005-11.
2. Leon MB, Smith CR, Mack MJ, Makkar RR, Svensson LG, Kodali SK, et al. Transcatheter or surgical aortic-valve replacement in intermediate-risk patients. *N Engl J Med* 2016;374:1609-20.
3. Smith CR, Leon MB, Mack MJ, Miller DC, Moses JW, Svensson LG, et al. Transcatheter versus surgical aortic-valve replacement in high-risk patients. *N Engl J Med* 2011;364:2187-98.
4. Adams DH, Popma JJ, Reardon MJ, Yakubov SJ, Coselli JS, Deeb GM, et al. Transcatheter aortic-valve replacement with a self-expanding prosthesis. *N Engl J Med* 2014;370:1790-8.
5. Popma JJ, Adams DH, Reardon MJ, Yakubov SJ, Kleiman NS, Heimansohn D, et al. Transcatheter aortic valve replacement using a self-expanding bioprosthesis in patients with severe aortic stenosis at extreme risk for surgery. *J Am Coll Cardiol* 2014;63:1972-81.
6. Zoghbi WA, Chambers JB, Dumesnil JG, Foster E, Gottdiener JS, Grayburn PA, et al. Recommendations for evaluation of prosthetic valves with echocardiography and Doppler ultrasound: a report from the American Society of Echocardiography's guidelines and standards committee and the task force on prosthetic valves, developed in conjunction with the American College of Cardiology Cardiovascular Imaging Committee, Cardiac Imaging Committee of the American Heart Association, the European Association of Echocardiography, a registered branch of the European Society of Cardiology, the Japanese Society of Echocardiography and the Canadian Society of Echocardiography, endorsed by the American College of Cardiology Foundation, American Heart Association, European Association of Echocardiography, a registered branch of

- the European Society of Cardiology, the Japanese Society of Echocardiography, and Canadian Society of Echocardiography. *J Am Soc Echocardiogr* 2009;22:975-1014. quiz 82-4.
7. Zoghbi WA, Adams D, Bonow RO, Enriquez-Sarano M, Foster E, Grayburn PA, et al. Recommendations for noninvasive evaluation of native valvular regurgitation: a report from the American Society of Echocardiography developed in Collaboration with the Society for Cardiovascular Magnetic Resonance. *J Am Soc Echocardiogr* 2017;30:303-71.
 8. Nishimura RA, Otto CM, Bonow RO, Carabello BA, Erwin JP 3rd, Fleisher LA, et al. 2017 AHA/ACC focused update of the 2014 AHA/ACC guideline for the management of patients with valvular heart disease: a report of the American College of Cardiology/American Heart Association task force on clinical practice guidelines. *J Am Coll Cardiol* 2017;70:252-89.
 9. Leon MB, Smith CR, Mack M, Miller DC, Moses JW, Svensson LG, et al. Transcatheter aortic-valve implantation for aortic stenosis in patients who cannot undergo surgery. *N Engl J Med* 2010;363:1597-607.
 10. Thourani VH, Kodali S, Makkar RR, Herrmann HC, Williams M, Babaliaros V, et al. Transcatheter aortic valve replacement versus surgical valve replacement in intermediate-risk patients: a propensity score analysis. *Lancet* 2016;387:2218-25.
 11. Reardon MJ, Van Mieghem NM, Popma JJ, Kleiman NS, Sondergaard L, Mumtaz M, et al. Surgical or transcatheter aortic-valve replacement in intermediate-risk patients. *N Engl J Med* 2017;376:1321-31.
 12. Athappan G, Patvardhan E, Tuzcu EM, Svensson LG, Lemos PA, Fracarro C, et al. Incidence, predictors, and outcomes of aortic regurgitation after transcatheter aortic valve replacement: meta-analysis and systematic review of literature. *J Am Coll Cardiol* 2013;61:1585-95.
 13. O'Sullivan KE, Gough A, Segurado R, Barry M, Sugrue D, Hurley J. Is valve choice a significant determinant of paravalvular leak post-transcatheter aortic valve implantation? A systematic review and meta-analysis. *Eur J Cardiothorac Surg* 2014;45:826-33.
 14. Hahn RT, Pibarot P, Stewart WJ, Weissman NJ, Gopalakrishnan D, Keane MG, et al. Comparison of transcatheter and surgical aortic valve replacement in severe aortic stenosis: a longitudinal study of echocardiography parameters in cohort A of the PARTNER trial (placement of aortic transcatheter valves). *J Am Coll Cardiol* 2013;61:2514-21.
 15. Abdel-Wahab M, Zahn R, Horack M, Gerckens U, Schuler G, Sievert H, et al. Aortic regurgitation after transcatheter aortic valve implantation: incidence and early outcome. Results from the German transcatheter aortic valve interventions registry. *Heart* 2011;97:899-906.
 16. Gotzmann M, Plijakic A, Bojara W, Lindstaedt M, Ewers A, Germing A, et al. Transcatheter aortic valve implantation in patients with severe symptomatic aortic valve stenosis-predictors of mortality and poor treatment response. *Am Heart J* 2011;162:238-45.e1.
 17. Moat NE, Ludman P, de Belder MA, Bridgewater B, Cunningham AD, Young CP, et al. Long-term outcomes after transcatheter aortic valve implantation in high-risk patients with severe aortic stenosis: the U.K. TAVI (United Kingdom Transcatheter Aortic Valve Implantation) Registry. *J Am Coll Cardiol* 2011;58:2130-8.
 18. Tamburino C, Capodanno D, Ramondo A, Petronio AS, Ertori F, Santoro G, et al. Incidence and predictors of early and late mortality after transcatheter aortic valve implantation in 663 patients with severe aortic stenosis. *Circulation* 2011;123:299-308.
 19. Kodali SK, Williams MR, Smith CR, Svensson LG, Webb JG, Makkar RR, et al. Two-year outcomes after transcatheter or surgical aortic-valve replacement. *N Engl J Med* 2012;366:1686-95.
 20. Pibarot P, Hahn RT, Weissman NJ, Monaghan MJ. Assessment of paravalvular regurgitation following TAVR: a proposal of unifying grading scheme. *JACC Cardiovasc Imaging* 2015;8:340-60.
 21. Lefevre T, Colombo A, Tchetché D, Latib A, Klugmann S, Fajadet J, et al. Prospective multicenter evaluation of the direct flow medical transcatheter aortic valve system: 12-month outcomes of the evaluation of the direct flow medical percutaneous aortic valve 18F system for the treatment of patients with severe aortic stenosis (DISCOVER) study. *JACC Cardiovasc Interv* 2016;9:68-75.
 22. Meredith IT, Walters DL, Dumonteil N, Worthley SG, Tchetché D, Manoharan G, et al. 1-Year outcomes with the fully repositionable and retrievable lotus transcatheter aortic replacement valve in 120 high-risk surgical patients with severe aortic stenosis: results of the REPRISE II study. *JACC Cardiovasc Interv* 2016;9:376-84.
 23. Hahn RT, Little SH, Monaghan MJ, Kodali SK, Williams M, Leon MB, et al. Recommendations for comprehensive intraprocedural echocardiographic imaging during TAVR. *JACC Cardiovasc Imaging* 2015;8:261-87.
 24. Genereux P, Head SJ, Hahn R, Daneault B, Kodali S, Williams MR, et al. Paravalvular leak after transcatheter aortic valve replacement: the new Achilles' heel? A comprehensive review of the literature. *J Am Coll Cardiol* 2013;61:1125-36.
 25. Binder RK, Webb JG, Willson AB, Urena M, Hansson NC, Norgaard BL, et al. The impact of integration of a multidetector computed tomography annulus area sizing algorithm on outcomes of transcatheter aortic valve replacement: a prospective, multicenter, controlled trial. *J Am Coll Cardiol* 2013;62:431-8.
 26. Khaliq OK, Kodali SK, Paradis JM, Nazif TM, Williams MR, Einstein AJ, et al. Aortic annular sizing using a novel 3-dimensional echocardiographic method: use and comparison with cardiac computed tomography. *Circ Cardiovasc Imaging* 2014;7:155-63.
 27. Haensig M, Lehmkühl L, Rastan AJ, Kempfert J, Mukherjee C, Gutberlet M, et al. Aortic valve calcium scoring is a predictor of significant paravalvular aortic insufficiency in transcatheter aortic valve implantation. *Eur J Cardiothorac Surg* 2012;41:1234-40. discussion 40-1.
 28. Khaliq OK, Hahn RT, Gada H, Nazif TM, Vahl TP, George I, et al. Quantity and location of aortic valve complex calcification predicts severity and location of paravalvular regurgitation and frequency of post-dilation after balloon-expandable transcatheter aortic valve replacement. *JACC Cardiovasc Interv* 2014;7:885-94.
 29. Hamid NB, Khaliq OK, Monaghan MJ, Kodali SK, Dvir D, Bapat VN, et al. Transcatheter valve implantation in failed surgically inserted bioprosthesis: review and practical guide to echocardiographic imaging in valve-in-valve procedures. *JACC Cardiovasc Imaging* 2015;8:960-79.
 30. Bijuklic K, Haselbach T, Witt J, Krause K, Hansen L, Gehrckens R, et al. Increased risk of cerebral embolization after implantation of a balloon-expandable aortic valve without prior balloon valvuloplasty. *JACC Cardiovasc Interv* 2015;8:1608-13.
 31. Delgado V, Ng AC, van de Veire NR, van der Kley F, Schuijff JD, Tops LF, et al. Transcatheter aortic valve implantation: role of multi-detector row computed tomography to evaluate prosthesis positioning and deployment in relation to valve function. *Eur Heart J* 2010;31:1114-23.
 32. Kronzon I, Jelmin V, Ruiz CE, Saric M, Williams MR, Kasel AM, et al. Optimal imaging for guiding TAVR: transesophageal or transthoracic echocardiography, or just fluoroscopy? *JACC Cardiovasc Imaging* 2015;8:361-70.
 33. Ali OF, Schultz C, Jabbour A, Rubens M, Mittal T, Mohiaddin R, et al. Predictors of paravalvular aortic regurgitation following self-expanding Medtronic CoreValve implantation: the role of annulus size, degree of calcification, and balloon size during pre-implantation valvuloplasty and implant depth. *Int J Cardiol* 2015;179:539-45.
 34. Greif M, Lange P, Nabauer M, Schwarz F, Becker C, Schmitz C, et al. Transcatheter aortic valve replacement with the Edwards SAPIEN XT and Medtronic CoreValve prosthesis under fluoroscopic guidance and local anaesthesia only. *Heart* 2014;100:691-5.
 35. Dall'Ara G, Eltchaninoff H, Moat N, Laroche C, Goicolea J, Ussia GP, et al. Local and general anaesthesia do not influence outcome of transfemoral aortic valve implantation. *Int J Cardiol* 2014;177:448-54.
 36. Babaliaros V, Devireddy C, Lerakis S, Leonardi R, Iturra SA, Mavromatis K, et al. Comparison of transfemoral transcatheter aortic valve replacement performed in the catheterization laboratory (minimalist approach) versus hybrid operating room (standard approach): outcomes and cost analysis. *JACC Cardiovasc Interv* 2014;7:898-904.
 37. Mayr NP, Michel J, Bleiziffer S, Tassani P, Martin K. Sedation or general anesthesia for transcatheter aortic valve implantation (TAVI). *J Thorac Dis* 2015;7:1518-26.

38. Greason KL, Pochettino A, Sandhu GS, King KS, Holmes DR. Transfemoral transcatheter aortic valve insertion-related intraoperative morbidity: implications of the minimalist approach. *J Thorac Cardiovasc Surg* 2016;151:1026-9.
39. Hyman MC, Vemulapalli S, Szeto WY, Stebbins A, Patel PA, Matsouka RA, et al. Conscious sedation versus general anesthesia for transcatheter aortic valve replacement: insights from the National Cardiovascular Data Registry Society of Thoracic Surgeons/American College of Cardiology transcatheter valve therapy registry. *Circulation* 2017;136:2132-40.
40. Bagur R, Rodes-Cabau J, Doyle D, De Larocheliere R, Villeneuve J, Lemieux J, et al. Usefulness of TEE as the primary imaging technique to guide transcatheter transapical aortic valve implantation. *JACC Cardiovasc Imaging* 2011;4:115-24.
41. Oguri A, Yamamoto M, Mouillet G, Gilard M, Laskar M, Eltchaninoff H, et al. Clinical outcomes and safety of transfemoral aortic valve implantation under general versus local anesthesia: subanalysis of the French Aortic National CoreValve and Edwards 2 registry. *Circ Cardiovasc Interv* 2014;7:602-10.
42. Hayek SS, Corrigan FE 3rd, Condado JF, Lin S, Howell S, MacNamara JP, et al. Paravalvular regurgitation after transcatheter aortic valve replacement: comparing transthoracic versus transesophageal echocardiographic guidance. *J Am Soc Echocardiogr* 2017;30:533-40.
43. de Brito FS Jr, Carvalho LA, Sarmento-Leite R, Mangione JA, Lemos P, Siciliano A, et al. Outcomes and predictors of mortality after transcatheter aortic valve implantation: results of the Brazilian registry. *Catheter Cardiovasc Interv* 2015;85:E153-62.
44. Condado JF, Haider MN, Lerakis S, Keegan P, Caughron H, Thourani VH, et al. Does minimalist transfemoral transcatheter aortic valve replacement produce better survival in patients with severe chronic obstructive pulmonary disease? *Catheter Cardiovasc Interv* 2017;89:775-80.
45. Kodali S, Thourani VH, White J, Malaisrie SC, Lim S, Greason KL, et al. Early clinical and echocardiographic outcomes after SAPIEN 3 transcatheter aortic valve replacement in inoperable, high-risk and intermediate-risk patients with aortic stenosis. *Eur Heart J* 2016;37:2252-62.
46. Hahn RT, Gillam LD, Little SH. Echocardiographic imaging of procedural complications during self-expandable transcatheter aortic valve replacement. *JACC Cardiovasc Imaging* 2015;8:319-36.
47. Hahn RT, Kodali S, Tuzcu EM, Leon MB, Kapadia S, Gopal D, et al. Echocardiographic imaging of procedural complications during balloon-expandable transcatheter aortic valve replacement. *JACC Cardiovasc Imaging* 2015;8:288-318.
48. Kiramijyan S, Ben-Dor I, Koifman E, Didier R, Magalhaes MA, Escarcega RO, et al. Comparison of clinical outcomes with the utilization of monitored anesthesia care vs. general anesthesia in patients undergoing transcatheter aortic valve replacement. *Cardiovasc Rev Med* 2016;17:384-90.
49. Sellers RD, Levy MJ, Amplatz K, Lillehei CW. Left retrograde cardiography in acquired cardiac disease: technic, indications and interpretations in 700 cases. *Am J Cardiol* 1964;14:437-47.
50. Michel PL, Vahanian A, Besnainou F, Acar J. Value of qualitative angiographic grading in aortic regurgitation. *Eur Heart J* 1987;8(Suppl C):11-4.
51. Croft CH, Lipscomb K, Mathis K, Firth BG, Nicod P, Tilton G, et al. Limitations of qualitative angiographic grading in aortic or mitral regurgitation. *Am J Cardiol* 1984;53:1593-8.
52. Sinning JM, Hammerstingl C, Vasa-Nicotera M, Adenauer V, Lema Cachiguango SJ, Scheer AC, et al. Aortic regurgitation index defines severity of peri-prosthetic regurgitation and predicts outcome in patients after transcatheter aortic valve implantation. *J Am Coll Cardiol* 2012;59:1134-41.
53. Jilaihawi H, Chakravarty T, Shiota T, Rafique A, Harada K, Shibayama K, et al. Heart-rate adjustment of transcatheter haemodynamics improves the prognostic evaluation of paravalvular regurgitation after transcatheter aortic valve implantation. *EuroIntervention* 2015;11:456-64.
54. Sinning JM, Stundl A, Pingel S, Weber M, Sedaghat A, Hammerstingl C, et al. Pre-procedural hemodynamic status improves the discriminatory value of the aortic regurgitation index in patients undergoing transcatheter aortic valve replacement. *JACC Cardiovasc Interv* 2016;9:700-11.
55. Bugan B, Kapadia S, Svensson L, Krishnaswamy A, Tuzcu EM. Novel hemodynamic index for assessment of aortic regurgitation after transcatheter aortic valve replacement. *Catheter Cardiovasc Interv* 2015;86:E174-9.
56. Mihara H, Shibayama K, Jilaihawi H, Itabashi Y, Berdejo J, Utsunomiya H, et al. Assessment of post-procedural aortic regurgitation after TAVR: an intraprocedural TEE study. *JACC Cardiovasc Imaging* 2015;8:993-1003.
57. Kappetein AP, Head SJ, Genereux P, Piazza N, van Mieghem NM, Blackstone EH, et al. Updated standardized endpoint definitions for transcatheter aortic valve implantation: the Valve Academic Research Consortium-2 consensus document. *J Am Coll Cardiol* 2012;60:1438-54.
58. Douglas PS, Waugh RA, Bloomfield G, Dunn G, Davis L, Hahn RT, et al. Implementation of echocardiography core laboratory best practices: a case study of the PARTNER I trial. *J Am Soc Echocardiogr* 2013;26:348-358 e3.
59. Jones BM, Tuzcu EM, Krishnaswamy A, Popovic Z, Mick S, Roselli EE, et al. Prognostic significance of mild aortic regurgitation in predicting mortality after transcatheter aortic valve replacement. *J Thorac Cardiovasc Surg* 2016;152:783-90.
60. Lang RM, Badano LP, Tsang W, Adams DH, Agricola E, Buck T, et al. EAE/ASE recommendations for image acquisition and display using three-dimensional echocardiography. *J Am Soc Echocardiogr* 2012;25:3-46.
61. Perez de Isla L, Zamorano J, Fernandez-Golfín C, Ciocarelli S, Corros C, Sanchez T, et al. 3D color-Doppler echocardiography and chronic aortic regurgitation: a novel approach for severity assessment. *Int J Cardiol* 2013;166:640-5.
62. Goncalves A, Almeria C, Marcos-Alberca P, Feltes G, Hernandez-Antolin R, Rodriguez E, et al. Three-dimensional echocardiography in paravalvular aortic regurgitation assessment after transcatheter aortic valve implantation. *J Am Soc Echocardiogr* 2012;25:47-55.
63. Mori Y, Shiota T, Jones M, Wanitkun S, Irvine T, Li X, et al. Three-dimensional reconstruction of the color Doppler-imaged vena contracta for quantifying aortic regurgitation: studies in a chronic animal model. *Circulation* 1999;99:1611-7.
64. Fang L, Hsiung MC, Miller AP, Nanda NC, Yin WH, Young MS, et al. Assessment of aortic regurgitation by live three-dimensional transthoracic echocardiographic measurements of vena contracta area: usefulness and validation. *Echocardiography* 2005;22:775-81.
65. Pirat B, Little SH, Igo SR, McCulloch M, Nose Y, Hartley CJ, et al. Direct measurement of proximal isovelocity surface area by real-time three-dimensional color Doppler for quantitation of aortic regurgitant volume: an in vitro validation. *J Am Soc Echocardiogr* 2009;22:306-13.
66. Palau-Caballero G, Walmsley J, Gorcsan J 3rd, Lumens J, Delhaas T. Abnormal ventricular and aortic wall properties can cause inconsistencies in grading aortic regurgitation severity: a computer simulation study. *J Am Soc Echocardiogr* 2016;29:1122-30.e4.
67. Svedlund S, Wetterholm R, Volkmann R, Caidahl K. Retrograde blood flow in the aortic arch determined by transesophageal Doppler ultrasound. *Cerebrovasc Dis* 2009;27:22-8.
68. Hashimoto J, Ito S. Aortic stiffness determines diastolic blood flow reversal in the descending thoracic aorta: potential implication for retrograde embolic stroke in hypertension. *Hypertension* 2013;62:542-9.
69. Lancellotti P, Tribouilloy C, Hagendorff A, Moura L, Popescu BA, Agricola E, et al. European Association of Echocardiography recommendations for the assessment of valvular regurgitation. Part 1: aortic and pulmonary regurgitation (native valve disease). *Eur J Echocardiogr* 2010;11:223-44.
70. Takenaka K, Dabestani A, Gardin JM, Russell D, Clark S, Allie A, et al. A simple Doppler echocardiographic method for estimating severity of aortic regurgitation. *Am J Cardiol* 1986;57:1340-3.
71. Hahn RT, Leipsic J, Douglas PS, Jaber WA, Weissman NJ, Pibarot P, et al. Comprehensive echocardiographic assessment of normal transcatheter valve function. *JACC Cardiovasc Imaging* 2018.

72. Kodali S, Pibarot P, Douglas PS, Williams M, Xu K, Thourani V, et al. Paravalvular regurgitation after transcatheter aortic valve replacement with the Edwards sapien valve in the PARTNER trial: characterizing patients and impact on outcomes. *Eur Heart J* 2015;36:449-56.
73. Ribeiro HB, Orwat S, Hayek SS, Larose E, Babaliaros V, Dahou A, et al. Cardiovascular magnetic resonance to evaluate aortic regurgitation after transcatheter aortic valve replacement. *J Am Coll Cardiol* 2016;68:577-85.
74. Oh JK, Little SH, Abdelmoneim SS, Reardon MJ, Kleiman NS, Lin G, et al. Regression of paravalvular aortic regurgitation and remodeling of self-expanding transcatheter aortic valve: an observation from the core-valve U.S. pivotal trial. *JACC Cardiovasc Imaging* 2015;8:1364-75.
75. Pibarot P, Hahn RT, Weissman NJ, Arsenaault M, Beaudoin J, Bernier M, et al. Association of paravalvular regurgitation with 1-year outcomes after transcatheter aortic valve replacement with the SAPIEN 3 valve. *JAMA Cardiol* 2017;2:1208-16.
76. Chakravarty T, Sondergaard L, Friedman J, De Backer O, Berman D, Kofoed KF, et al. Subclinical leaflet thrombosis in surgical and transcatheter bioprosthetic aortic valves: an observational study. *Lancet* 2017;389:2383-92.
77. Ruiz CE, Hahn RT, Berrebi A, Borer JS, Cutlip DE, Fontana G, et al. Clinical trial principles and endpoint definitions for paravalvular leaks in surgical prosthesis: an expert statement. *J Am Coll Cardiol* 2017;69:2067-87.
78. Hartlage GR, Babaliaros VC, Thourani VH, Hayek S, Chrysohoou C, Ghasemzadeh N, et al. The role of cardiovascular magnetic resonance in stratifying paravalvular leak severity after transcatheter aortic valve replacement: an observational outcome study. *J Cardiovasc Magn Reson* 2014;16:93.
79. Crouch G, Tully PJ, Bennetts J, Sinhal A, Bradbrook C, Penhall AL, et al. Quantitative assessment of paravalvular regurgitation following transcatheter aortic valve replacement. *J Cardiovasc Magn Reson* 2015;17:32.
80. Merten C, Beurich HW, Zachow D, Mostafa AE, Geist V, Toelg R, et al. Aortic regurgitation and left ventricular remodeling after transcatheter aortic valve implantation: a serial cardiac magnetic resonance imaging study. *Circ Cardiovasc Interv* 2013;6:476-83.
81. Sherif MA, Abdel-Wahab M, Beurich HW, Stocker B, Zachow D, Geist V, et al. Haemodynamic evaluation of aortic regurgitation after transcatheter aortic valve implantation using cardiovascular magnetic resonance. *Euro-Intervention* 2011;7:57-63.
82. Altiok E, Frick M, Meyer CG, Al Ateah G, Napp A, Kirschfink A, et al. Comparison of two- and three-dimensional transthoracic echocardiography to cardiac magnetic resonance imaging for assessment of paravalvular regurgitation after transcatheter aortic valve implantation. *Am J Cardiol* 2014;113:1859-66.
83. Cawley PJ, Hamilton-Craig C, Owens DS, Krieger EV, Strugnell WE, Mitsumori L, et al. Prospective comparison of valve regurgitation quantitation by cardiac magnetic resonance imaging and transthoracic echocardiography. *Circ Cardiovasc Imaging* 2013;6:48-57.
84. Abdel-Wahab M, Mehilli J, Frerker C, Neumann FJ, Kurz T, Tolg R, et al. Comparison of balloon-expandable vs self-expandable valves in patients undergoing transcatheter aortic valve replacement: the CHOICE randomized clinical trial. *JAMA* 2014;311:1503-14.
85. Ribeiro HB, Le Ven F, Larose E, Dahou A, Nombela-Franco L, Urena M, et al. Cardiac magnetic resonance versus transthoracic echocardiography for the assessment and quantification of aortic regurgitation in patients undergoing transcatheter aortic valve implantation. *Heart* 2014;100:1924-32.
86. Orwat S, Diller GP, Kaleschke G, Kerckhoff G, Kempny A, Radke RM, et al. Aortic regurgitation severity after transcatheter aortic valve implantation is underestimated by echocardiography compared with MRI. *Heart* 2014;100:1933-8.
87. Gopalakrishnan D, Gopal A, Grayburn PA. Evaluating paravalvular leak after TAVR. *Heart* 2014;100:1903-4.
88. American College of Cardiology Foundation Task Force on Expert Consensus D, Hundley WG, Bluemke DA, Finn JP, Flamm SD, Fogel MA, Friedrich MG, et al. ACCF/ACR/AHA/NASCI/SCMR 2010 expert consensus document on cardiovascular magnetic resonance: a report of the American College of Cardiology Foundation task force on expert consensus documents. *J Am Coll Cardiol* 2010;55:2614-62.
89. Myerson SG. Heart valve disease: investigation by cardiovascular magnetic resonance. *J Cardiovasc Magn Reson* 2012;14:7.
90. Lerakis S, Hayek S, Arepalli CD, Thourani V, Babaliaros V. Cardiac magnetic resonance for paravalvular leaks in post-transcatheter aortic valve replacement. *Circulation* 2014;129:e430-1.
91. Dahiya A, Bolen M, Grimm RA, Rodriguez LL, Thomas JD, Marwick TH, et al. Development of a consensus document to improve multireader concordance and accuracy of aortic regurgitation severity grading by echocardiography versus cardiac magnetic resonance imaging. *Am J Cardiol* 2012;110:709-14.
92. Cavalcante JL, Lalude OO, Schoenhagen P, Lerakis S. Cardiovascular magnetic resonance imaging for structural and valvular heart disease interventions. *JACC Cardiovasc Interv* 2016;9:399-425.
93. Myerson SG, d'Arcy J, Mohiaddin R, Greenwood JP, Karamitsos TD, Francis JM, et al. Aortic regurgitation quantification using cardiovascular magnetic resonance: association with clinical outcome. *Circulation* 2012;126:1452-60.
94. Gabriel RS, Renapurkar R, Bolen MA, Verhaert D, Leiber M, Flamm SD, et al. Comparison of severity of aortic regurgitation by cardiovascular magnetic resonance versus transthoracic echocardiography. *Am J Cardiol* 2011;108:1014-20.
95. Gelfand EV, Hughes S, Hauser TH, Yeon SB, Goepfert L, Kissinger KV, et al. Severity of mitral and aortic regurgitation as assessed by cardiovascular magnetic resonance: optimizing correlation with Doppler echocardiography. *J Cardiovasc Magn Reson* 2006;8:503-7.
96. Corrigan FE 3rd, Chen JH, Maini A, Lisko JC, Alvarez L, Kamioka N, et al. Pulmonary venous waveforms predict rehospitalization and mortality after percutaneous mitral valve repair. *JACC Cardiovasc Imaging* 2018. [Article in Press] <https://doi.org/10.1016/j.jcmg.2018.08.004>.
97. Praz F, Spargias K, Chrissoheris M, Bullesfeld L, Nickenig G, Deuschl F, et al. Compassionate use of the PASCAL transcatheter mitral valve repair system for patients with severe mitral regurgitation: a multicentre, prospective, observational, first-in-man study. *Lancet* 2017;390:773-80.
98. Lin BA, Forouhar AS, Pahlevan NM, Anastassiou CA, Grayburn PA, Thomas JD, et al. Color Doppler jet area overestimates regurgitant volume when multiple jets are present. *J Am Soc Echocardiogr* 2010;23:993-1000.
99. Altiok E, Hamada S, Brehmer K, Kuhr K, Reith S, Becker M, et al. Analysis of procedural effects of percutaneous edge-to-edge mitral valve repair by 2D and 3D echocardiography. *Circ Cardiovasc Imaging* 2012;5:748-55.
100. Gruner C, Herzog B, Bettex D, Felix C, Datta S, Greutmann M, et al. Quantification of mitral regurgitation by real time three-dimensional color Doppler flow echocardiography pre- and post-percutaneous mitral valve repair. *Echocardiography* 2015;32:1140-6.
101. Avenatti E, Mackensen GB, El Tallawi C, Reisman M, Gruye L, Barker C, et al. Diagnostic value of 3D Vena Contracta Area for the quantification of residual mitral regurgitation after MitraClip procedure. *JACC Cardiovasc Interv* 2019. [Article in Press].
102. Lubos E, Schluter M, Vettorazzi E, Goldmann B, Lubs D, Schirmer J, et al. MitraClip therapy in surgical high-risk patients: identification of echocardiographic variables affecting acute procedural outcome. *JACC Cardiovasc Interv* 2014;7:394-402.
103. Biaggi P, Felix C, Gruner C, Herzog BA, Hohlfeld S, Gaemperli O, et al. Assessment of mitral valve area during percutaneous mitral valve repair using the MitraClip system: comparison of different echocardiographic methods. *Circ Cardiovasc Imaging* 2013;6:1032-40.
104. Lutter G, Lozonschi L, Ebner A, Gallo S, Marin y Kall C, Missov E, et al. First-in-human off-pump transcatheter mitral valve replacement. *JACC Cardiovasc Interv* 2014;7:1077-8.
105. Bapat V, Buellfeld L, Peterson MD, Hancock J, Reineke D, Buller C, et al. Transcatheter mitral valve implantation (TMVI) using the Edwards FORTIS device. *EuroIntervention* 2014;10(Suppl U):U120-8.

106. Cheung A, Webb J, Verheye S, Moss R, Boone R, Leipsic J, et al. Short-term results of transapical transcatheter mitral valve implantation for mitral regurgitation. *J Am Coll Cardiol* 2014;64:1814-9.
107. Sondergaard L, De Backer O, Franzen OW, Holme SJ, Ihlemann N, Vejstrup NG, et al. First-in-human case of transfemoral CardiAQ mitral valve implantation. *Circ Cardiovasc Interv* 2015;8:e002135.
108. Moat N, Duncan A, Lindsay A, Quarto C, Blanke P, Leipsic J, et al. Transcatheter mitral valve replacement for the treatment of mitral regurgitation: in-hospital outcomes of an apically tethered device. *J Am Coll Cardiol* 2015;65:2352-3.
109. Theriault-Lauzier P, Andalib A, Martucci G, Mylotte D, Cecere R, Lange R, et al. Fluoroscopic anatomy of left-sided heart structures for transcatheter interventions: insight from multislice computed tomography. *JACC Cardiovasc Interv* 2014;7:947-57.
110. Blanke P, Dvir D, Cheung A, Levine RA, Thompson C, Webb JG, et al. Mitral annular evaluation with CT in the context of transcatheter mitral valve replacement. *JACC Cardiovasc Imaging* 2015;8:612-5.
111. Blanke P, Naoum C, Webb J, Dvir D, Hahn RT, Grayburn P, et al. Multimodality imaging in the context of transcatheter mitral valve replacement: establishing consensus among modalities and disciplines. *JACC Cardiovasc Imaging* 2015;8:1191-208.
112. Guerrero M, Dvir D, Himbert D, Urena M, Eleid M, Wang DD, et al. Transcatheter mitral valve replacement in native mitral valve disease with severe mitral annular calcification: results from the First Multicenter Global Registry. *JACC Cardiovasc Interv* 2016;9:1361-71.
113. Yoon SH, Whisenant BK, Bleiziffer S, Delgado V, Schofer N, Eschenbach L, et al. Transcatheter mitral valve replacement for degenerated bioprosthetic valves and failed annuloplasty rings. *J Am Coll Cardiol* 2017;70:1121-31.
114. Muller DWM, Farivar RS, Jansz P, Bae R, Walters D, Clarke A, et al. Transcatheter mitral valve replacement for patients with symptomatic mitral regurgitation: a Global Feasibility Trial. *J Am Coll Cardiol* 2017;69:381-91.
115. Bapat V, Rajagopal V, Meduri C, Farivar RS, Walton A, Duffy SJ, et al. Early experience with new transcatheter mitral valve replacement. *J Am Coll Cardiol* 2018;71:12-21.
116. Timek TA, Lai DT, Tibayan F, Liang D, Daughters GT, Dagum P, et al. Septal-lateral annular cinching abolishes acute ischemic mitral regurgitation. *J Thorac Cardiovasc Surg* 2002;123:881-8.
117. Webb JG, Harnek J, Munt BI, Kimblad PO, Chandavimol M, Thompson CR, et al. Percutaneous transvenous mitral annuloplasty: initial human experience with device implantation in the coronary sinus. *Circulation* 2006;113:851-5.
118. Schofer J, Siminiak T, Haude M, Herrman JP, Vainer J, Wu JC, et al. Percutaneous mitral annuloplasty for functional mitral regurgitation: results of the CARILLON Mitral Annuloplasty Device European Union Study. *Circulation* 2009;120:326-33.
119. Siminiak T, Wu JC, Haude M, Hoppe UC, Sadowski J, Lipiecki J, et al. Treatment of functional mitral regurgitation by percutaneous annuloplasty: results of the TITAN Trial. *Eur J Heart Fail* 2012;14:931-8.
120. Mandinov LAF, Grube E. Mitralign percutaneous annuloplasty system for the treatment of functional mitral regurgitation. *European Cardiology* 2010;6:67-70.
121. Maisano F, La Canna G, Latib A, Denti P, Taramasso M, Kuck KH, et al. First-in-man transseptal implantation of a "surgical-like" mitral valve annuloplasty device for functional mitral regurgitation. *JACC Cardiovasc Interv* 2014;7:1326-8.
122. Nickenig G, Hammerstingl C, Schueler R, Topilsky Y, Grayburn PA, Vahanian A, et al. Transcatheter mitral annuloplasty in chronic functional mitral regurgitation: 6-Month results with the cardioband percutaneous mitral repair system. *JACC Cardiovasc Interv* 2016;9:2039-47.
123. Arsalan M, Agricola E, Alfieri O, Baldus S, Colombo A, Filardo G, et al. Effect of transcatheter mitral annuloplasty with the cardioband device on 3-dimensional geometry of the mitral annulus. *Am J Cardiol* 2016;118:744-9.
124. Rihal CS, Sorajja P, Booker JD, Hagler DJ, Cabalka AK. Principles of percutaneous paravalvular leak closure. *JACC Cardiovasc Interv* 2012;5:121-30.
125. Grayburn PA, Foster E, Sangli C, Weissman NJ, Massaro J, Glower DG, et al. Relationship between the magnitude of reduction in mitral regurgitation severity and left ventricular and left atrial reverse remodeling after MitraClip therapy. *Circulation* 2013;128:1667-74.
126. Zamorano JL, Badano LP, Bruce C, Chan KL, Goncalves A, Hahn RT, et al. EAE/ASE recommendations for the use of echocardiography in new transcatheter interventions for valvular heart disease. *J Am Soc Echocardiogr* 2011;24:937-65.
127. Foster E, Wasserman HS, Gray W, Homma S, Di Tullio MR, Rodriguez L, et al. Quantitative assessment of severity of mitral regurgitation by serial echocardiography in a multicenter clinical trial of percutaneous mitral valve repair. *Am J Cardiol* 2007;100:1577-83.
128. Siegel RJ, Biner S, Rafique AM, Rinaldi M, Lim S, Fail P, et al. The acute hemodynamic effects of MitraClip therapy. *J Am Coll Cardiol* 2011;57:1658-65.
129. Hamilton-Craig C, Strugnell W, Gaikwad N, Ischenko M, Speranza V, Chan J, et al. Quantitation of mitral regurgitation after percutaneous MitraClip repair: comparison of Doppler echocardiography and cardiac magnetic resonance imaging. *Ann Cardiothorac Surg* 2015;4:341-51.
130. Luis SA, Blauwet LA, Samardhi H, West C, Mehta RA, Luis CR, et al. Usefulness of mitral valve prosthetic or bioprosthetic time velocity index ratio to detect prosthetic or bioprosthetic mitral valve dysfunction. *Am J Cardiol* 2017;120:1373-80.
131. Sucha D, Symersky P, Tanis W, Mali WP, Leiner T, van Herwerden LA, et al. Multimodality imaging assessment of prosthetic heart valves. *Circ Cardiovasc Imaging* 2015;8:e003703.
132. Thavendiranathan P, Phelan D, Thomas JD, Flamm SD, Marwick TH. Quantitative assessment of mitral regurgitation: validation of new methods. *J Am Coll Cardiol* 2012;60:1470-83.
133. Myerson SG, Francis JM, Neubauer S. Direct and indirect quantification of mitral regurgitation with cardiovascular magnetic resonance, and the effect of heart rate variability. *MAGMA* 2010;23:243-9.
134. Marsan NA, Westenberg JJ, Ypenburg C, Delgado V, van Bommel RJ, Roes SD, et al. Quantification of functional mitral regurgitation by real-time 3D echocardiography: comparison with 3D velocity-encoded cardiac magnetic resonance. *JACC Cardiovasc Imaging* 2009;2:1245-52.
135. Buchner S, Debl K, Poschenrieder F, Feuerbach S, Riegger GA, Luchner A, et al. Cardiovascular magnetic resonance for direct assessment of anatomic regurgitant orifice in mitral regurgitation. *Circ Cardiovasc Imaging* 2008;1:148-55.
136. Hundley WG, Li HF, Willard JE, Landau C, Lange RA, Meshack BM, et al. Magnetic resonance imaging assessment of the severity of mitral regurgitation. Comparison with invasive techniques. *Circulation* 1995;92:1151-8.
137. Kizilbash AM, Hundley WG, Willett DL, Franco F, Peshock RM, Grayburn PA. Comparison of quantitative Doppler with magnetic resonance imaging for assessment of the severity of mitral regurgitation. *Am J Cardiol* 1998;81:792-5.
138. Glogar D, Globits S, Neuhold A, Mayr H. Assessment of mitral regurgitation by magnetic resonance imaging. *Magn Reson Imaging* 1989;7:611-7.
139. Guo YK, Yang ZG, Ning G, Rao L, Dong L, Pen Y, et al. Isolated mitral regurgitation: quantitative assessment with 64-section multidetector CT—comparison with MR imaging and echocardiography. *Radiology* 2009;252:369-76.
140. Kon MW, Myerson SG, Moat NE, Pennell DJ. Quantification of regurgitant fraction in mitral regurgitation by cardiovascular magnetic resonance: comparison of techniques. *J Heart Valve Dis* 2004;13:600-7.

141. Fujita N, Chazouilleres AF, Hartiala JJ, O'Sullivan M, Heidenreich P, Kaplan JD, et al. Quantification of mitral regurgitation by velocity-encoded cine nuclear magnetic resonance imaging. *J Am Coll Cardiol* 1994;23:951-8.
142. Myerson SG, d'Arcy J, Christiansen JP, Dobson LE, Mohiaddin R, Francis JM, et al. Determination of clinical outcome in mitral regurgitation with cardiovascular magnetic resonance quantification. *Circulation* 2016;133:2287-96.
143. Kawel-Boehm N, Maceira A, Valsangiacomo-Buechel ER, Vogel-Claussen J, Turkbey EB, Williams R, et al. Normal values for cardiovascular magnetic resonance in adults and children. *J Cardiovasc Magn Reson* 2015;17:29.
144. Krumm P, Zuern CS, Wurster TH, Mangold S, Klumpp BD, Henning A, et al. Cardiac magnetic resonance imaging in patients undergoing percutaneous mitral valve repair with the MitraClip system. *Clin Res Cardiol* 2014;103:397-404.
145. Radunski UK, Franzen O, Barmeyer A, Lange M, Lund G, Rudolph V, et al. Cardiac remodeling following percutaneous mitral valve repair - initial results assessed by cardiovascular magnetic resonance imaging. *Rofo* 2014;186:951-8.
146. Kramer CM, Barkhausen J, Flamm SD, Kim RJ, Nagel E. Society for Cardiovascular Magnetic Resonance Board of Trustees task force on standardized P. Standardized cardiovascular magnetic resonance (CMR) protocols 2013 update. *J Cardiovasc Magn Reson* 2013;15:91.
147. Schulz-Menger J, Bluemke DA, Bremerich J, Flamm SD, Fogel MA, Friedrich MG, et al. Standardized image interpretation and post processing in cardiovascular magnetic resonance: Society for Cardiovascular Magnetic Resonance (SCMR) board of trustees task force on standardized post processing. *J Cardiovasc Magn Reson* 2013;15:35.
148. Alfakih K, Plein S, Thiele H, Jones T, Ridgway JP, Sivananthan MU. Normal human left and right ventricular dimensions for MRI as assessed by turbo gradient echo and steady-state free precession imaging sequences. *J Magn Reson Imaging* 2003;17:323-9.
149. Maceira AM, Prasad SK, Khan M, Pennell DJ. Reference right ventricular systolic and diastolic function normalized to age, gender and body surface area from steady-state free precession cardiovascular magnetic resonance. *Eur Heart J* 2006;27:2879-88.
150. Maceira AM, Prasad SK, Khan M, Pennell DJ. Normalized left ventricular systolic and diastolic function by steady state free precession cardiovascular magnetic resonance. *J Cardiovasc Magn Reson* 2006;8:417-26.
151. Hudsmith LE, Petersen SE, Francis JM, Robson MD, Neubauer S. Normal human left and right ventricular and left atrial dimensions using steady state free precession magnetic resonance imaging. *J Cardiovasc Magn Reson* 2005;7:775-82.
152. Maceira AM, Cosin-Sales J, Roughton M, Prasad SK, Pennell DJ. Reference left atrial dimensions and volumes by steady state free precession cardiovascular magnetic resonance. *J Cardiovasc Magn Reson* 2010;12:65.
153. Carvalho JS, Shinebourne EA, Busst C, Rigby ML, Redington AN. Exercise capacity after complete repair of tetralogy of Fallot: deleterious effects of residual pulmonary regurgitation. *Br Heart J* 1992;67:470-3.
154. Gatzoulis MA, Balaji S, Webber SA, Siu SC, Hokanson JS, Poile C, et al. Risk factors for arrhythmia and sudden cardiac death late after repair of tetralogy of Fallot: a multicentre study. *Lancet* 2000;356:975-81.
155. Valente AM, Cook S, Festa P, Ko HH, Krishnamurthy R, Taylor AM, et al. Multimodality imaging guidelines for patients with repaired tetralogy of fallot: a report from the American Society of Echocardiography: developed in collaboration with the Society for Cardiovascular Magnetic Resonance and the Society for Pediatric Radiology. *J Am Soc Echocardiogr* 2014;27:111-41.
156. Bokma JP, Winter MM, Oosterhof T, Vliegen HW, van Dijk AP, Hazekamp MG, et al. Preoperative thresholds for mid-to-late haemodynamic and clinical outcomes after pulmonary valve replacement in tetralogy of Fallot. *Eur Heart J* 2016;37:829-35.
157. Geva T. Repaired tetralogy of Fallot: the roles of cardiovascular magnetic resonance in evaluating pathophysiology and for pulmonary valve replacement decision support. *J Cardiovasc Magn Reson* 2011;13:9.
158. Oosterhof T, van Straten A, Vliegen HW, Meijboom FJ, van Dijk AP, Spijkerboer AM, et al. Preoperative thresholds for pulmonary valve replacement in patients with corrected tetralogy of Fallot using cardiovascular magnetic resonance. *Circulation* 2007;116:545-51.
159. Therrien J, Provost Y, Merchant N, Williams W, Colman J, Webb G. Optimal timing for pulmonary valve replacement in adults after tetralogy of Fallot repair. *Am J Cardiol* 2005;95:779-82.
160. Warnes CA, Williams RG, Bashore TM, Child JS, Connolly HM, Dearani JA, et al. ACC/AHA 2008 guidelines for the management of adults with congenital heart disease: a report of the American College of Cardiology/American Heart Association Task Force on practice guidelines (writing committee to develop guidelines on the management of adults with congenital heart disease). *Circulation* 2008;118:e714-833.
161. Cheatham JP, Hellenbrand WE, Zahn EM, Jones TK, Berman DP, Vincent JA, et al. Clinical and hemodynamic outcomes up to 7 years after transcatheter pulmonary valve replacement in the US melody valve investigational device exemption trial. *Circulation* 2015;131:1960-70.
162. McElhinney DB, Hellenbrand WE, Zahn EM, Jones TK, Cheatham JP, Lock JE, et al. Short- and medium-term outcomes after transcatheter pulmonary valve placement in the expanded multicenter US melody valve trial. *Circulation* 2010;122:507-16.
163. Zahn EM, Hellenbrand WE, Lock JE, McElhinney DB. Implantation of the melody transcatheter pulmonary valve in patients with a dysfunctional right ventricular outflow tract conduit early results from the U.S. Clinical trial. *J Am Coll Cardiol* 2009;54:1722-9.
164. Hijazi ZM, Ruiz CE, Zahn E, Ringel R, Aldea GS, Bacha EA, et al. SCAI/AATS/ACC/STS operator and institutional requirements for transcatheter valve repair and replacement, Part III: pulmonic valve. *J Am Coll Cardiol* 2015;65:2556-63.
165. Bergersen L, Benson LN, Gillespie MJ, Cheatham SL, Crean AM, Hor KN, et al. Harmony feasibility trial: acute and short-term outcomes with a self-expanding transcatheter pulmonary valve. *JACC Cardiovasc Interv* 2017;10:1763-73.
166. Zahn EM, Chang JC, Armer D, Garg R. First human implant of the Alterra Adaptive Presept(TM): a new self-expanding device designed to remodel the right ventricular outflow tract. *Catheter Cardiovasc Interv* 2018;91:1125-9.
167. Meadows JJ, Moore PM, Berman DP, Cheatham JP, Cheatham SL, Porras D, et al. Use and performance of the Melody Transcatheter Pulmonary Valve in native and postsurgical, nonconduit right ventricular outflow tracts. *Circ Cardiovasc Interv* 2014;7:374-80.
168. Chung R, Taylor AM. Imaging for preintervention planning: transcatheter pulmonary valve therapy. *Circ Cardiovasc Imaging* 2014;7:182-9.
169. Eicken A, Ewert P, Hager A, Peters B, Fratz S, Kuehne T, et al. Percutaneous pulmonary valve implantation: two-centre experience with more than 100 patients. *Eur Heart J* 2011;32:1260-5.
170. Morray BH, McElhinney DB, Cheatham JP, Zahn EM, Berman DP, Sullivan PM, et al. Risk of coronary artery compression among patients referred for transcatheter pulmonary valve implantation: a multicenter experience. *Circ Cardiovasc Interv* 2013;6:535-42.
171. Fraisse A, Assaidi A, Mauri L, Malekzadeh-Milani S, Thambo JB, Bonnet D, et al. Coronary artery compression during intention to treat right ventricle outflow with percutaneous pulmonary valve implantation: incidence, diagnosis, and outcome. *Catheter Cardiovasc Interv* 2014;83:E260-8.
172. Partington SL, Valente AM. Cardiac magnetic resonance in adults with congenital heart disease. *Methodist Debakey Cardiovasc J* 2013;9:156-62.
173. Holzer RJ, Hijazi ZM. Transcatheter pulmonary valve replacement: State of the art. *Catheter Cardiovasc Interv* 2016;87:117-28.
174. Kenny D, Hijazi ZM, Kar S, Rhodes J, Mullen M, Makkar R, et al. Percutaneous implantation of the Edwards SAPIEN transcatheter heart valve for conduit failure in the pulmonary position: early phase I results from an international multicenter clinical trial. *J Am Coll Cardiol* 2011;58:2248-56.
175. Awad SM, Masood SA, Gonzalez I, Cao QL, Abdulla RI, Heitschmidt MG, et al. The use of intracardiac echocardiography during

- percutaneous pulmonary valve replacement. *Pediatr Cardiol* 2015;36:76-83.
176. Chessa M, Butera G, Carminati M. Intracardiac echocardiography during percutaneous pulmonary valve replacement. *Eur Heart J* 2008;29:2908.
 177. Renella P, Aboulhosn J, Lohan DG, Jonnala P, Finn JP, Satou GM, et al. Two-dimensional and Doppler echocardiography reliably predict severe pulmonary regurgitation as quantified by cardiac magnetic resonance. *J Am Soc Echocardiogr* 2010;23:880-6.
 178. Brown DW, McElhinney DB, Araoz PA, Zahn EM, Vincent JA, Cheatham JP, et al. Reliability and accuracy of echocardiographic right heart evaluation in the U.S. Melody Valve Investigational Trial. *J Am Soc Echocardiogr* 2012;25:383-92.e4.
 179. Silversides CK, Veldtman GR, Crossin J, Merchant N, Webb GD, McCrindle BW, et al. Pressure half-time predicts hemodynamically significant pulmonary regurgitation in adult patients with repaired tetralogy of fallot. *J Am Soc Echocardiogr* 2003;16:1057-62.
 180. Dellas C, Kammerer L, Gravenhorst V, Lotz J, Paul T, Steinmetz M. Quantification of pulmonary regurgitation and prediction of pulmonary valve replacement by echocardiography in patients with congenital heart defects in comparison to cardiac magnetic resonance imaging. *Int J Cardiovasc Imaging* 2018;34:607-13.
 181. Li W, Davlouros PA, Kilner PJ, Pennell DJ, Gibson D, Henein MY, et al. Doppler-echocardiographic assessment of pulmonary regurgitation in adults with repaired tetralogy of Fallot: comparison with cardiovascular magnetic resonance imaging. *Am Heart J* 2004;147:165-72.
 182. Lancellotti P, Tribouilloy C, Hagendorff A, Popescu BA, Edvardsen T, Pierard LA, et al. Recommendations for the echocardiographic assessment of native valvular regurgitation: an executive summary from the European Association of Cardiovascular Imaging. *Eur Heart J Cardiovasc Imaging* 2013;14:611-44.
 183. McElhinney DB, Cheatham JP, Jones TK, Lock JE, Vincent JA, Zahn EM, et al. Stent fracture, valve dysfunction, and right ventricular outflow tract reintervention after transcatheter pulmonary valve implantation: patient-related and procedural risk factors in the US Melody Valve Trial. *Circ Cardiovasc Interv* 2011;4:602-14.
 184. Muller B, Ghawi H, Heitschmidt MG, Fogg L, Hibbeln J, Hijazi ZM, et al. Medium-term CT evaluation of stent geometry, integrity, and valve function of the Edwards SAPIEN transcatheter heart valve in the pulmonary position. *Catheter Cardiovasc Interv* 2016;87:E97-103.
 185. Ahmed S, Johnson PT, Fishman EK, Zimmerman SL. Role of multidetector CT in assessment of repaired tetralogy of Fallot. *Radiographics* 2013;33:1023-36.
 186. Yamasaki Y, Nagao M, Yamamura K, Yonezawa M, Matsuo Y, Kawanami S, et al. Quantitative assessment of right ventricular function and pulmonary regurgitation in surgically repaired tetralogy of Fallot using 256-slice CT: comparison with 3-Tesla MRI. *Eur Radiol* 2014;24:3289-99.
 187. Secchi F, Resta EC, Piazza L, Butera G, Di Leo G, Carminati M, et al. Cardiac magnetic resonance before and after percutaneous pulmonary valve implantation. *Radiol Med* 2014;119:400-7.
 188. Nath J, Foster E, Heidenreich PA. Impact of tricuspid regurgitation on long-term survival. *J Am Coll Cardiol* 2004;43:405-9.
 189. Lee JW, Song JM, Park JP, Lee JW, Kang DH, Song JK. Long-term prognosis of isolated significant tricuspid regurgitation. *Circ J* 2010;74:375-80.
 190. Ohno Y, Attizzani GF, Capodanno D, Cannata S, Dipasqua F, Imme S, et al. Association of tricuspid regurgitation with clinical and echocardiographic outcomes after percutaneous mitral valve repair with the MitraClip System: 30-day and 12-month follow-up from the GRASP Registry. *Eur Heart J Cardiovasc Imaging* 2014;15:1246-55.
 191. Lindman BR, Maniar HS, Jaber WA, Lerakis S, Mack MJ, Suri RM, et al. Effect of tricuspid regurgitation and the right heart on survival after transcatheter aortic valve replacement: insights from the Placement of Aortic Transcatheter Valves II inoperable cohort. *Circ Cardiovasc Interv* 2015;8.
 192. Nickenig G, Kowalski M, Hausleiter J, Braun D, Schofer J, Yzeiraj E, et al. Transcatheter treatment of severe tricuspid regurgitation with the Edge-to-Edge MitraClip Technique. *Circulation* 2017;135:1802-14.
 193. Vismara R, Gelpi G, Prabhu S, Romitelli P, Troxler LG, Mangini A, et al. Transcatheter Edge-to-Edge treatment of functional tricuspid regurgitation in an ex vivo pulsatile heart model. *J Am Coll Cardiol* 2016;68:1024-33.
 194. Shinn SH, Schaff HV. Evidence-based surgical management of acquired tricuspid valve disease. *Nat Rev Cardiol* 2013;10:190-203.
 195. Kay JH, Maselli-Campagna G, Tsuji KK. Surgical treatment of tricuspid insufficiency. *Ann Surg* 1965;162:53-8.
 196. Hahn RT. State-of-the-art review of echocardiographic imaging in the evaluation and treatment of functional tricuspid regurgitation. *Circ Cardiovasc Imaging* 2016;9.
 197. Hahn RT, Zamorano JL. The need for a new tricuspid regurgitation grading scheme. *Eur Heart J Cardiovasc Imaging* 2017;18:1342-3.
 198. Rivera JM, Vandervoort PM, Mele D, Siu S, Morris E, Weyman AE, et al. Quantification of tricuspid regurgitation by means of the proximal flow convergence method: a clinical study. *Am Heart J* 1994;127:1354-62.
 199. Sugeng L, Weinert L, Lang RM. Real-time 3-dimensional color Doppler flow of mitral and tricuspid regurgitation: feasibility and initial quantitative comparison with 2-dimensional methods. *J Am Soc Echocardiogr* 2007;20:1050-7.
 200. Song JM, Jang MK, Choi YS, Kim YJ, Min SY, Kim DH, et al. The vena contracta in functional tricuspid regurgitation: a real-time three-dimensional color Doppler echocardiography study. *J Am Soc Echocardiogr* 2011;24:663-70.
 201. Rodriguez L, Anconina J, Flachskampf FA, Weyman AE, Levine RA, Thomas JD. Impact of finite orifice size on proximal flow convergence. Implications for Doppler quantification of valvular regurgitation. *Circ Res* 1992;70:923-30.
 202. Hahn RT, Meduri CU, Davidson CJ, Lim S, Nazif TM, Ricciardi MJ, et al. Early feasibility study of a transcatheter tricuspid valve annuloplasty: SCOUT trial 30-day results. *J Am Coll Cardiol* 2017;69:1795-806.
 203. Reddy ST, Shah M, Doyle M, Thompson DV, Williams RB, Yamrozik J, et al. Evaluation of cardiac valvular regurgitant lesions by cardiac MRI sequences: comparison of a four-valve semi-quantitative versus quantitative approach. *J Heart Valve Dis* 2013;22:491-9.
 204. Medvedofsky D, Leon Jimenez J, Addetia K, Singh A, Lang RM, Mor-Avi V, et al. Multi-parametric quantification of tricuspid regurgitation using cardiovascular magnetic resonance: a comparison to echocardiography. *Eur J Radiol* 2017;86:213-20.