

指南与标准

美国心脏超声协会临床建议——

各种心血管影像技术在肥厚型心肌病中的应用

由美国心脏核医学学会、心血管磁共振学会和心血管断层扫描学会认可

Sherif F. Nagueh, MD, FASE, Chair,* S. Michelle Bierig, RDCS, FASE,* Matthew J. Budoff, MD,§

Milind Desai, MD,* Vasken Dilsizian, MD,† Benjamin Eidem, MD, FASE,* Steven A. Goldstein, MD,*

Judy Hung, MD, FASE,* Martin S. Maron, MD,‡ Steve R. Ommen, MD,* and Anna Woo, MD,* Houston, Texas;

St. Louis, Missouri; Los Angeles, California; Cleveland, Ohio; Baltimore, Maryland; Rochester, Minnesota;

Washington, District of Columbia; Boston, Massachusetts; Toronto, Ontario, Canada

(J Am Soc Echocardiogr 2011;24:473-98.)

关键词：肥厚型心肌病，超声心动图，核医学成像，心血管磁共振，心脏计算机断层扫描

中文版翻译：中日友好医院 李爱莉 翟亚楠

中文版校对：上海交通大学医学院附属第九人民医院 陈启稚

起草单位：Methodist DeBakey Heart and Vascular Center, Houston, Texas (S.F.N.); St. Anthony's Medical Center, St. Louis, Missouri (S.M.B.); Los Angeles Biomedical Research Institute, Torrance, California (M.J.B.); Cleveland Clinic, Cleveland, Ohio (M.D.); the University of Maryland School of Medicine, Baltimore, Maryland (V.D.); Mayo Clinic, Rochester, Minnesota (B.E., S.R.O.); Washington Hospital Center, Washington, District of Columbia (S.A.G.); Massachusetts General Hospital, Boston, Massachusetts (J.H.); Tufts Medical Center, Boston, Massachusetts (M.S.M.); and Toronto General Hospital, University of Toronto, Toronto,

Ontario, Canada (A.W.).

以下作者与本文没有利益冲突: Sherif F. Nagueh, MD, FASE, S. Michelle Bierig, RDCS, FASE, Matthew J. Budoff, MD, Milind Desai, MD, Vasken Dilsizian, MD, Benjamin Eidem, MD, FASE, Steven A. Goldstein, MD, Judy Hung, MD, FASE, Steve R. Ommen, MD, and Anna Woo, MD.

The following author reported a relationship with one or more commercial interests: Martin S. Maron, MD, serves as a consultant for PGx Health.

索要单行本邮寄地址: American Society of Echocardiography, 2100 Gateway Centre

Boulevard, Suite 310, Morrisville, NC 27560 (E-mail: ase@asecho.org). Writing Group of the

*American Society of Echocardiography (ASE) †American Society of Nuclear Cardiology, ‡

Society for Cardiovascular Magnetic Resonance, and §Society of Cardiovascular Computed

Tomography. 0894-7317/\$36.00

ASE版权所有

doi:10.1016/j.echo.2011.03.006

目录

缩略语

写作小组和证据审查

1. 前言

2. 超声心动图

A. 心脏结构

- B. 左心室收缩功能评估
- C. 左心室舒张功能评估
- D. 动力性梗阻和二尖瓣异常
- E. 肥厚型心肌病的二尖瓣反流
- F. 心肌缺血、纤维化和心肌代谢
- G. 引导室间隔减容术
 - i. 肌切除术
 - ii. 室间隔酒精消融
 - iii. 永久起搏
- H. 筛查和临床前诊断

3.核素显像

- A. 心脏结构
- B. 放射性核素显像评估左室收缩功能
- C. 放射性核素显像评估左室舒张功能
- D. 动力性梗阻和二尖瓣异常
- E. 肥厚型心肌病的二尖瓣反流
- F. 心肌缺血、纤维化和代谢
 - i. SPECT
 - ii. 正电子发射断层成像（PET）
 - iii. 代谢显像
- G. 引导室间隔减容术

H. 筛查和临床前诊断

3.心血管磁共振成像

A. 心脏结构

B. 左心室收缩功能评估

C. 左心室舒张功能评估

D. 动力性梗阻和二尖瓣异常

E. 肥厚型心肌病的二尖瓣反流

F. 心肌缺血、纤维化和代谢

i. 缺血

ii. 纤维化

iii. 代谢

G. 引导室间隔减容术

H. 筛查和临床前诊断

4.心脏断层扫描（CT）

A. 心脏结构

B. 左心室收缩功能评估

C. 左心室舒张功能评估

D. 动力性梗阻和二尖瓣异常

E. 肥厚型心肌病的二尖瓣反流

F. 心肌缺血、纤维化和代谢

G. 引导室间隔减容术

- H. 筛查和临床前诊断
- 5. 儿童肥厚型心肌病影像学
- 6. 影像学在肥厚型心肌病鉴别诊断中的作用
- 7. 临床应用推荐
 - A. 心脏结构
 - B. 左心室收缩和舒张功能评估
 - C. 左室流出道梗阻评估
 - D. 接受侵入性治疗患者的评估
 - E. 肥厚型心肌病患者冠状动脉疾病的诊断
 - F. 筛查
 - G. 影像学在识别猝死高危患者中的作用

写作小组和证据审查

写作组包括肥厚型心肌病（HCM）方面的资深专家。文中的图像代表美国超声心动图学会（ASE），美国心脏核医学学会，心血管磁共振学会和心血管断层扫描学会。文件经 ASE 指南和标准委员会成员，及 4 位由美国心脏核医学学会，心血管磁共振学会，心血管断层扫描学会和美国心脏学院基金会提名的官方评审专家审查。

本文的目的是回顾当前各种影像技术的优势，对应用这些技术优化 HCM 患者的管理提出推荐指南。这些建议是基于观察性研究，部分入选病例较少，以及写作组成员的临床经验，缺乏多种影像方法之间的比较研究。虽然写作组作了这些推荐，但我们认为必须个体化地选择具体影像学方法。

1. 简介

HCM 是最常见的基因相关性心肌病，分布于多个地域及种族，其发病率约为 0.2%¹。

HCM 以常染色体显性模式遗传。多数患者的自然病程是良性的，预期寿命与正常人相仿。但部分患者可出现不良结局：包括心源性猝死、由左室流出道动力性梗阻和/或舒张充盈异常导致的活动受限、心房颤动及左室收缩功能不全¹。

临床诊断 HCM 的依据是：存在明显的左室肥厚，却无法用其他疾病合理解释¹。很多病人是由于发现了心脏杂音或心电图异常去做超声心动图评估时被意外诊断的。其他一些病人会出现呼吸困难、胸痛和/或晕厥症状。每年约 1% 的 HCM 患者发生心源性猝死，而如何发现存在心脏猝死风险的 HCM 患者，是最具挑战的临床问题之一。目前，根据每个病人的具体情况，其中包括一系列临床危险因素的评估，及影像检查的结果，可以帮助每个患者决定是否适合安装植入性心脏除颤器（ICD）¹。

对 HCM 潜在解剖结构和病理生理的全面了解，是做好 HCM 患者管理的基础。此外，仔细评估伴随的结构性心脏病是选择合适病人做进一步治疗的关键。

可以采用多种影像手段来评估心脏结构和功能，如：是否存在动力性梗阻及梗阻的严重程度，是否存在二尖瓣异常，二尖瓣反流的严重程度，心肌缺血、纤维化及心肌代谢情况。另外，影像学可以用来指导治疗，进行筛查和临床前诊断，并可用于发现拟表型患者。

2. 超声心动图

A. 心脏结构

超声心动图可以很好地明确左室容积和心肌肥厚模式。（图 1，视频 1，[点击网址观看视频](#)，表 1）。HCM 心室容积通常为正常或轻度减低。习惯上，应用双平面 Simpson's 法测量左室容积和射血分数（EF）。近年发展的实时三维（3D）超声心动图，可以提供更准确的定量方法，但在评价 HCM 的准确性方面尚缺乏数据。应通过所有的图像声窗来精确确定室壁增厚的范围。与舒张末期厚度正常的心肌节段相比，肥厚节段通常回声轻度增强。

左室壁肥厚虽然通常呈非对称性，但亦可能是对称的。肥厚心肌可以以任何形式分布于任何部位，包括右室。虽然肥厚较常见于室间隔，但也可单独累及左室游离壁和心尖（图 1）。局限于前侧壁的心肌肥厚容易被漏诊，必须在扫查及解读图像时特别注意。当肥厚范围不清晰时，应高度怀疑并仔细观察左室心尖部是否有肥厚，并可应用经静脉左心声学造影帮助明确诊断（视频 2 和 3[[点击网址观看视频](#)]）。特别需要指出的是，如无左心声学造影辅助，心尖 HCM 和心尖部室壁瘤很容易被漏诊。当怀疑 HCM 患者存在心尖肥厚时，需做经胸超声心

动图（transthoracic echocardiography, TTE）并注射超声对比剂来确定肥厚程度，明确是否存在心尖室壁瘤和血栓。用半定量评分表示肥厚的严重程度是可行的，这种评分以二维胸骨旁短轴切面下测量的舒张末室壁厚度为基础。如图像质量很好，并有专家解读时，三维超声心动图是定量左室质量最精确的超声学方法。

B: 左心室收缩功能评价

HCM 患者左室射血分数通常正常或增高，所有影像学检查中都应评估收缩功能。需注意的是，HCM 患者如心肌肥厚严重，其左室舒张末期容积可能较小，此时尽管 EF 正常，每搏输出量依然是降低的。HCM 患者 LVEF 如 $<50\%$ ，通常定义为显著的左室收缩功能不全，这种情况仅发生于少数患者（2%-5%），被称为“扩张性或进展性 HCM”、“HCM 终末期”或者“HCM 耗竭”。一旦出现左室收缩功能不全，预后明显变差⁷。同样，心尖部室壁瘤也不常见，但却是超声造影易于诊断的严重并发症⁸。

除了二维和三维超声心动图，多普勒方法已被用来评估是否存在亚临床左室收缩功能异常。组织多普勒可于收缩期和舒张期测量心肌运动速度。在明显的心肌肥厚出现之前可以发现收缩期 Sa 减低和舒张早期 Ea（或 e'）速度减低⁹⁻¹⁰。组织多普勒还可用于测定心肌应变和应变率，这些指标与组织多普勒速度不同，一般不受心脏转动和周围心肌牵拉的影响。应变率有助于鉴别非梗阻性 HCM 与高血压所致的左室肥厚¹¹。但是，通过组织多普勒得到的应变图像因其角度依赖性而存在技术局限。斑点追踪超声心动图（speckle-tracking echocardiography, STE）直接通过二维图像评价心肌运动，对超声束和运动平面的夹角没有依赖。一些研究已表明，与正常人比较，HCM 患者的二维应变减低^{12,13}（图 2 和图 3）。关于径向运动，STE 可以定量评价心脏扭转运动。从心尖角度观察正常人的心脏扭转运动，基部呈顺时针方向旋转，而心尖部呈逆时针方向旋转，其合力使左室产生了“拧毛巾式”的运动。总体而言，HCM 患者的心脏旋转和解旋速度与对照组相似，但也存在个体差异（图 4）。HCM 患者心脏旋转的程度虽然是正常的，但旋转的方向可能与正常人存在差异。比如，HCM 患者左室中部旋转呈顺时针方向，与正常人相反¹³。

尽管 STE 是一种有前景的评估心肌功能的方法，但正常人左室 17 个节段的应变值之间存在显著差异。故有必要研究不同节段心肌应变的正常值范围。目前尚不推荐常规应用 STE。

C. 左心室舒张功能评价

不论左室肥厚存在与否、程度如何，HCM 患者都存在左室和左房充盈异常。二尖瓣及肺静脉血流速度与有创的左室舒张功能参数间相关性较弱，因而在评价 HCM 患者左室舒张功能中的作用有限^{14,15}。但是，肺静脉血流频谱中的心房反向波速度及其持续时间（图 5）与左室舒张末压显著相关¹⁵。

以往的研究已发现， E/e' 与左室充盈压存在一定相关¹⁵。这种相关性所适用的瓣环速度范围很广，包括侧壁瓣环 e' 速度 $>8\text{cm/s}$ 都适用（图 5，图 6）。最近研究发现，HCM 患者左室松弛功能严重受损与瓣环速度显著减低中等相关。 E/e' 比值还与成人¹⁷和儿童 HCM 患者的运动耐量相关¹⁸。此外，研究显示儿童 HCM 患者间隔的 e' 速度是死亡和室性心律失常的独立预测因子¹⁹。

推荐采用综合方法预测 HCM 患者的左室充盈压¹⁹，参照上文提到的速度和比值，同时考虑肺动脉压力和左房容积，特别是当患者无严重二尖瓣反流和心房颤动时。严重二尖瓣反流和心房颤动可导致左房扩大，但左房压可以正常。

左房大小是 HCM 患者重要的预后信息²⁰⁻²²。疾病初期 HCM 患者的左房扩大是多因素的，其中二尖瓣反流严重程度、是否存在舒张功能不全以及可能存在的心房肌病变都起到了重要作用¹。由于左房容积在评价左房大小方面更准确，因此根据 ASE 指南，应该评估经体表面积校正的左房容积指数²。

左心房有3个主要机械功能：（1）储器功能（心室收缩期和等容舒张期），（2）管道功能（舒张早期），以及（3）收缩（增压泵）功能（心房收缩期）。可通过多普勒超声心动图测量肺静脉血流信号，或在不同心房时相应用二维和三维超声心动图测量左房容积¹⁹，从而间接评价左房功能。其它对左房功能的间接测量包括计算左房射血力和动能，这些参数在梗阻性HCM患者中增加，梗阻解除后下降（即使未达到正常）²³。

左房应变可以更直接地评价左房功能。可用组织多普勒和二维应变评价 HCM 患者心房三个时相的左房长轴应变²⁴。HCM 患者左房 3 个时相的应变值均显著低于继发性左室肥厚患者。通常 2D 心房应变与组织多普勒应变相比，重复性更佳且更省时，但目前并未推荐常规临床应用。

D. 动力性梗阻和二尖瓣异常

HCM 患者的原发性二尖瓣装置异常包括：乳头肌肥大导致的乳头肌前移、先天性二尖瓣面积增加和瓣叶延长^{25,26}。另外，二尖瓣装置异常使瓣叶在高动力 EF 的牵引力下向 LVOT 移位²⁷。这会导致二尖瓣或腱索的收缩期前向运动（systolic anterior motion, SAM），这是梗阻性 HCM 二尖瓣异常的特征性表现。值得注意的是，严重的梗阻常来自于瓣膜的 SAM，而不是腱索的 SAM。SAM 被定义为收缩期二尖瓣叶移位，进入 LVOT（图 7），导致湍流，彩色多普勒显示为五彩镶嵌的血流。SAM 征还会使二尖瓣叶对合变形导致二尖瓣反流（图 7）。通过连续波多普勒测量 LVOT 处的峰值速度，可以测得最大瞬时压差，用于反映 LVOT 梗阻的严重程度。测量时要仔细避免将 LVOT 信号与二尖瓣反流束信号相混杂（图 8）。

鉴别动力性的 LVOT 压力阶差和由瓣下隔膜导致的固定性 LVOT 梗阻很重要。此外，需要检查主动脉瓣结构以排除伴随的主动脉瓣狭窄，如有需要可作经食管超声心动图（transesophageal echocardiography, TEE）检查，应用脉冲波多普勒在瓣环处测量，要特别注意观察收缩早期，主动脉瓣会因 LVOT 的梗阻而表现为瓣叶提前关闭或震颤。考虑 TEE 检查的另一个重要原因是需要排除存在固定梗阻的 LVOT 疾病，如隔膜。这类疾病可经外科手术纠正，故需仔细筛查。TTE 检查时可能发现的存在瓣下狭窄的有用线索包括：连续多普勒（continuous-wave Doppler, CW）测得的与主动脉瓣狭窄相似的 LVOT 频谱早期达峰以及主动脉瓣反流，而未进行外科心肌切除术的 HCM 患者主动脉反流是不常见的。

心室中部梗阻，伴或不伴 LVOT 梗阻，在高动力状态和/或对称性肥厚时均可发生。这种现象在有乙状间隔的老年患者中经常可以看到。脉冲波多普勒可测定梗阻位置，彩色多普勒可显示梗阻部位的高速血流（脉冲波多普勒出现速度混叠）。LVOT 梗阻是导致梗阻性 HCM 动力性收缩功能异常的原因，表现为收缩中期 LVOT 入口处射血速度下降及长轴应变减低，此 2 点在解除梗阻后可得到改善²⁷。

其他一些异常亦可导致 SAM 征，如乳头肌前向移位及二尖瓣后叶牵制力的降低。体内体外二尖瓣模型研究，通过模拟梗阻性 HCM 的乳头肌前向移位，其结果都强调了这些机制的重要性²⁸。乳头肌前向移位使二尖瓣前叶漂移接近 LVOT，并导致腱索和瓣叶松弛。由于左室产生的牵拉力拉动前向位移，并使瓣叶在收缩早期伸长至流出道，瓣叶远端 1/2 至 1/3

形成前向夹角插入 LVOT，形成了由两个瓣叶组成的“漏斗”（图 7）。由于前叶相对于后叶前移更明显，故前叶与后叶之间的结合点呈典型的偏心性。

造成 SAM 征的牵引力在产生 LVOT 压力阶差中起重要作用。间隔肥厚的程度及其导致的 LVOT 狭窄也对 LVOT 压差起作用。除了左室收缩造成对二尖瓣叶的牵引，当血流进入狭窄的 LVOT 时，产生的 Venturi 效应也可能是导致梗阻的原因。但是 SAM 常常在主动脉瓣开放之前出现，那时 LVOT 的血流速度较低²⁷。而且，LVOT 多普勒血流速度在 SAM 开始时与正常人流出道的速度并无差别。这表明虽然 Venturi 效应在流出道是存在的，但并不是导致 SAM 的主要因素。正是由于超声心动图证实了牵引力在 SAM 成因中的重要性，出现了肌切除术的改良，切除部位延伸到超过二尖瓣瓣尖，并且在一些病例可达乳头肌基底部。

乳头肌的异常插入包括 1 个或 2 个乳头肌的头部直接插入（没有腱索）到二尖瓣瓣叶的心室面，这在 HCM 患者发生率可达 13%，并在 VOT 梗阻中起作用（图 9，视频 4，点击在线观看视频）。非常规切面更易识别这些异常，如瓣膜的病理结构不能被辨别要考虑应用 TEE。超声心动图报告应该包括关于乳头肌大小（如果存在肥厚）的清晰描述，以及是否直接插入二尖瓣叶导致 LVOT 梗阻。

E. HCM 患者的二尖瓣反流

SAM 征时，由于二尖瓣前叶运动大于后叶，瓣叶间产生缝隙，导致指向后方的二尖瓣反流束，反流可以是显著的（中度或以上，取决于缝隙的大小）。前叶表面积较大，更冗长更易移动，所以后叶向流出道的位移不如前叶明显，导致两个瓣叶间产生了缝隙²⁵。二尖瓣反流程度与前、后叶对合不匹配的长度以及后叶前向运动能力降低相关²⁹。对合不匹配可以通过测量两个瓣叶接合部的长度定量评估，如上文所示，后叶异常时瓣叶接合长度缩短。动力性梗阻也影响二尖瓣反流的严重程度³⁰，这种反流是动力性的，其影响因素与影响梗阻程度的因素相同。

并非所有 HCM 伴发的二尖瓣反流都与 SAM 现象有关。HCM 患者可同时存在瓣膜本身的异常，比如二尖瓣脱垂，或继发于反复与间隔接触或是湍流束冲击导致的瓣叶增厚、腱索断裂、腱索延长或增厚和感染³⁰。重要的是，当发现中心性的或朝向前方的反流束时，需要立即仔细评估二尖瓣装置，并通过 TEE 来确定瓣膜本身的异常。

还有一些特殊的情况，比如在手术室或重症监护病房，一些病理生理情况可导致类梗阻性 HCM。例如，室间隔基底部肥厚或乙状间隔的患者进行二尖瓣粘液变性修复术后，因脱离体外循环导致左心室充盈不完全。这种情况下，如合并某些因素，如延长的二尖瓣叶、较窄的 LVOT、较小的左心腔以及高动力性的 EF，就可出现 SAM 现象和 LVOT 梗阻。通常，补充容量、增加后负荷及停止正性肌力药物后这种情况可以逆转。同样，SAM 与动力性梗阻可以出现于应用正性肌力药物的容量不足患者、室间隔基底部肥厚的老年人、或作为应激性心肌病临床表现的一部分。

F. 心肌缺血、纤维化和心肌代谢

通常超声心动图在诊断 HCM 心肌缺血方面作用局限。大面积局灶性纤维化可以导致节段性功能减低，表现为心肌应变减低。但应变减低也可出现于无纤维化的心肌节段，因此降低了诊断的特异性。

经胸超声心动图测量左前降支的冠脉血流储备是可行的。异常的血流储备可由大血管和微血管的冠脉病变（CAD）所致。这项技术需要经验，且血流储备异常对心外膜冠脉病变的阳性预测价值较低。目前超声心动图尚无法研究心肌代谢。

G. 超声心动图引导室间隔减容术

i. 外科心肌切除术：经胸途径以及心脏的空虚状态妨碍了在肌切除术时直接观察心脏，有可能会造成切除程度的不精确。这些局限性会导致或是切除不充分，术后仍存在持续 LVOT 梗阻，或是切除太多，造成室间隔缺损和/或完全性心脏传导阻滞。因此，术中 TEE 已经成为外科心肌切除术必需的辅助手段，可以帮助制定外科手术方案，明确切除是否充分，并发现并发症。

随着术中 TEE 的应用，间隔心肌切除术的安全性和有效性有所改善，TEE 能为外科医生提供间隔解剖和几何形态的路线图^{25,30,31}。TEE 获得的重要信息包括：间隔的最大厚度（图 10），从主动脉瓣瓣环至间隔最厚处的距离，心内膜纤维性斑块的位置（摩擦或冲击损伤病变），以及间隔隆起向心尖延伸的长度。而且，TEE 还可以很好地识别功能性和固有的二尖

瓣异常。重要的是，TEE 可确定二尖瓣的异常并指导必要的修复或瓣膜置换³²。尤其 TEE 能够更清晰地确定乳头肌是否直接插入二尖瓣前叶中间或基底部。外科技术已可以处理这种病理改变，并且避免术后残留梗阻，术式包括松解并选择性切除异常的乳头肌连接。部分来外科治疗的患者二尖瓣叶非常冗长，对于这些患者，二尖瓣前叶折叠术可成功地抑制 SAM 现象。经术前超声心动图证实，且术中直接观察到二尖瓣叶非常冗长的病例，水平前叶折叠术已经成为一种安全有效的技术，可减少瓣叶的长度和松弛性，使瓣叶变硬以抵抗变形。停用体外循环后，需即刻复查 TEE 以评价是否存在残留梗阻，或轻度以上的二尖瓣反流，以便决定是否进行进一步的切除或修复。

手术也可出现不常见的并发症，包括医源性的室间隔缺损，通过 TEE 发现后马上可以修复。主动脉瓣反流（通常是轻度的）也可能发生，确切的机制还不清楚，可能是由于手术对瓣叶的直接损伤，或者起始肌切除术的部位太靠近右冠窦使瓣环不稳定所致³²。

ii. 酒精间隔消融

当药物治疗失败或患者无法耐受手术时，酒精间隔消融可作为外科手术的替代。此技术指的是注射酒精到间隔近端的前降支穿隔支，阻断血流，使肥厚的室间隔近段心肌局部梗死（图 11）。应用心肌声学造影（myocardial contrast echocardiography, MCE），向目标血管注射超声造影剂，以显示单支穿隔动脉的灌注范围，是间隔消融术的重要修正环节之一，并且是手术成功的关键。手术成功的标志是术后 LVOT 压差下降>50%（图 12，表 12）。

穿隔支的数量、大小以及血管供血区域有很大的个体差异，因此确定哪支或是哪些血管接受酒精注射是非常重要的。最初确定靶血管的方法是在球囊充气时评估 LVOT 压差降低的水平。但目前大多数中心已用术中经胸或经食管超声心动图引导下的心肌声学造影取代^{33,34}。

确定靶血管并建立通路后，将球囊导管插入血管并充气阻断血流。然后在超声连续成像同时注入 1-2cm³ 稀释的超声对比剂（如 Definity, Optison, Levovist），并用 1ml-2ml 生理盐水冲洗。声学对比剂要用普通生理盐水稀释以达到最佳的心肌增强效果并减少衰减⁸。具体稀释方法各种造影剂有所不同。也可以用振动放射成像造影剂代替超声造影剂³。最佳的基底部分隔消融区域还应包括二尖瓣与室间隔接触部位的最大血流加速区。典型情况下，MCE 可在室间隔基底部显示回声密度增高区域并产生声影。此外很重要的一点是，此时远离消融靶区域较远的心肌节段要没有造影剂灌注，包括左室前壁、右室游离壁和乳头肌。

在应用术中 MCE 之前，酒精间隔消融术后压力阶差下降不满足的主要原因是消融（瘢痕化）部位不理想。应用术中 MCE 可能改变靶血管的选择³⁵，甚至因为条件不佳而放弃酒精消融。部分病人也许更适合外科手术，如靶间隔支同时也为乳头肌供血，或者插管进入靶间隔支失败。

大多数中心应用TTE作术中引导。推荐经多个切面，包括心尖四腔和三腔切面、胸骨旁短轴和长轴切面确认造影增强的靶区域和非靶区域。TTE的局限性包括：操作过程中很难连续监测、患者需取仰卧位会导致图像质量不理想。某些团队更愿意用TEE，因为通常TEE图像质量更佳。但TEE通常需要全身麻醉，这可能改变负荷条件而影响LVOT压差。如果应用TEE，应扫查心尖四腔切面（深部胃底水平，0°）和长轴切面（食管中部，主动脉瓣水平，120-130°），可能还需经胃的短轴切面做补充，以评价乳头肌或可能存在的右室灌注³⁶。TEE测量腔内压差时是有用的，虽然它通常比TTE更具挑战性。已有初步数据表明腔内成像在间隔消融中的作用³⁷。腔内成像可提供高质量的近场图像，并且可由心脏介入专家操作。由于LVOT本身解剖结构的复杂性，3D超声心动图可提供更多信息。但尚未确定酒精消融术中应用3D TEE技术 是否存在额外益处。

术中超声心动图对评估手术效果也是有益的^{36, 38}。酒精灌注造成间隔基底部区域梗死，其特征性表现为回声增加，还会出现厚度和位移的减小。如果二尖瓣反流是由SAM现象所致，消融后反流通常会减轻或消除³⁸。更重要的是，动力性梗阻应消除或减少。

iii. 永久起搏器

对大多数流出道梗阻的病人，起搏器已不是首选治疗，但在部分病人中可能是有用的，而对那些室间隔减容治疗后继发高度房室传导阻滞的病人则是必需的。起搏器置入术中很少需要超声心动图引导。但如需明确右室导线是否定位于右室心尖部，或担心穿孔时，则需要进行TTE检查³⁹。超声心动图在评价和随访治疗效果、优化房室延迟时间方面是很重要的³⁹。

H. 筛查和临床前诊断

目前，超声心动图是筛查HCM最实用的技术。大多数心肌肥厚的活跃期似乎是青年期，

但也存在迟发的心肌肥厚（50或60岁时）。因此指南推荐青年期每12个月，成人每5年，或在出现与HCM相关症状时应作定期筛查⁴⁰。检查中应仔细检查所有心肌节段是否存在肥厚，而不仅限于室间隔。超声图像不清晰，或心电图提示异常但超声心动图结果正常的患者应推荐进行心脏磁共振检查。

转基因动物研究发现：心肌肥厚出现之前，心肌功能的异常已存在⁴¹。基于此发现，有研究应用组织多普勒成像对携带编码HCM肌蛋白突变的个体进行临床前诊断。一些研究已经表明瓣环e'速度是有希望的指标^{9,10,42}，另一研究表明a'速度在HCM临床前期异常减低⁴³。这些研究的局限性在于：在老年人群或同时合并其他疾病的患者中特异性较差。此外，很难对那些携带突变基因但速度指标仍然正常的个体解释其多普勒数据并提供咨询。由于多变的外显率，这些个体也许永远不会发展为HCM，包括心肌功能异常。或者也可能其心脏功能的异常确实存在，但程度较轻不能通过心肌影像学来诊断。因此，多普勒速度的异常不能诊断HCM，但可以帮助确定基因携带者，使他们从密切随访中受益。

附：473-483页图表

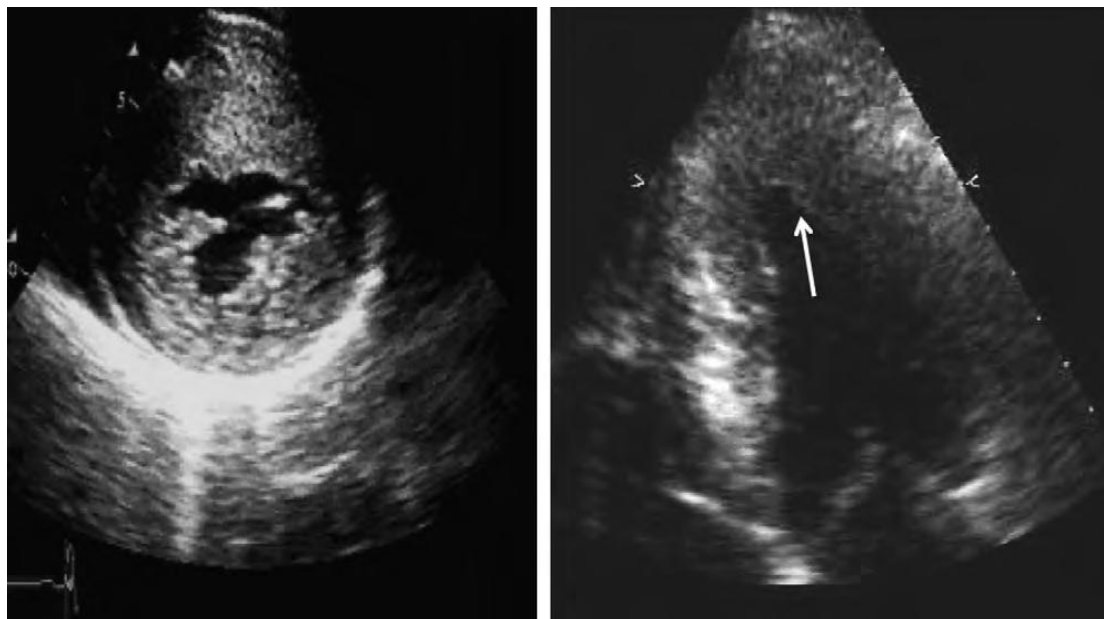


图1 (左) 胸骨旁短轴切面显示重度非对称性HCM累及前间隔及前侧壁。(右) 心尖四腔心切面显示心尖部HCM。箭头提示远端侧壁肥厚。

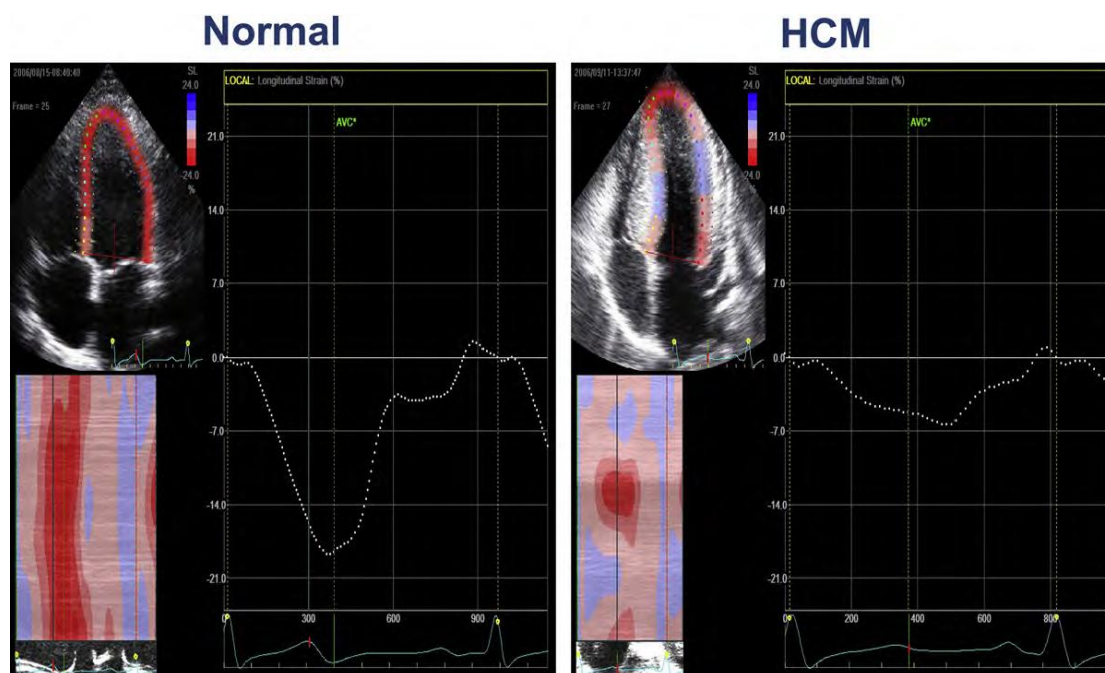


图2 STE获得的左室整体纵向应变。左：对照组；右：HCM伴左心室高动力。HCM患者左室整体应变显著减低7%。AVC，主动脉瓣关闭。

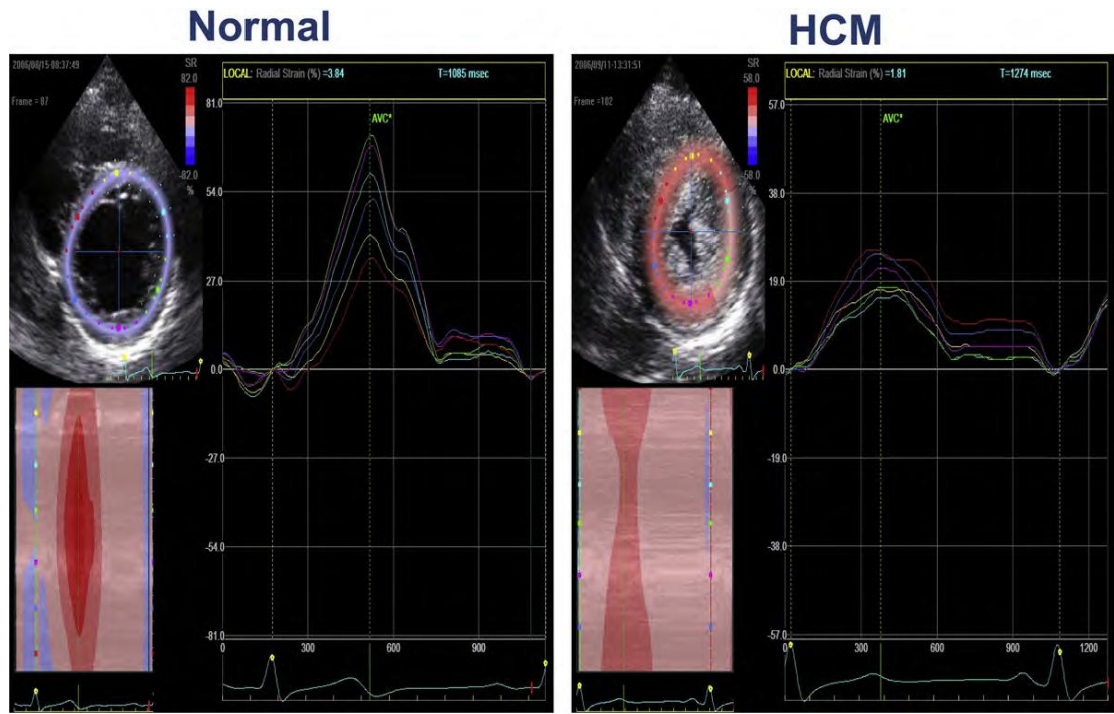


图3 STE获得的左室短轴六个心肌节段径向应变。左：对照组；右：HCM伴左心室高动力。HCM患者所有六个心肌节段的径向应变都显著减低。AVC，主动脉瓣关闭。

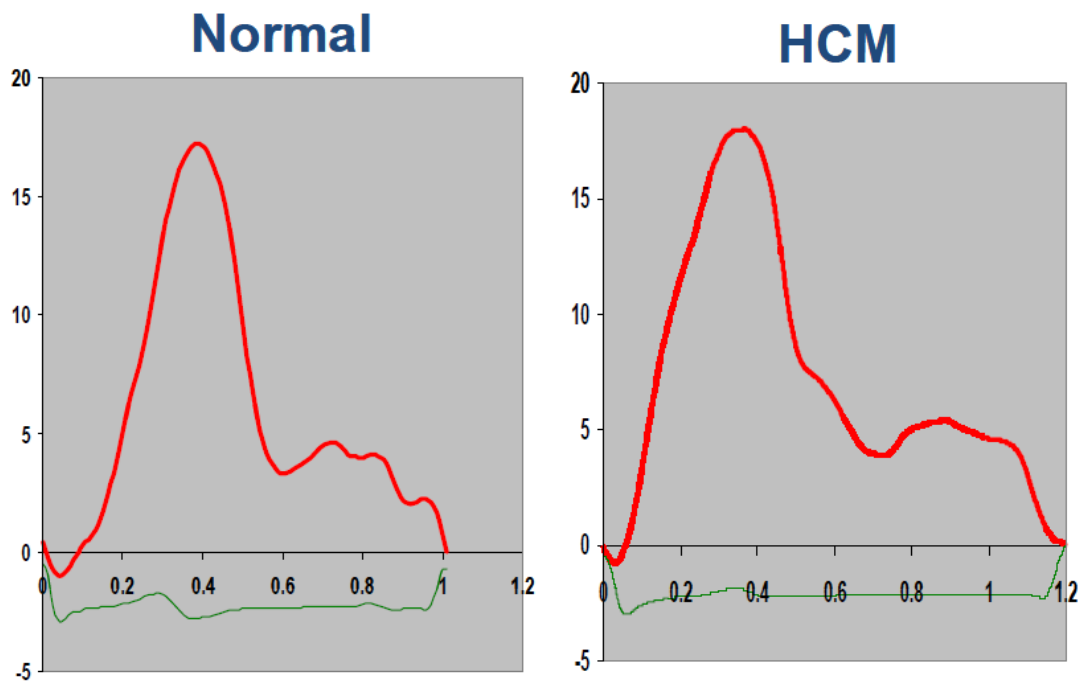


图4 STE获得的扭转曲线。左：对照组；右：HCM。均表现为先顺时针旋转后逆时针旋转 17° 。

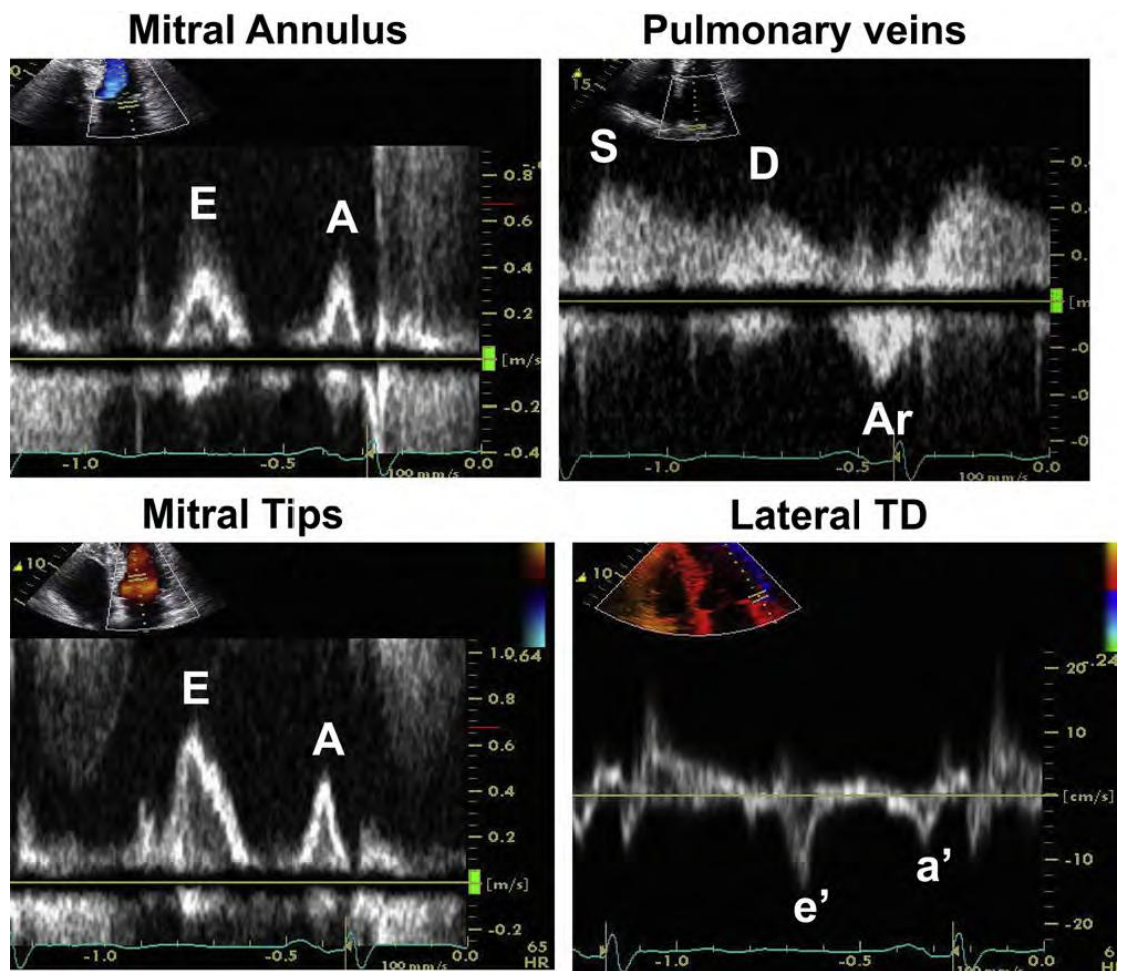


图5，左室舒张末压升高但左房压正常HCM患者的左室舒张功能评估。二尖瓣血流显示二尖瓣环水平二尖瓣A峰持续时间缩短，而肺静脉血流频谱Ar峰速度加快且持续时间延长。二尖瓣环侧壁e'速率正常，E峰峰值速度（二尖瓣尖水平）/e'的比值<8，左房压力正常。（右）组织多普勒（TD）速度，A，二尖瓣舒张晚期速度；a'，舒张晚期TD速度；Ar，肺静脉心房反转信号；E，二尖瓣舒张早期速度；e'，舒张早期TD速度；D，肺静脉舒张期速度；S，肺静脉收缩期速度

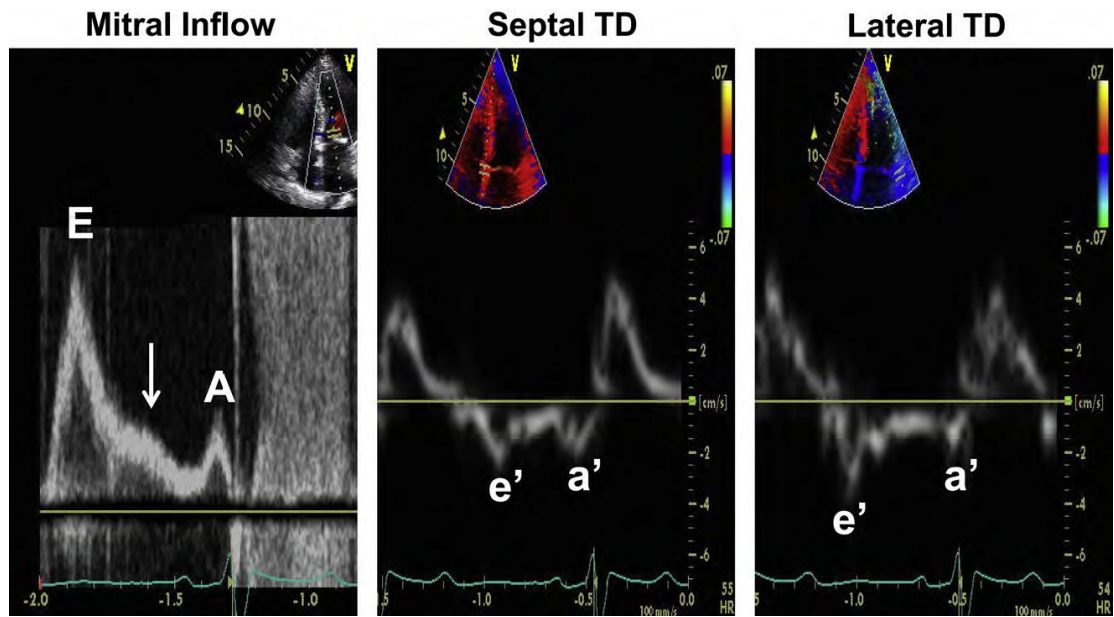


图6 左房压升高的HCM患者的左室舒张功能评估。二尖瓣血流显示限制型血流频谱形态（E峰速度，140cm/s）。箭头所指为舒张中期的L速度，于松弛受损和充盈压升高时可见。侧壁和室间隔瓣环TD速度（包括e'和a'）显著减低，与左室松弛严重受损相关。左房压力>20mm Hg时E/e'速度比值显著增加。二尖瓣A峰速度减低及减速时间缩短、严重减低的a'速度与左室舒张末期压力增高有关。A，二尖瓣舒张末期峰值速度；a'舒张末期TD速度；E，二尖瓣舒张早期峰值速度；e'，舒张早期TD速度。

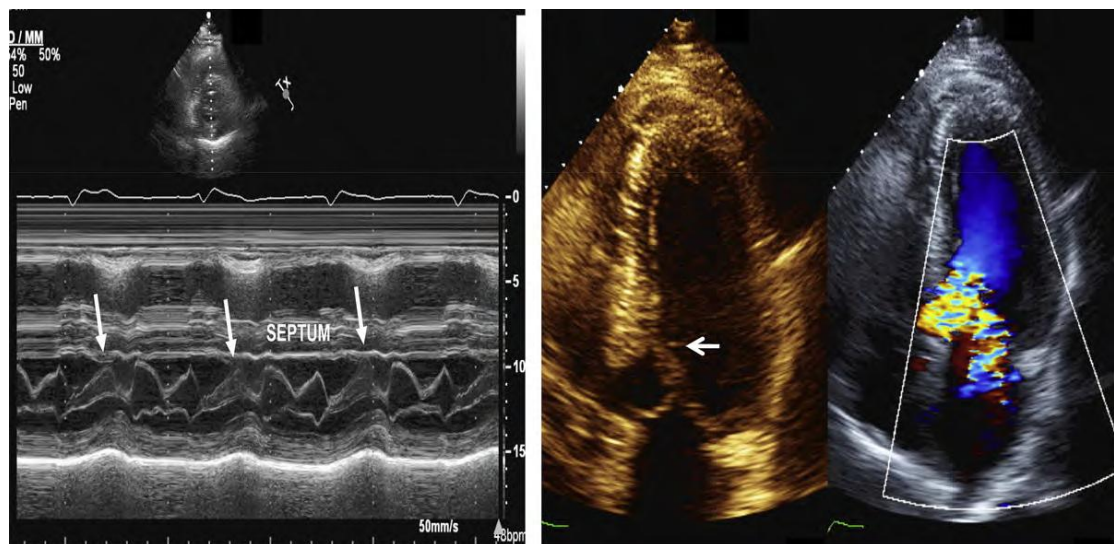


图7 （左） M型显示的SAM征和二尖瓣叶接触室间隔（箭头）。（右）二维超声心动图显示SAM征（箭头）。同一切面，彩色多普勒显示LVOT彩色镶嵌的高速血流信号及指向后侧壁的二尖瓣偏心反流信号。

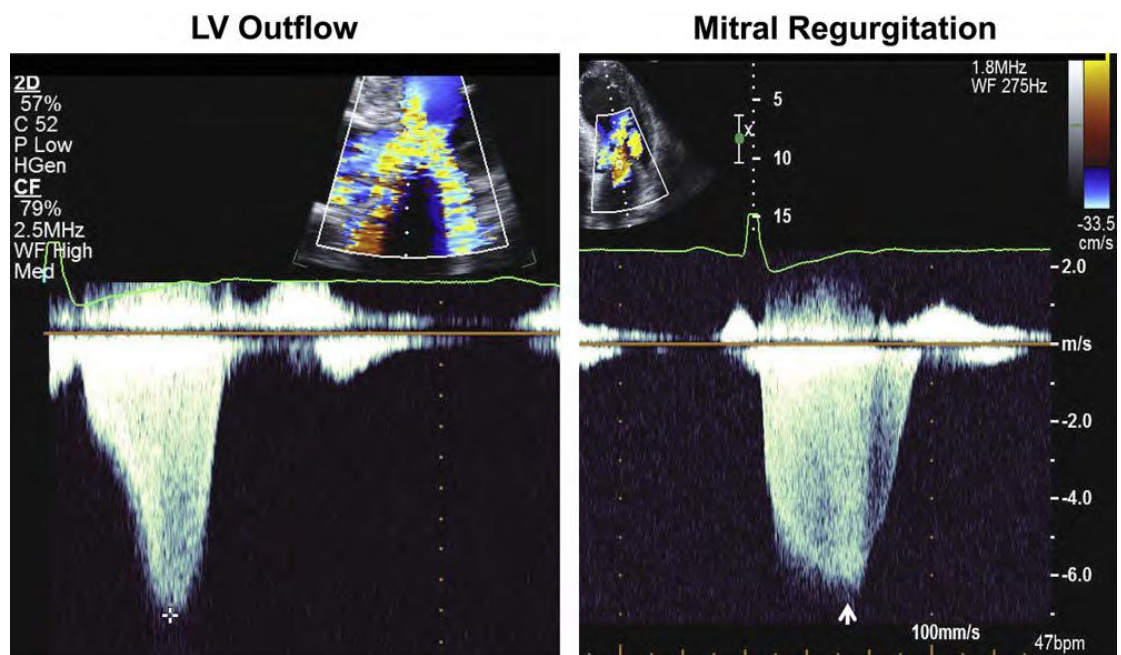


图8 连续多普勒（CW）显示左室流出道峰值速度（十字：4.5m/s）（左）和二尖瓣反流峰值速度（箭头：6.3m/s）（右）。连续多普勒频谱凹面向左的血流束，导致收缩期左室流出道节流面积减小，二尖瓣更贴近室间隔。这种CW频谱形态有助于左室流出道动力性梗阻与二尖瓣反流及主动脉瓣狭窄的鉴别。

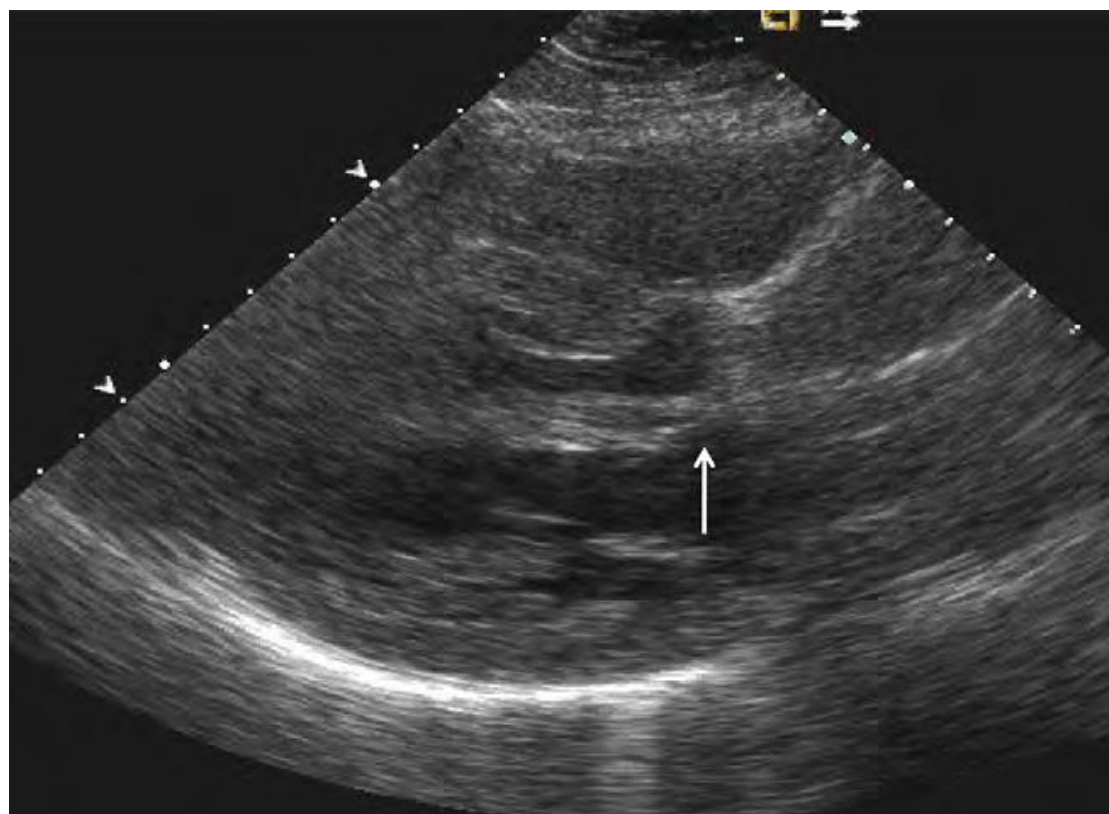


图9 乳头肌插入异常，乳头肌直接插入二尖瓣前叶（箭头）。

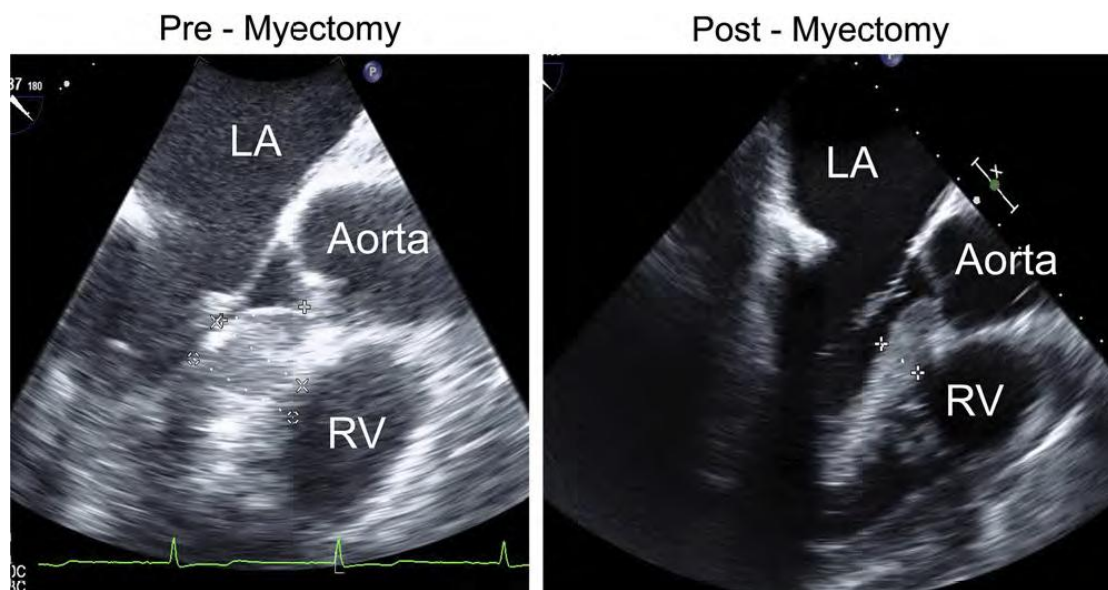


图10 TEE测量的室间隔厚度。左：室间隔切除术前（厚2.9cm）；右：切除术后（厚1.5cm）。
LA，左心房；RV，右心室。

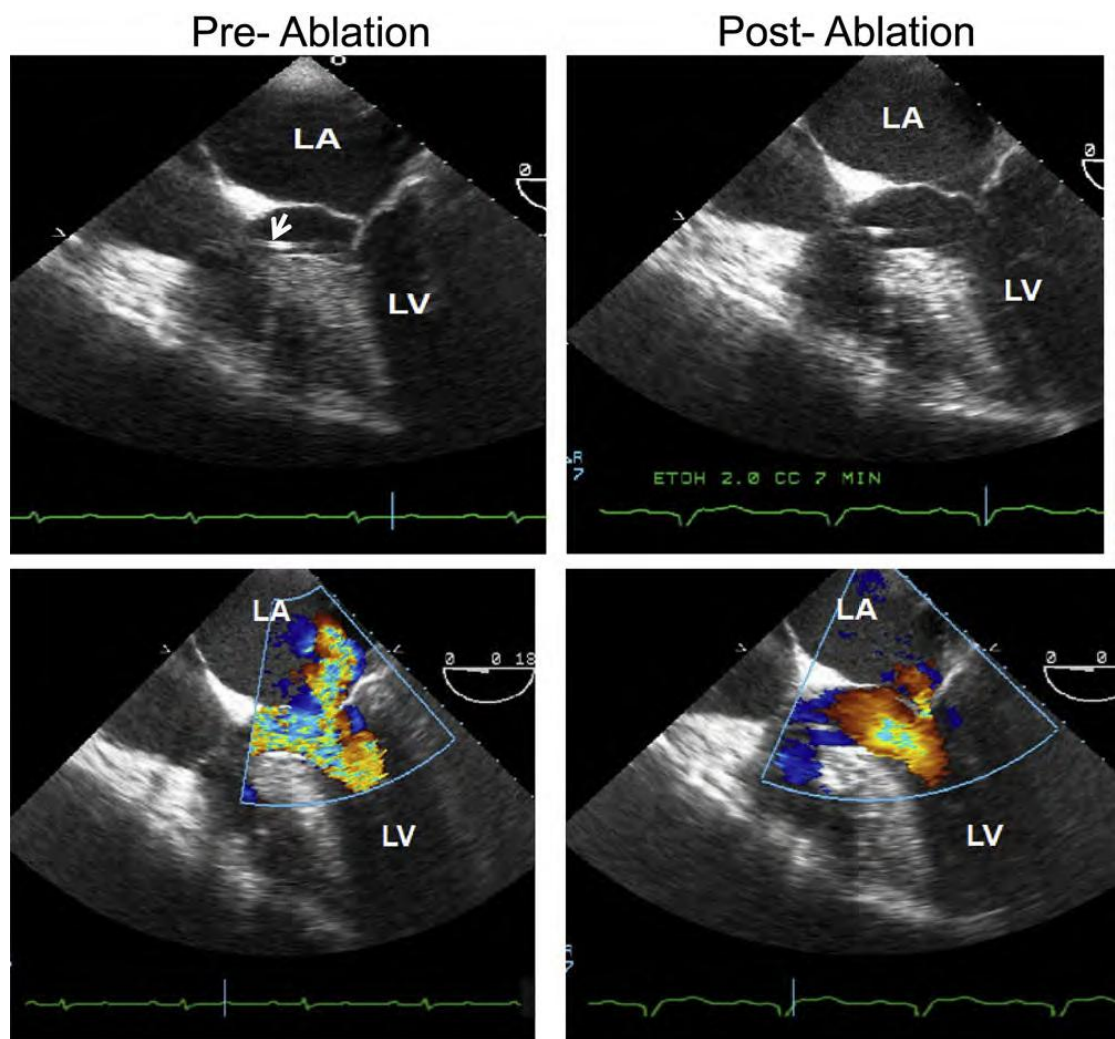
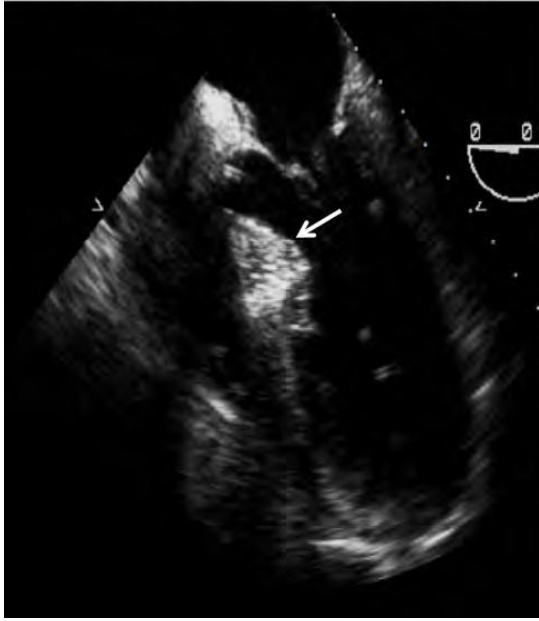

图11 HCM患者室间隔酒精消融术前后的TEE图像。左上：消融前二维图像显示左室流出道狭窄和SAM征；右上：消融后二维图像。左下：消融前彩色多普勒显示彩色镶嵌的高速血流信号和指向后侧壁的偏心性二尖瓣反流。右下：消融后，左室流出道流速明显下降，微量二尖瓣反流。箭头所指为穿过左室流出道的导管，用于在术中测量左室压力。LA，左心房；LV，左心室。

MCE opacifies LV side of septum



MCE opacifies RV side of septum

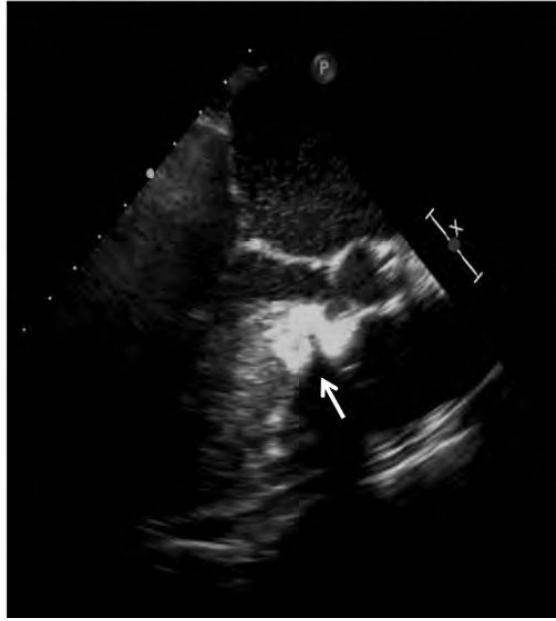


图12 进行室间隔酒精消融治疗的两名HCM患者的超声心动图心肌造影（MCE）图像。左：左室侧的室间隔基部显影（箭头），肥厚的室间隔会与二尖瓣前叶接触，是合适的消融部位；右：右室侧的室间隔显影（箭头），此位置不会引起动力性梗阻。

表1 HCM患者的超声心动图评估

-
- 1.是否存在心肌肥厚及其定位；报告应该包括左室大小和室壁厚度（室间隔，后壁，和最大值）
 - 2.左室射血分数
 - 3.右室肥厚及是否存在右室动力性梗阻
 - 4.基于体表表面积的左房容积指数
 - 5.左室舒张功能（评价左室松弛和充盈压）
 - 6.肺动脉收缩压
 - 7.静息状态下和Valsalva动作后的动力性梗阻；报告应该指出梗阻的位置和压力阶差。
 - 8.二尖瓣和乳头肌的评估，包括方向、结构和二尖瓣反流的严重程度；如有需要，应作TEE检查来回答这些问题。
 9. 建议应用TEE指导外科心肌切除术，应用TTE或TEE指导室间隔酒精消融术。
 - 10.筛查
-

表2 室间隔酒精消融术中MCE的优势

-
- 1.减少介入时间
 - 2.减少X线透视时间
 - 3.减少闭塞血管数量
 - 4.减少酒精用量
 - 5.减少梗塞面积
 - 6.降低心脏传导阻滞的可能性
 - 7.提高成功率
-

表 3HCM 患者的核素显像

-
1. 心肌灌注
 2. 放射性核素显像及门控 SPECT 测量左室容积和射血分数
 3. 当超声心动图和心血管磁共振成像不适用时, 用于监测经医学或非医学治疗后动力性梗阻情况 (药物或动力性梗阻介入治疗后, 观察左室容积、射血分数和充盈率的变化)
 4. 应用 PET 观察冠状动脉血流储备
 5. 应用 PET 观察心脏代谢 (科学研究)
 6. 应用 SPECT 或 PET 观测心肌受体和神经递质 (科学研究)
-

3. 核素显像

A. 心脏结构

门控血池放射性核素显像可以测量左室容积及其射血分数, 以及右室容积及其射血分数。放射性核素显像可以很容易地识别出无症状的以室间隔增厚为主的非对称性心肌增厚。单光子发射计算机化断层显像 (SPECT) 也可提供类似数据 (表 3)。但超声心动图和心血管磁共振成像空间分辨力更高, 可提供更精确的测量值。因此, 以评估心脏结构为唯一目的的核素显像已不再被推荐。

B. 放射性核素显像测量左室收缩功能

应用门控血池放射性核素显像可为 HCM 患者提供可靠且可重复的左室射血分数测量值。大多数患者放射性核素显像的特征包括: 射血分数正常或超常、室间隔不成比例的增厚及收缩期心室腔闭塞。少数患者在病程后期发展为左室收缩功能不全, 射血分数降至正常以下, 很容易被放射性核素显像检出。但鉴于超声心动图和心血管磁共振成像的实用性, 若以评估射血分数为唯一目的, 则常无需应用放射性核素显像。

C. 放射性核素显像测量左室舒张功能

左室充盈的定量参数可以从时间-活性曲线中获取, 与舒张期左室容积变化密切相关。为了避免低估左室充盈, 应首选高时间分辨率的方法。峰值充盈率是应用最广泛的反映心脏舒张功能的放射性核素参数, 它表示时间-活性曲线第一阶段的最大值。应用钙通道阻滞剂如维拉帕米^{44,45}后, 左室充盈可改善, 患者症

状可减轻，但这些药物会导致左室充盈压上升，可使部分原有左室舒张早期充盈参数升高的患者舒张功能不全进一步恶化⁴⁶。

超声心动图可用于评价 HCM 的舒张功能，由于可测量每个心动周期的舒张充盈参数，因此得到的左室松弛指数较少受容量因素的影响。

D. 动力性梗阻及二尖瓣异常

核医学技术不能检出 SAM 征或评估动力性梗阻的位置及严重程度，但可发现左室高动力伴左室心腔闭塞。

E. HCM 的二尖瓣反流

核素显像不能显示导致二尖瓣反流的结构异常，但如患者仅有二尖瓣单瓣反流（即除了二尖瓣反流外不伴有其他瓣膜的严重反流），则可通过计算左右心室搏出量的差异，来评估二尖瓣反流的严重程度。鉴于其他技术方法存在的局限性，推荐首选超声心动图评估 HCM 患者的二尖瓣反流。

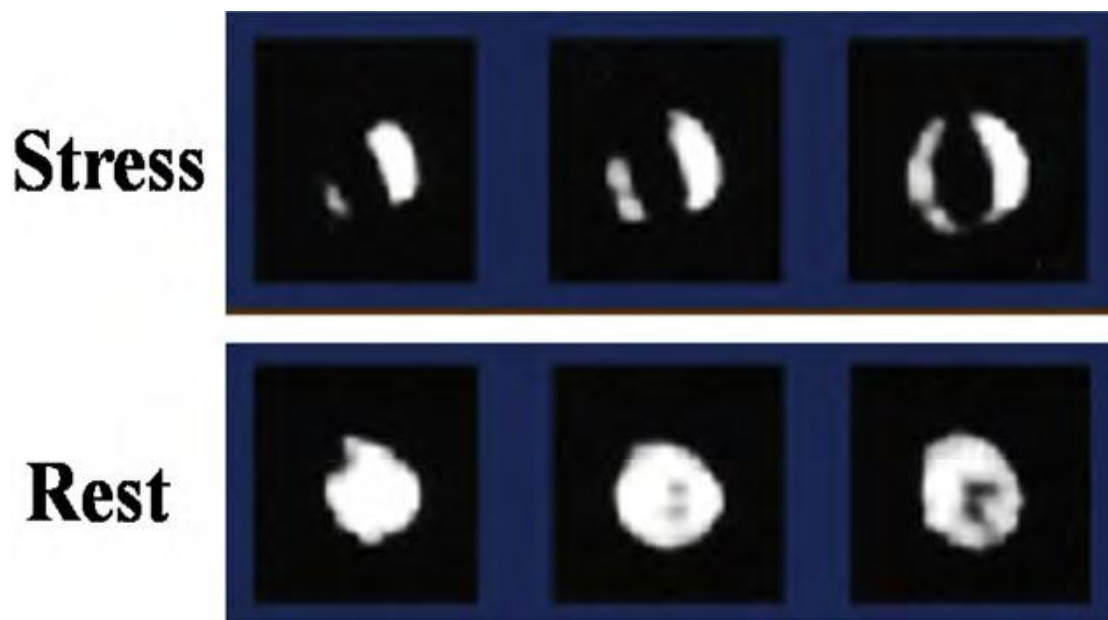


图 13 从心尖到基底的三个连续短轴图像，显示了无冠状动脉粥样硬化性心脏病的 HCM 患者负荷（顶部）和静息（底部）状态下的心肌灌注显像。前壁、间隔、下壁有多个静息状态下正常，而运动后诱发的钝灌注缺损（可逆性缺损），与心肌缺血的同位素显像图像特点一致。此外，有明显的运动诱发的左室腔扩张和广泛的心肌肥厚。

F. 心肌缺血、纤维化及代谢

i. SPECT. 部分 HCM 患者存在心肌缺血，却无心外膜冠状动脉狭窄的证据，可能与心肌内小血管异常、心肌细胞结构异常、大量的肥大心肌、心肌内微循环异常等所引起的心肌血流不足有关，尤其在心肌耗氧量增加时缺血更明显。许多患者的心肌耗氧量增加也可由左室肥厚和流出道梗阻所致。运动、血管扩张剂如腺苷和多巴酚丁胺可以诱发心肌缺血。基于对可能诱发和加重动力性梗阻的顾虑，不推荐在 HCM 患者中应用多巴酚丁胺作负荷心肌灌注显像。心肌缺血的存在及其严重程度可通过发现可逆性的铊摄取异常区域而明确（图 13）。这是成年人 HCM 的病理生理学特征⁴⁷⁻⁴⁹，与潜在致死性心律失常、不良心室重构及收缩功能不全有关⁴⁹⁻⁵⁰，甚至病变尚未累及心外膜时也是如此。除了上述机制，左室松弛功能受损和左室舒张末压升高可挤压冠状动脉微循环，进一步限制冠状动脉血流⁵⁰⁻⁵⁵。反复发生的心肌缺血可以引起心肌损伤和疤痕形成（特征为固定缺损），这些变化可潜在性降低室性心律失常的阈值。特别值得指出的是，已证实固定缺损与晕厥、较大的左心腔和降低的运动能力相关⁵⁶。

在选定一组年轻 HCM 患者中，心脏猝死或晕厥常与心肌缺血有关⁴⁹。但并非所有研究都能观察到缺血与临床事件之间的关系⁵⁶。SPECT 对诊断心外膜冠状动脉病变的特异性较低。肥厚区域（如室间隔）同位素摄取增加，使正常节段与肥大节段相比同位素计数明显降低，³⁹ 这样就会出现假阳性结果（图 14）。尽管不推荐常规应用 SPECT 负荷灌注显像，但如 HCM 患者伴有胸痛，而其冠心病机率较低时仍可考虑负荷 SPECT 显像。

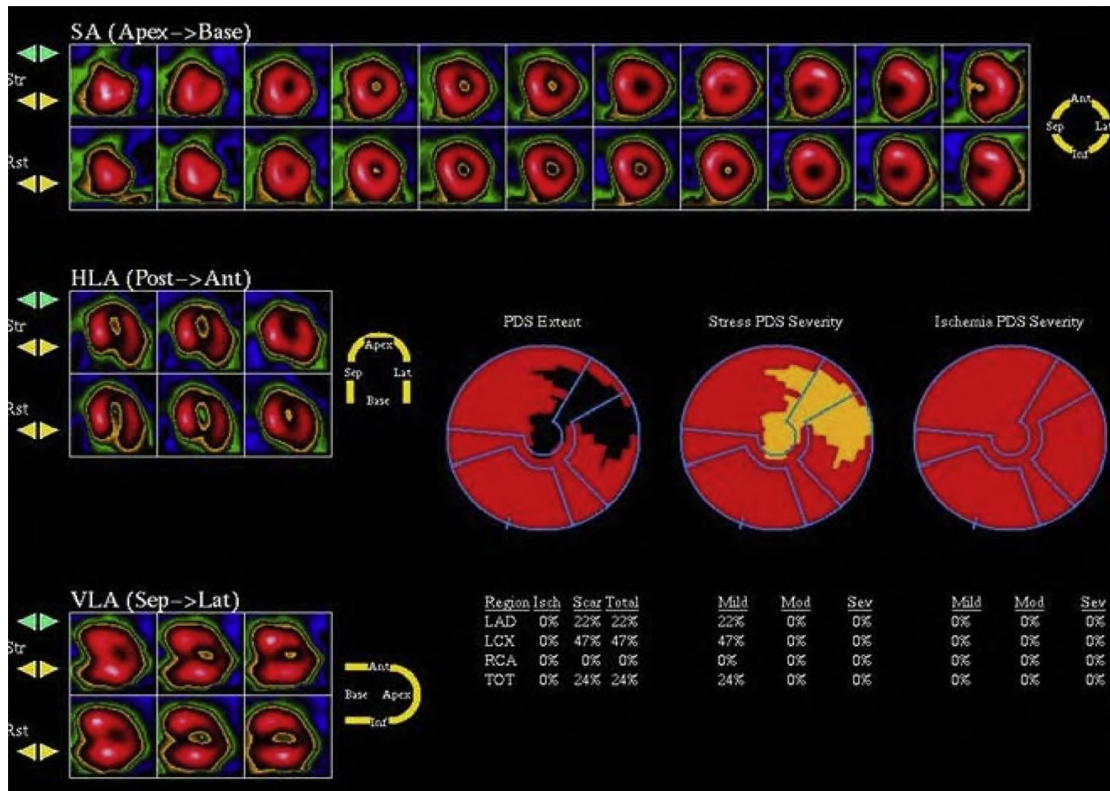


图 14 一例 HCM 患者的单光子发射计算机断层显像。室间隔 (*Sep*) 厚度增加, 室间隔相对于侧壁活性计数 (热点) 也增加。计算机分析软件记录到了侧壁和心尖固定缺损, 而室间隔正常。 *Ant*, 前壁; *HLA*, 水平长轴; *LAD*, 冠状动脉左前降支; *LCX*, 冠状动脉回旋支; *RCA*, 右冠状动脉; *SA*, 短轴; *TOT*, 总计; *VLA*, 垂直长轴。 J Am CollCardiol 授权转载³⁹。

ii. 正电子发射断层成像 (PET)。尽管 SPECT 广泛应用于 HCM 患者的临床研究, 但 SPECT 评价局部心肌灌注缺损时, 仅可得到心肌放射性分布的相对值, 而不是心肌血流灌注的绝对值 (如: 毫升/克/分钟)。应用 PET 定量局部心肌血流量在心血管研究中已不可或缺, 但在临床实践中应用仍较少。费用较贵、设备及放射性示踪剂获得较困难是 PET 的主要劣势, 因为 PET 检查需要回旋加速器或是昂贵的同位素发生器。

冠状动脉正常的 HCM 患者, 虽然心肌灌注 PET 提示静息状态下心肌血流量绝对值与正常对照组相似, 但应用血管扩张剂 (如双嘧达莫) 后血流量的增加明显减弱。此外, 这种应用血管扩张剂后异常的心肌血流储备在心内膜下区域更为明显, 与所谓的“显著”短暂性血管腔扩张一致^{52,55}。这种无心外膜 CAD 的、可以量化的心肌血流储备异常, 可能与微血管功能障碍导致的心肌缺血有关, 对预后具有重要意义⁵⁰。这些 HCM 患者, 如无其他不利因素影响, 其累计生存率与药物性血管扩张达到的心肌血流量相关。HCM 患者应用双嘧达莫后, 心肌血流量降低较多者, 更易出现左室重构、左室射血分数减低和严重的心力衰竭症状。总之,

目前尚不提倡对 HCM 患者常规进行 PET 检查以发现潜在的心肌缺血，但某些特定患者，如伴有心绞痛或发现与左室射血分数不符的心力衰竭的患者，则可以考虑 PET 检查。

iii. 代谢影像

未来，通过核素示踪剂评价心肌代谢⁵⁷、交感神经支配⁵⁸⁻⁶⁰，和 β -肾上腺素能受体密度⁶¹可能进一步阐明 HCM 的病理生理机制，明确 HCM 在左室功能障碍及重构进展、心力衰竭发展和心脏猝死中起的作用。然而，这些示踪剂的临床应用目前仍处初步探索阶段。

G. 指导室间隔消融

如上所述，由于核医学成像在二尖瓣图像和动力性梗阻评估方面存在局限，并非室间隔消融治疗所需。但该技术可以提供室间隔消融治疗后左室功能和心肌灌注的重要信息。对有症状的 HCM 患者于室间隔切除术或二尖瓣置换术前后分别进行 SPECT 检查，术前 85% 患者存在铊灌注缺损，其中 65% 的患者术后灌注缺损的大小和分布完全恢复正常或得到改善。这与术后肺摄取的改善和暂时的心室扩张有关。

酒精消融术使室间隔变薄后，左室流出道压力阶差立刻降低，97% 的患者 6 周后固定灌注缺损有所增加但不影响左室射血分数⁶²。术后 8 个月后再次检查发现，室间隔基底段灌注缺损从术后早期占左室心肌的 9.4% 减少到 5.2%，且未加重左室流出道梗阻或出现症状复发⁶³。除非存在超声心动图和 CMR 方面的技术限制，并不推荐侵入性治疗后常规进行核素成像评价心脏功能。

H. 筛查和临床前诊断

目前核素显像技术尚未应用于 HCM 的筛查和临床前诊断。

3. 心血管磁共振成像

A. 心脏结构

CMR 已成为一种重要的三维断层成像技术，它可在任意平面提供高空间分辨率和高时间分辨率的心脏图像，且无电离辐射⁶⁴⁻⁹¹。CMR 电影成像序列是在屏气状态下，通过回顾性或前瞻性心电门控所获得的，与 2 维超声心动图的成像平面

几乎一致。此外，左室短轴系列切面是由很薄的心肌切片（通常 7mm）组成，可以断层方式完整覆盖整个心肌。电影成像序列（无对比剂）中明亮的血池和暗淡的心肌形成了强烈对比，因此可以提供 HCM 的详细特征，包括精确的室壁厚度测量值⁶⁷⁻⁶⁹及可重复性很高的室容积和质量的测量值（表 4）。

CMR 对明确 HCM 是否存在左室肥厚、肥厚心肌的位置和范围特别有用（图 15），大约 10% 的 HCM 仅局限于一个或两个左室节段⁶⁷。虽然超声心动图和 CMR 对左室壁最厚处的测量值往往很接近，但部分患者中，CMR 可以发现二维超声心动图无法很好观察到的左室壁局灶性增厚。基底段前外侧游离壁的室壁肥厚就是其中一个例子，超声心动图中短轴切面由于空间分辨率不足，侧壁心外膜边界很难与相邻的胸壁区分⁶⁹。另一个区域是左室心尖部的肥厚⁶⁸。同样，CMR 可以识别出 HCM 心尖部室壁瘤，这一发现往往会改变治疗方案⁷⁵。CMR 也可提供精准的左室肥厚特征。最近的一项研究指出，54% 的 HCM 患者存在弥漫性心肌肥厚（指左室心肌受累 >50% 和累及八个或更多心肌节段）⁶⁷。CMR 对识别严重肥厚的节段（>30mm）非常有用，而此为考虑植入 ICD 的指征。因此，应考虑对左室心肌显示不清的 HCM 患者进行 CMR 评估。

HCM 的 CMR 成像显示多达三分之一患者存在右室壁厚度和重量增加⁷⁶，如肥厚累及室间隔缘，则可观察到右室流出道梗阻。HCM 患者的乳头肌数量和重量也有所增加⁷⁷。此外，一小部分 HCM 患者虽然左室肥厚是局灶性或局限性的（左室重量正常），但却存在相当程度的乳头肌肥大。CMR 对乳头肌的评估发现如前外侧乳头肌向心尖移位或存在双组乳头肌，是与静息状态下 LVOT 压力阶差明显升高有关的（图 16），这也揭示了流出道梗阻的机制。

表 4 HCM 患者的 CMR 成像

-
1. 左室形态，包括肥厚程度及其分布
 2. 右心室形态
 3. 二尖瓣装置及乳头肌
 4. 整体和局部左室功能
 5. 评估左室流出道梗阻（如可作超声心动图，则 CMR 作用有限）和二尖瓣反流的机制及其严重程度
 6. 负荷灌注成像评估心肌缺血
 7. 应用对比剂增强 CMR 观察局灶性纤维化并分型
-

8. 监测侵入性治疗（室间隔切除术和酒精消融术）

9. 筛查

10. 观察血管和心室间相互影响

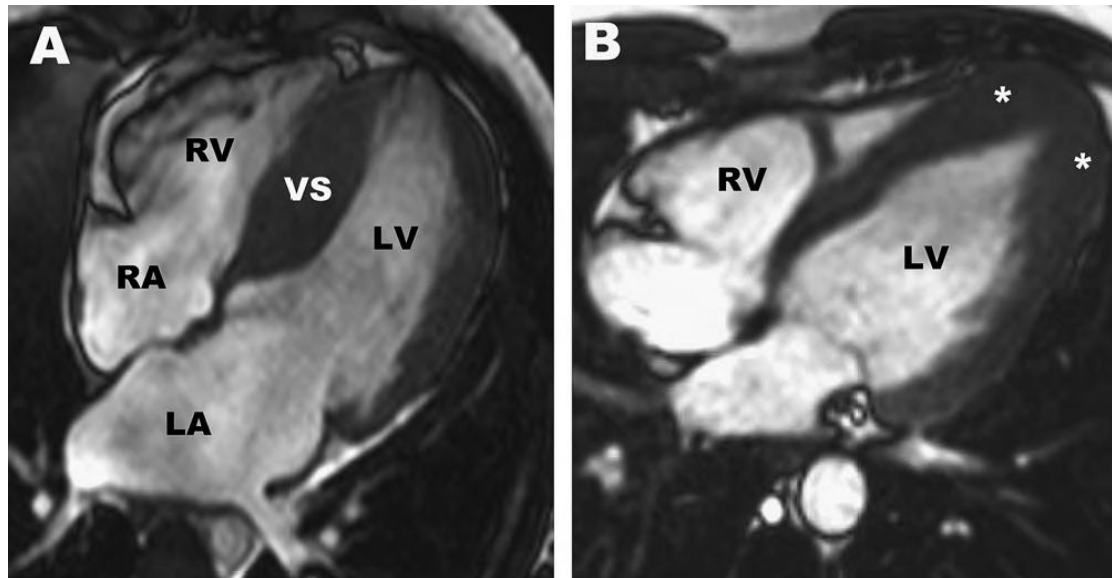


图 15 (A) 27 岁无症状 HCM 患者的舒张末期四腔 CMR 图像，显示心肌肥厚以室间隔为主（最厚处 24mm）。(B) 16 岁患者舒张末期四腔 CMR 图像，显示局限于左室心尖部的室壁肥厚（星号），符合心尖部 HCM 诊断。LV, 左室；RA, 右心房；RV, 右心室；VS, 室间隔

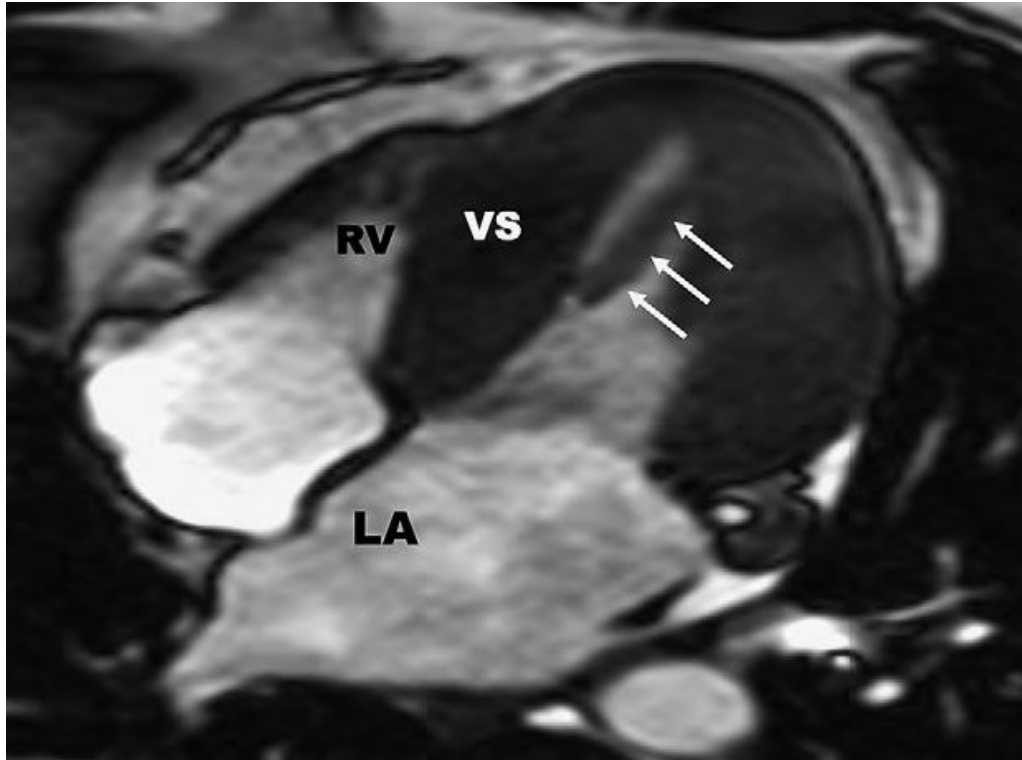


图 16 HCM的乳头肌向心尖部移位。一例44岁男子收缩中期四腔心CMR电影，图像显示静息状态下左室流出道压力阶差为85mmHg，且乳头肌向心尖移位（箭头），由于二尖瓣环平面位置更接近于室间隔，形成了流出道梗阻。LA，左心房；RV，右心室；VS，室间隔

B. 评估左室收缩功能

CMR测量心室容积和射血分数是准确的和可重复的。此外，可以使用心肌标记方法定量评估局部心肌收缩和舒张功能^{79,80}。为数不多的研究证实了HCM患者确实存在心肌功能的局部差异⁷⁹。然而目前临床上尚未明确是否可应用心肌标记技术来鉴别HCM和继发性心肌肥厚（即高血压性心肌病或运动员心脏），或者说心肌标记的异常是否出现于左室肥厚之前。

C. 评估左室舒张功能

CMR可以测量二尖瓣血流、肺静脉和二尖瓣环血流速度，也可以计算左室充盈速率。然而这些通过CMR测量的速度是否可特定应用于HCM仍未评估，故目前尚不推荐。

CMR的广泛使用使我们更深入了解了HCM心室-血管间复杂的相互作用。最近研究显示，与对照组相比，HCM左室流出道和主动脉根部与左室的夹角更大，⁸¹而这一夹角的大小与左室流出道压力阶差独立相关。近年来，相位对比CMR测定的脉搏波传导速度结果显示，HCM患者主动脉僵硬增加，特别是心肌被纤维组织替代的HCM患者，其主动脉僵硬高于没有晚期钆增强（LGE）的HCM患者⁸²。进一步研究表明，主动脉僵硬增加对运动能力有不利影响，这一影响与左室形态、舒张功能和左室流出道压力阶差无关⁸³。

D. 动力性梗阻和二尖瓣异常

通过CMR的长轴和短轴图像可以明确二尖瓣与室间隔是否接触。此外，往往可在二尖瓣与室间隔接触区域观察到高速血流导致的收缩期射流信号，支持主动脉瓣下狭窄的存在（视频5[在线观看视频]）。可以通过相位速度血流映射序列测定左室流出道峰值流速，来明确HCM瓣下梗阻的程度。然而，只有少量研究对CMR测得的左室流出道流速与连续多普勒测得的压力阶差之间作了精确度的比较⁸⁴。因此，不能确定经CMR与超声心动图连续多普勒测得的流出道流速是否一致⁸⁵。相位速度血流映射序列存在一定的技术限制，使它难以可靠地应用于临床。目前CMR只能在基础状态下进行评估，这是一个很大的局限性，因为1/3的HCM患者仅在诱发后才出现流出道梗阻。由于这些原因，流出道梗阻的相关决策应基于超声心动图获得的压力阶差。

E. HCM二尖瓣反流

虽然通常应用超声心动图来评估二尖瓣反流程度，但也可应用CMR观察二尖瓣装置，评估二尖瓣反流的机制和严重程度。如前文所述，CMR也可以提供乳头肌大小和位置的重要信息。在计划进行解除梗阻的手术时，这些信息具有潜在价值。因此，当超声心动图无法看清二尖瓣或乳头肌，且患者拒绝TEE或是存在TEE禁忌症时，应考虑CMR。

F. 心肌缺血、纤维化和代谢

i. 缺血. 使用钆造影剂可以评估静息和负荷状态下的心肌血流⁷⁰。随着CMR灌注序列的发展，使静息和药物负荷下精确性和定量评价心肌血流量（通常使用腺苷）成为可能。负荷CMR可以发现，HCM患者对血管扩张剂诱导的心肌血流增加效应有所减弱，心内膜下心肌较心外膜心肌更明显，且同时存在于肥厚与非肥厚区域。目前尚无CMR测得的心肌缺血与临床预后之间相关性的数据。目前临床上

不建议作常规血管扩张剂负荷的 CMR 检查。

ii. 纤维化. CMR 增强 LGE 序列可以发现 HCM 患者的局灶性异常心肌区域^{72,74,86-88}。可勾划出 LGE 区域的面积,并可定量表示为与左室质量的百分比。对一些进行了心脏移植的终末期 HCM 患者,研究人员对其原有心脏进行了大体及组织病理学检查,发现纤维化程度与前期在体 CMR 检查的 LGE 结果一致⁸⁷。但仍不能确定是否所有正常或高动力射血分数的 HCM 的 LGE 都代表心肌纤维化。类似的,弥漫性心肌纤维化时应用 LGE 技术常无法找到合适的正常心肌作参照背景,而新的 CMR 技术在弥漫性心肌纤维化定量中有一定前景。

约有 50%-80% HCM 患者出现 LGE, LGE 阳性的心肌占整个左室心肌体积的 10%^{72,74,86,88}。HCM 的 LGE 没有特定模式, LGE 的分布也不像得过心肌梗塞的患者那样沿冠状动脉走向分布。LGE 常位于室间隔,但局限于左室游离壁或右室游离壁与室间隔的插入点(图 17)⁷⁴的也不少见。LGE 更常见于肥厚的心肌节段,以及伴较大左室质量指数的 HCM 患者^{72,74,86}。

许多研究已证明 LGE 的范围与收缩功能障碍相关的不良左室重构之间的关系。终末期 HCM 患者 (EF<50%) LGE 范围较大,而射血分数较高的患者范围则较小^{72,74,86,88}。然而,目前还不清楚 LGE 的范围是否可前瞻性地识别 HCM 患者进展为收缩功能障碍的风险。同样,大量横断面研究显示 LGE 与 24 小时动态心电图发现的室性心律失常(包括室性心动过速)之间显著相关^{71,73}。但是,目前尚不清楚相比 LGE 定性方法而言, LGE 范围是否在识别猝死风险患者方面有更大的预测价值。最近一些前瞻性短期研究评估了 LGE 与心血管结局预后的数据^{86,88}。其中一项研究发现 LGE 的 HCM 患者不良心血管事件发生率无显著增加⁸⁶。更新的一项研究发现 LGE 与猝死或正确的 ICD 放电之间存在显著关系。然而鉴于不良事件数量较少,有必要在更大的队列研究中进行更长期的随访,以在统计学上确定 LGE 是否为不良事件的独立预测指标。因此,目前不推荐 LGE 用于常规临床决策。

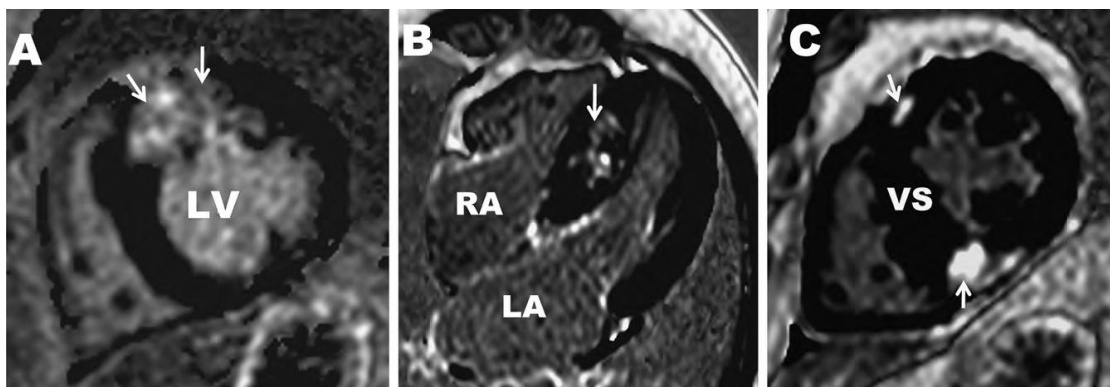


图17 HCM的对比剂增强CMR及晚期钆显像增强。(A) 58岁无症状女性HCM患者,图像显示基底部前间隔和前壁大面积透壁LGE。(B) 21岁男性HCM患者,室间隔中层心肌呈弥漫性和片状LGE。(C) LGE局限于右室游离壁与前、后室间隔相交的插入

点。LA, 左房; LV, 左室; RA, 右房; VS, 室间隔

*iii. 代谢图像.*核磁共振评价心肌代谢很少用于HCM患者^{80,90}。然而, 需要更多这方面的研究来阐明与心肌代谢有关的HCM心肌重构和心力衰竭的病理生理学变化。但目前不建议核磁共振在HCM患者心肌代谢方面的临床应用。

G. 指导室间隔消融术

CMR可以识别出与梗阻有关的、需要切除以解除流出道压差的副乳头肌。因此, CMR可以于术前指导手术规划。CMR短轴和长轴电影成像可以显示出心肌部分切除术的手术区域。

对比剂增强的CMR可准确定量室间隔消融术后坏死组织, 以及疤痕位置与左室流出道之间的关系。平均而言, 消融术引起的梗死心肌范围占左室总质量的10%⁹¹。CMR可以明确室间隔酒精消融术后未获理想结果的原因, 因为在少数患者, 组织坏死主要涉及心室中部室间隔右心室一侧, 即室间隔变薄发生在二尖瓣与室间隔接触区域的远端, 导致依然存在持续的动力性梗阻。CMR显示室间隔酒精消融后左室流出道阶差的下降与左室重构有关, 包括室间隔质量的减少和梗死后的室间隔心肌远离了流出道⁹²。不推荐室间隔术后常规进行CMR, 但部分患者如术后左室功能和心肌重构出现问题, 而超声心动图不能很好解释时, 或术后流出道再次出现压力阶差时, CMR检查是有价值的。

H. 筛查与潜伏期诊断

CMR发现的一些形态学异常可能在HCM临床前期(基因型[+]/表型[-])就存在。特别是, CMR已证实临床前期患者室间隔下段出现隐窝结构, 其病因仍不能确定⁹³。有必要进行更多的研究进一步阐释这些CMR所发现的形态学异常在临床前期HCM患者中的发生率及其临床意义, 因为部分异常在正常人中也存在。

目前, 尚无数据比较CMR和超声心动图在筛查家族性HCM方面孰优孰劣。鉴于CMR可识别超声心动图无法识别的左室肥厚, 以下情况仍可考虑应用CMR评估家庭成员的风险:

超声心动图图像不理想, 不能清晰显示所有左室节段; 其他检查有异常如心电图怀疑HCM而超声心动图结果正常; HCM的诊断尚不明确, 但患者是极高危家族的成员, 诊断会对治疗策略产生直接影响, 比如是否考虑作为一级预防植入ICD以预防猝死, 或应避免竞技体育。

表 5 HCM患者的心脏CT检查

1. 超声心动图检查左室形态显示不佳，或不适合CMR检查者（例如，ICD和起搏器）
2. CT断层扫描评估冠状动脉疾病
3. 必要时可提供室间隔切除术前、术后冠状动脉解剖和二尖瓣环的信息（有超声心动图和CMR时通常不需要）

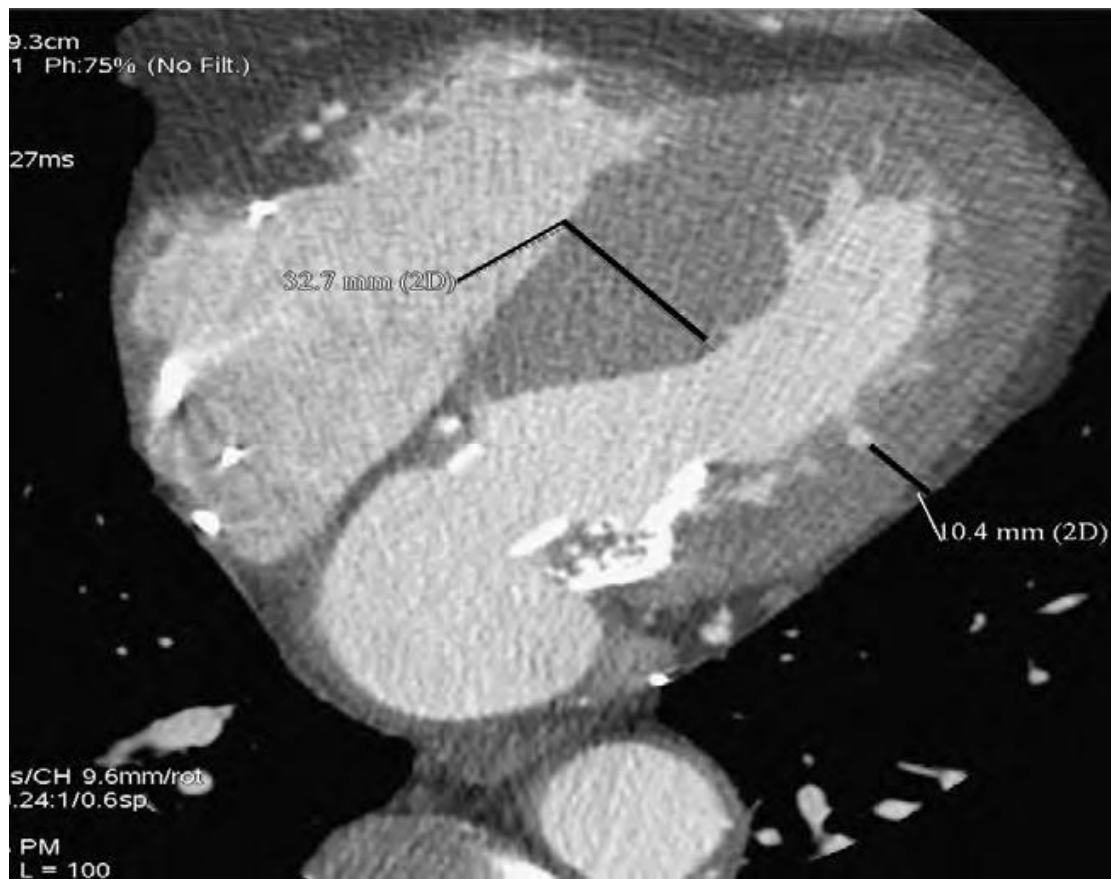


图 18高对比分辨率的门控心脏CT，通过对比剂（白色）

和心肌（灰色）的强烈反差，可以清晰地勾勒出心肌，因此可提供HCM表型的详细特征。此例患者呈非对称性室间隔肥厚，因患者已植入起搏器，故无法进行CMR检查。线状测量值表示的是室间隔心肌厚度和侧壁心肌厚度。

4. 心脏计算机断层扫描

A. 心脏结构

心脏计算机断层扫描（CT）是一种三维断层成像技术，提供具有良好空间分辨率和时间分辨率的心脏图像⁹⁴。由于同方向成像，左室短轴和长轴切面可以形成0.4mm的薄切片，提供覆盖整个心肌的完整断层图像（表5）。

高对比剂分辨率可以划定明确的心肌界线，对比剂（白色）和心肌（灰色）区分明显，故可以提供HCM表型的详细特征（图18），包括精确的室壁厚度测量和高度可重复性的室容积、射血分数和质量^{95,96}的测量值。已有研究对不明原因心肌病患者的64排冠状动脉CT检查与CMR和侵入性血管造影检查进行了比较⁹⁷，但目前尚无系统评价HCM患者的研究报道。

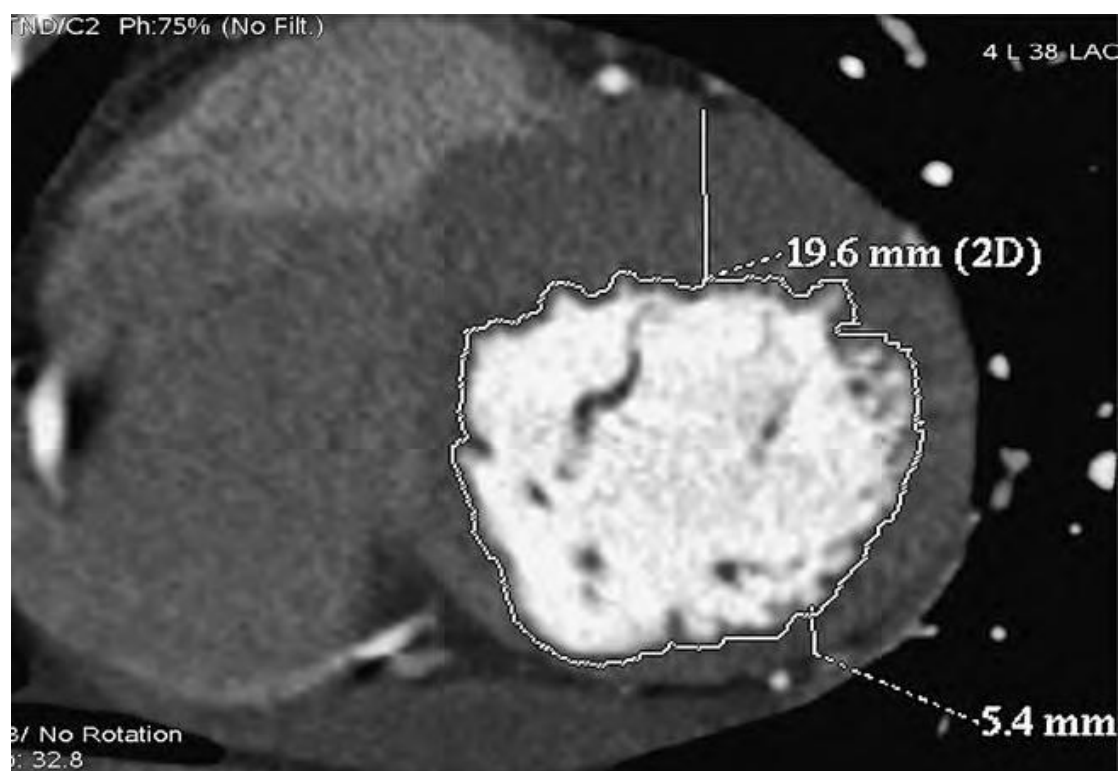


图 19 心脏CT断层成像短轴图像，显示非对称性心肌肥厚。测量值为前间隔（19.6mm）和下侧壁（5.4mm）。

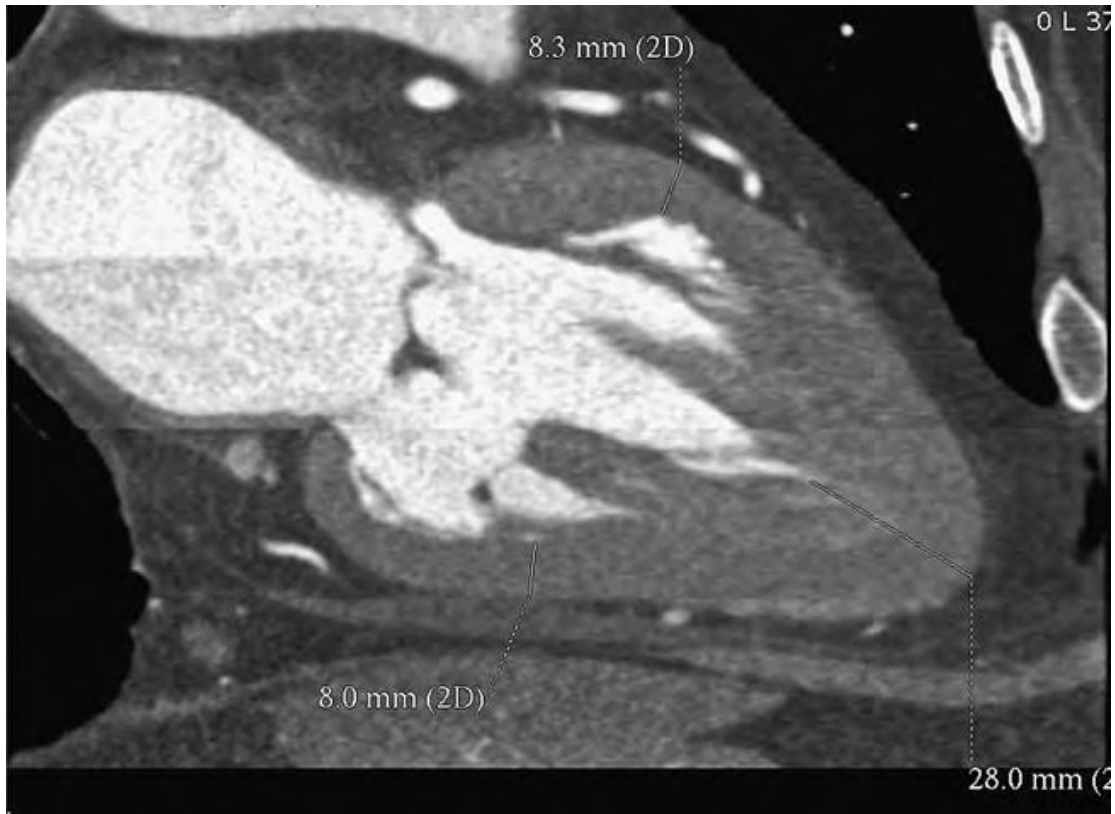


图 20 增强CT图像重建后很好地显示了包括乳头肌在内的所有心脏结构，提示心尖部肥厚。心脏CT显示前壁和后壁舒张末期厚度均正常（分别为8.3mm和8mm），而心尖重度肥厚（28mm）。

心血管CT可同时对冠状动脉、是否存在心肌桥、右室和左室容积和质量以及心脏整体和局部的功能^{98, 99}进行成像。所有心脏的结构包括乳头肌都可以很好显示（图19）。心尖、室间隔和乳头肌的肥厚都可以很方便地被勾画出来（图20）。CT可提供左室肥厚的精确范围，包括识别明显肥厚患者（最大的壁厚>30mm），有助于选择合适患者进行ICD治疗。

总之，心脏CT对部分患者有优势。特别当超声心动图的图像受声窗限制，心脏CT能可靠地识别所有左室节段，提供精确的室壁测量值。由于CT的空间分辨率比CMR和超声心动图更高，其在容积和质量测量方面至少相当于或更优于其他两种检查。但是，CMR显示组织特征的能力更胜一筹。

目前，在评价或诊断HCM方面，尚无心脏CT与超声心动图和CMR的系统性比较数据，故临床上一般不推荐心脏CT。虽然如此，在某些特定状况下，心脏CT仍不失为有用的检查手段，如超声心动图图像不佳时，或有CMR禁忌（如：起搏器或ICD植入，幽闭恐惧症，患者无法长时间屏住呼吸）时。这些情况下可应用心脏CT，但仍需关注回顾性心电门控时较大的辐射暴露，应尽可能采用前瞻性触

发¹⁰⁰。

B. 左室收缩功能的评价

心脏CT可以准确测量左室容积和射血分数。但尚缺少特定应用于HCM的数据。

C. 评价左室舒张功能

由于心脏CT的时间分辨率有限，目前不用于评估左室舒张功能。

D. 动力性梗阻和二尖瓣异常

心脏CT已经被用于评估二尖瓣环的三维形状、大小和运动，也可在多相图像中显示二尖瓣前叶的SAM征象和二尖瓣环钙化的范围。

目前不用心脏CT评估HCM的动力性梗阻，因为超声心动图和CMR可以获得这些数据且无辐射污染。

E. HCM的二尖瓣反流

CT可以评价乳头肌异常所影响的二尖瓣功能。这些异常包括乳头肌肥厚的位置和程度。然而，尚未评价应用该技术评估HCM的二尖瓣反流情况。

F. 心肌缺血，纤维化和代谢

CT可以容易地观察到冠状动脉，识别狭窄的位置和范围，及识别心肌桥的存在。有中-高度冠状动脉疾病可能的HCM患者出现胸痛症状时应考虑CT检查明确诊断。目前CT尚不能评价心肌纤维化和心肌代谢。

G. 指导室间隔消融

CT可以同时冠状动脉和左室心肌进行成像，从而明确描述冠状动脉和左室心肌之间的关系。这些信息对室间隔切除术是有用的，故可用于HCM室间隔酒精消融术的术前准备和术后评价¹⁰²。虽然这是一个有希望的方向，但目前常规心脏CT并没有被推荐用于此方面。

H. 筛查与临床前期诊断

目前CT尚未应用于HCM的筛查和临床前诊断。

5. 儿童的HCM影像学

二维超声心动图是用于评价小儿HCM的主要无创诊断方法^{103, 104}。成人HCM的解剖和生理性特征在儿童也很突出, 包括非对称性室间隔心肌肥厚、动力性左室流出道梗阻、心室收缩和舒张功能障碍、二尖瓣和二尖瓣装置的SAM征象和不同程度的二尖瓣反流。在儿童和成人, 心肌肥厚的解剖模式(“室间隔曲率”)已被证明与遗传变异有关¹⁰⁵。

超声心动图也在排除其他原因导致的心肌肥厚中起关键作用。小儿先天性心脏病, 包括主动脉缩窄和主动脉瓣或主动脉瓣下狭窄, 常伴后负荷增加引起的显著左室肥厚。全身性疾病在儿童中可引起显著心肌肥厚, 包括高血压、肾动脉狭窄、嗜铬细胞瘤、代谢或贮存性疾病。一些综合征如Noona综合征、LEOPARD综合和Friedreich's共济失调也可出现对称或非对称性心肌肥厚, 酷似HCM。

最近研究表明, 左心房容积与小儿HCM病情严重程度之间也有关, 与舒张功能障碍、临床症状和运动耐量下降程度均有显著相关关系¹⁰⁶。对有明显左室流出道梗阻的儿童进行手术切除后, 其左心房容积的大小与其运动耐量的改善及长期预后有关¹⁰⁷。

多普勒超声心动图在评价儿童HCM中起重要的作用。常规二尖瓣血流和肺静脉血流频谱可出现心肌舒张功能受损的表现。舒张早期充盈时间降低, 等容舒张时间延长和肺静脉血流左心房逆转时间延长都是儿童HCM舒张功能异常的表现。舒张中期二尖瓣波的存在也可出现于松弛功能明显受损的HCM患者中¹⁰⁸。儿童HCM患者的室间隔侧和外侧壁二尖瓣瓣环收缩和舒张早期组织多普勒速度显著降低。已证明室间隔E/e' 比值可预测儿童HCM的临床风险, 包括死亡、心脏骤停或室性心动过速。室间隔E/e' 比值与临床症状密切相关, 与峰值耗氧量呈负相关¹⁸。

一些新的评估心肌变形的超声心动图方法已应用于健康儿童^{109, 110}和年轻的HCM患者^{111, 112}。儿童HCM表现为收缩变形减弱, 应变和应变率的异常在最肥厚的心肌节段表现最为明显。然而, 即使无肥厚的心肌节段, 其变形能力与健康对照组相比也有明显减弱。在儿童中对不同病因导致的左室肥厚做了类似的心肌形变分析, 发现不论潜在病因如何, 收缩形变都有所减弱, 提示与肥厚的病因相比, 肥厚本身对心肌变形的影响更显著。

6. 影像学在HCM鉴别诊断中的作用

HCM的诊断是基于存在左室肥厚，但无导致类似程度肥厚的其他疾病。心脏淀粉样变性、糖原贮积病、Anderson-Fabry病和Freiderich's共济失调都能导致心肌肥厚，但通常伴有心脏外的体征和症状，可引导医生考虑全身性疾病。其中包括肌酸激酶异常升高、心电图见预激图形、骨骼疾病、皮肤受累、大脑、小脑或视网膜病及感觉神经功能障碍。心脏形态学特征也有助于鉴别，大多数其他疾病表现为向心性肥厚，HCM多数情况下表现为非对称性肥厚。其他疾病出现左室流出道梗阻较少见。CMR钆增强可有助于某些全身性疾病的鉴别。例如，成人Anderson-Fabry病的LGE主要局限于下侧壁基底段，而这并不是HCM通常累及的节段¹¹³。此外，某些初诊（或怀疑）为心尖HCM的病例，通过CMR检查可能明确诊断为左室心肌致密化不全。CMR可发现明显的心肌小梁化，支持左室心肌致密化不全的诊断¹¹⁴。

有时很难确定究竟是高血压引起的肥厚，还是HCM引起肥厚。但高血压通常呈向心性肥厚，而不是非对称性肥厚。高血压所致的室壁厚度很少超过18至19mm，而HCM患者室壁厚度超过20mm的却很常见。

一些老年人心肌肥厚可局限于室间隔上段，室间隔形态可以呈乙状也可不呈乙状。后者的特征是左室腔通常呈卵形，室间隔凹向左室并且基底段室间隔明显凸出。有时，乙状室间隔也出现于正常厚度的室间隔。这些患者可以有动力性梗阻，但不太可能有肌节蛋白基因突变。

相对而言，更需关注的是如何将可能的HCM与高强度运动训练导致的生理性心肌肥厚相鉴别¹¹⁵。在北美，HCM是运动员猝死的最常见原因，故不建议HCM患者参与竞技体育^{1,116}。然而，许多高水平运动员因体型较大，心肌潜在性的生理性肥厚可能导致其心脏图像类似于HCM。因此，区分这两者很重要。优秀运动员研究表明，即使在最高级别的运动员中，左室壁厚度 $>12\text{mm}$ 也是罕见的（ $<1.5\%$ ）¹¹⁷⁻¹¹⁹。此外运动员心脏常见的形态学特征是腔室扩大，如舒张末内径达到或超过正常上限¹¹⁹，而HCM左室内径是缩小的。运动员的心肌肥厚通常是向心性或非向心性。

由于HCM是一个病理过程，而运动员训练的的心脏结果是生理性的适应过程，心脏影像的目的是寻找其他有利于HCM诊断的病理证据。运动员心脏不会出现显著的左心房扩张和心肌（收缩和舒张功能）障碍，但这却是HCM的常见特征。组织多普勒¹²⁰，冠状动脉血流储备¹²¹和钆显像都被报道用于区分运动员心脏和HCM。最后，停止训练可使运动员肥厚心肌退化，但对HCM的室壁厚度无影响。

应用经胸超声心动图评估合并动力性梗阻和主动脉瓣狭窄的HCM患者的主动脉瓣病变是具有挑战性的。高分辨率的经食管超声心动图可通过平面几何法测量主动脉瓣瓣口面积。

表 6 临床应用的总结

	超声心动图	核医学	CMR	心脏 CT
1.左心室内径,室壁厚度和	推荐为首次检查方法	不推荐	超声心动图不理想时推荐	很少需要,除非无法作超声心动图和CMR
2.左室射血分数和节段功能	推荐为首次检查方法	如可作超声心动图和CMR则不需要	超声心动图不理想时推荐	如可作超声心动图和CMR则不需要
3.左心室充盈压	推荐	不推荐,因为其仅提供间接证据	不推荐	不能用于此目的
4.肺动脉压力	推荐	不可用于此目的	不能用于此目的	不能用于此目的
5.左房容积和功能	推荐	不可用于此目的	超声心动图不理想时推荐	很少需要,除非无法作超声心动图和CMR
6.动力性梗阻	推荐	不可用于此目的	超声心动图不理想时推荐	不能用于此目的
7.二尖瓣反流	推荐	不推荐	超声心动图不理想时推荐	不推荐
8.缺血/CAD(如临床提示)	核医学和CT不适用时可考虑	推荐	用于科学研究	对心外膜冠状动脉病变有疑问时建议
9.心脏代谢和神经传导	不可用于此目的	用于科学研究	用于科学研究	不能用于此目的
10.侵入性治疗的监测	推荐	很少需要,除非无法作超声心动图和CMR	超声心动图不理想时推荐	很少需要,除非无法作超声心动图和CMR
11.纤维化	用于科学研究	不推荐	推荐测试	不能用于此目的
12.筛查	用于科学研究	不推荐	超声心动图不理想时推荐	不推荐

7. 对临床应用的建议

A. 形态学评价

应对HCM患者进行全面的超声心动图检查(表6)。超声心动图报告应包括具体的左室内径、室壁厚度(包括舒张末室间隔厚度、下侧壁和任何节段最厚值)、形态(非对称性/向心性)和左室肥厚的分布(累及的节段和是否存在心尖肥厚)。右室肥厚也不少见,右室壁厚度应在肋下或胸骨旁图像测量²。如需做超声造影,应参照上述“超声心动图”章节所描述的方法。通过超声心动图检查很容易对大

多数患者作出基本评估。

患者超声图像不佳时应做CMR检查。此外，如任一节段的心肌无法在超声心动图中很好显示时，可以考虑应用CMR对患者作首次评估。植入了ICD或起搏器的患者不能选择CMR检查（但新型起搏器可进行CMR检查）。对于这些病人，CT可用于观察其形态学特征。

为了观察患者临床状态的变化，通常可以考虑重复进行超声心动图检查。一小部分患者射血分数逐步减低可以发展为左室扩张，可考虑每一至两年作顺序评估，即使在无症状患者。此外，超声心动图随访有助于评估室间隔消融术后室间隔厚度和左室内径和容积的变化，特别在有残余症状的患者。

要点:

1. 超声心动图是首选的评价心脏形态的影像学方法。
2. 超声心动图图像质量不佳，或对室壁厚度评价不完整和/或不满意时，推荐应用CMR。
3. 超声心动图质量不佳，或患者有CMR禁忌症如植入ICD或起搏器时，考虑心脏CT。
4. 影像报告应包括左室内径、室壁厚度（包括最大室壁厚度）、肥厚的形态及其严重程度和分布。

B. 左室收缩和舒张功能的评估

大多数患者应用超声心动图评估左室射血分数是可行的。图像不佳时应考虑CMR。当超声心动图成像不佳或有CMR禁忌症时，可以考虑放射性核素显像或心脏CT。超声心动图组织多普勒及斑点追踪技术和CMR可以测量心肌形变和扭转。目前，不推荐常规作应变和扭转的测量。但在了解HCM的病理生理学特征，以及治疗对心肌功能的影响方面，它仍是一个有用的研究工具。

绝大多数HCM有舒张功能障碍，由于超声心动图的多功能性和高时间分辨率，成为推荐的影像学方法。如最近ASE指南¹⁹所推荐，对大多数患者进行综合评估是可行的。报告中应综合考虑左室松弛、充盈、左房容积和肺动脉压力对舒张功能作出评价。CMR和放射性核素显像测量HCM患者的充盈速率，尽管可行，但仍有一定限制。

要点:

1. 超声心动图是首选的评价左室射血分数的影像学方法，报告中应包括EF。
2. 超声心动图图像质量不佳时推荐 CMR。
3. 超声心动图图像质量不佳或有 CMR 禁忌症时，考虑心脏 CT 或放射性核素成像评估射血分数。
4. 超声心动图是唯一推荐的评价左室舒张功能的方法，应根据最新 ASE 和欧洲超声心动图协会指南进行全面检查¹⁹。

C. 左室流出道梗阻的评价

在大约 70% 的患者，动力性左室流出道梗阻是由心肌肥厚和异常血流的共同作用所导致的，二尖瓣 SAM 征是一个重要征象。梗阻程度高度依赖于负荷量，前负荷降低（如低血容量）、后负荷降低或心肌收缩力增加时梗阻加重。非同日的左室压力阶差变化可以超过 30mmHg。

超声心动图是可用于评价动力性梗阻的血流动力学变化。脉冲多普勒可发现 LVOT 梗阻的位置，连续多普勒可以估测最大压力阶差，测量时需注意避开二尖瓣反流血流束。值得注意的是，动力性梗阻也可以发生于腔室中间水平和室间隔心尖部。对于压力阶差 < 30mmHg 的患者，进行激发试验很重要。许多患者做 Valsalva 试验（降低了前负荷）或亚硝酸戊酯吸入（降低了后负荷）后，可以记录到 LVOT 血流速度显著上升。对静息状态下无动力性梗阻，但有症状的患者进行超声心动图负荷试验很重要，因为运动诱导的压力阶差通常高于 Valsalva 动作所激发的。

对于能够运动的患者，应更多进行符合生理的跑步机负荷试验，因为它不仅可提供动力性梗阻的数据，而且提供了运动耐量和运动血压变化的数据¹²²。某些无法进行直立运动的患者，可考虑使用仰卧自行车负荷试验，可方便地测量静息和运动状态下的左室充盈压和肺动脉收缩压¹⁹。然而，由于仰卧位增加了静脉回心血量，仰卧位自行车试验也可增加 LVOT 压力阶差。虽然低剂量多巴酚丁胺（< 20mg/kg/min）超声心动图可以用于那些不能运动但有症状的患者（静息状态下没有压力梯度）的激发试验，但此类患者最好在更有经验的中心进行评估。这种激发方法类似于在导管室使用异丙肾上腺素引起动力性梗阻。药物激发试验必需仔细观察，以确保所观察到的多普勒信号不是由于心室腔闭塞而是由于 SAM 征象所引起。重要的是，识别和治疗可诱发的梗阻，可使超声心动图对运动耐量和血流动力学状态的定性和定量测量能力有所提高¹²³。

由于 CMR 的技术限制及相关经验有限，临床决策时仍推荐超声心动图多普勒

测量LVOT压力阶差，但CMR可考虑应用于更具有挑战的临床情况中，如怀疑有瓣下病变或此前已进行过干预的患者。

要点:

1. 超声心动图是推荐的检查方法，脉冲多普勒用于明确梗阻的部位，连续多普勒用于明确压力阶差。
2. 静息状态下压力阶差 $<30\text{mmHg}$ ，但有症状的患者，可以通过 Valsalva 动作、亚硝酸戊酯（可行的时候）激发后测量压力阶差，条件许可时可进行运动负荷（最好是跑步机运动）试验。
3. CMR 可考虑应用于更具有挑战性的临床情况中，如怀疑有瓣下病变或此前已进行过干预的患者。

D. 评估接受侵入性治疗的患者

对于有症状的患者，影像学的目标是描述导致SAM征象和左室流出道梗阻的三个因素之间的相互作用：室间隔厚度和偏移、二尖瓣和乳头肌的几何形状¹²⁴。虽然许多情况下二维经胸超声心动图足以描述，但三维超声心动图和CMR正迅速成为有用的辅助工具，尤其是对二尖瓣和乳头肌的形态学评估。一旦决定进行手术，术中TEE对手术规划非常重要，包括估计需要去除的心肌的量和二尖瓣前叶的长度。术后TEE对明确是否残存SAM征象、动力性梗阻（自发的或者使用异丙肾上腺素）和二尖瓣反流非常重要，涉及到是否需要进一步干预。

对于接受酒精室间隔消融的患者，超声心动图心肌造影是必要的，以帮助确定需要消融的室间隔节段，避免引起远端梗死。术后随访超声心动图可以评估左室肥厚、射血分数、舒张功能和二尖瓣反流。SPECT和LGE CMR可以用于明确室间隔消除术后疤痕的存在、分布和范围。CMR空间分辨率更高且可避免放射性同位素。但不推荐常规进行SPECT和CMR检查。CMR可以考虑用于超声心动图图像不佳或有残存梗阻时。

要点:

1. 室间隔消融治疗前推荐应用超声心动图评估室间隔厚度和二尖瓣及乳头肌形态。
2. 外科手术切除术中需要经食管超声心动图指导手术。推荐术后在手术室中作

经食管超声心动图以明确是否残存 SAM 征象、残余梗阻、二尖瓣反流和室间隔缺损。

3. 超声心动图经冠状动脉心肌造影是室间隔酒精消融术前所必需，有助于明确需要消融的室间隔部位，避免引起其他区域的梗死。

E. HCM 患者冠状动脉疾病的诊断

虽然负荷超声心动图可用于评估运动时特定区域的功能障碍，但是很少有研究明确其在 HCM 人群中的准确性。也有研究关注到负荷超声心动图在左室肥厚病人中敏感性较低，产生的室壁负荷也相对较低。血管扩张剂负荷试验结合 SPECT 也存在同样的局限。但负荷试验也可能发生假阳性结果，这是因为由于室间隔呈非对称性肥厚，其放射性计数原本是升高的，如以此部位作正常参照，则会得出假阳性结果。此外，真正的灌注缺损也可能是由于微血管病变和非心外膜冠状动脉疾病所导致。有时某些区域放射性计数的降低不合逻辑，但如果观察到门控研究中室壁活动仍正常，则可有助于避免得出错误结论。血管扩张剂结合的 CMR 负荷试验已经被应用于其他群体，但是此方法是否在 HCM 中有效，相关信息仍很少。CT 血管成像可直接评估冠状动脉，也可识别室间隔切除后冠状动脉循环的变化。

要点：

1. HCM患者有胸痛但冠状动脉疾病可能性很小时，可以考虑负荷SPECT。
2. 患者有胸痛且冠状动脉疾病中度可能时，推荐应用冠状动脉造影术，包括 CT 血管造影。

F. 筛查

要点：

1. 推荐超声心动图作为HCM一级亲属初次筛查的影像学方法。
2. 青年期应每年复查超声心动图，成人每 5 年复查一次。
3. 当超声心动图检查有技术困难，或超声心动图不能满意显示所有心肌时，考虑 CMR。

表 7 心脏猝死的危险因素

-
1. 室壁最厚处 $\geq 3\text{cm}$ 超声心动图、CMR、心脏 CT
 2. 终末期 HCM (EF $< 50\%$) 超声心动图、放射性核素血管显像、
CMR、心脏 CT
 3. 心尖部室壁瘤 超声心动图造影、CMR、心脏 CT
 4. 左室流出道压力阶差 $\geq 30\text{mmHg}$ 多普勒超声心动图
 5. 灌注缺损 SPECT (尽管一些研究提示与猝死无关)
 6. 冠状动脉血流储备减低 PET (数据仅限于小样本观察)
 7. LGE (存在和范围) CMR (尚无明确结论)

G. 影像学在识别高危险性猝死患者中的作用

目前认为重度左室肥厚是可被影像学识别的危险因素之一。室壁最厚处 $\geq 3\text{cm}$ 是其中的主要危险因素，这可以通过超声心动图、CMR、心脏 CT 检查明确。这些影像学方法也能识别其他亚型的高危 HCM，包括终末期的 HCM 和心尖部室壁瘤（表 7）。

超声心动图发现 LVOT 压力阶差 $\geq 30\text{mmHg}$ 者似乎死亡率较高¹²⁵。然而，由于压力阶差依赖于负荷水平，限制了它在临床中的应用。虽然 CMR 的 LGE 与临床危险和室性心律失常有关，但目前尚无法确定能否预测心脏性猝死。值得一提的是，关于 HCM LGE 的四个短期随访研究^{86, 88, 126, 127} 均未证实 LGE 是猝死的独立预测因子。这些研究使用了多项临床事件的组合作为研究的复合终点。此外，目前尚不清楚 LGE 是否需要达到一定量或者说存在一定“阈值”。我们认为目前数据尚不支持常规根据 LGE 检查的结果对 HCM 患者进行危险分层，以决定是否植入 ICD 进行一级预防。然而，当对部分患者猝死危险分层尚不确切时，LGE 可能有潜在的价值。

其它发现包括 SPECT 观察到的灌注缺损和 PET 观察到的冠状动脉血流储备减低，但只有少数几项小样本研究对此进行了报道。因此，写作小组推荐应用超声心动图明确室壁最大厚度、左室射血分数、是否存在心尖部室壁瘤及动力性梗阻的严重程度。当超声心动图图像不佳，或超声心动图不足以看清心肌节段时，建议进行 CMR 检查。

American Society of Echocardiography Clinical Recommendations for Multimodality Cardiovascular Imaging of Patients with Hypertrophic Cardiomyopathy

Endorsed by the American Society of Nuclear Cardiology, Society for Cardiovascular Magnetic Resonance, and Society of Cardiovascular Computed Tomography

Sherif F. Nagueh, MD, FASE, Chair,* S. Michelle Bierig, RDCS, FASE,* Matthew J. Budoff, MD,§ Milind Desai, MD,* Vasken Dilsizian, MD,† Benjamin Eidem, MD, FASE,* Steven A. Goldstein, MD,* Judy Hung, MD, FASE,* Martin S. Maron, MD,‡ Steve R. Ommen, MD,* and Anna Woo, MD,* *Houston, Texas; St. Louis, Missouri; Los Angeles, California; Cleveland, Ohio; Baltimore, Maryland; Rochester, Minnesota; Washington, District of Columbia; Boston, Massachusetts; Toronto, Ontario, Canada*

(J Am Soc Echocardiogr 2011;24:473-98.)

Keywords: Hypertrophic cardiomyopathy, Echocardiography, Nuclear imaging, Cardiovascular magnetic resonance, Cardiac computed tomography

From the Methodist DeBakey Heart and Vascular Center, Houston, Texas (S.F.N.); St. Anthony's Medical Center, St. Louis, Missouri (S.M.B.); Los Angeles Biomedical Research Institute, Torrance, California (M.J.B.); Cleveland Clinic, Cleveland, Ohio (M.D.); the University of Maryland School of Medicine, Baltimore, Maryland (V.D.); Mayo Clinic, Rochester, Minnesota (B.E., S.R.O.); Washington Hospital Center, Washington, District of Columbia (S.A.G.); Massachusetts General Hospital, Boston, Massachusetts (J.H.); Tufts Medical Center, Boston, Massachusetts (M.S.M.); and Toronto General Hospital, University of Toronto, Toronto, Ontario, Canada (A.W.).

The following authors reported no actual or potential conflicts of interest in relation to this document: Sherif F. Nagueh, MD, FASE, S. Michelle Bierig, RDCS, FASE, Matthew J. Budoff, MD, Milind Desai, MD, Vasken Dilsizian, MD, Benjamin Eidem, MD, FASE, Steven A. Goldstein, MD, Judy Hung, MD, FASE, Steve R. Ommen, MD, and Anna Woo, MD. The following author reported a relationship with one or more commercial interests: Martin S. Maron, MD, serves as a consultant for PGx Health.

Attention ASE Members:

The ASE has gone green! Visit www.aseuniversity.org to earn free continuing medical education credit through an online activity related to this article. Certificates are available for immediate access upon successful completion of the activity. Nonmembers will need to join the ASE to access this great member benefit!

Reprint requests: American Society of Echocardiography, 2100 Gateway Centre Boulevard, Suite 310, Morrisville, NC 27560 (E-mail: ase@asecho.org).

Writing Group of the *American Society of Echocardiography (ASE) †American Society of Nuclear Cardiology, ‡Society for Cardiovascular Magnetic Resonance, and §Society of Cardiovascular Computed Tomography.

0894-7317/\$36.00

Copyright 2011 by the American Society of Echocardiography.

doi:10.1016/j.echo.2011.03.006

TABLE OF CONTENTS

Abbreviations	474
Organization of the Writing Group and Evidence Review	474
1. Introduction	474
2. Echocardiography	474
A. Cardiac Structure	474
B. Assessment of LV Systolic Function	475
C. Assessment of LV Diastolic Function	477
D. Dynamic Obstruction and Mitral Valve Abnormalities	477
E. Mitral Regurgitation in HCM	480
F. Myocardial Ischemia, Fibrosis, and Metabolism	481
G. Guidance of Septal Reduction Procedures	481
i. Surgical Myectomy	481
ii. Alcohol Septal Ablation	481
iii. Permanent Pacing	483
H. Screening and Preclinical Diagnosis	483
3. Nuclear Imaging	484
A. Cardiac Structure	484
B. Radionuclide Angiography for LV Systolic Function	484
C. Radionuclide Angiography for LV Diastolic Function	484
D. Dynamic Obstruction and Mitral Valve Abnormalities	484
E. Mitral Regurgitation in HCM	484
F. Myocardial Ischemia, Fibrosis, and Metabolism	484
i. SPECT	484
ii. Positron Emission Tomography (PET)	485
iii. Imaging Metabolism	486
G. Guidance of Septal Reduction Procedures	486
H. Screening and Preclinical Diagnosis	486
3. Cardiovascular Magnetic Resonance	486
A. Cardiac Structure	486
B. Assessment of LV Systolic Function	487
C. Assessment of LV Diastolic Function	487

Abbreviations**ASE** = American Society of Echocardiography**CAD** = Coronary artery disease**CMR** = Cardiovascular magnetic resonance**CT** = Computed tomography**EF** = Ejection fraction**HCM** = Hypertrophic cardiomyopathy**ICD** = Implantable cardioverter-defibrillator**LA** = Left atrial**LGE** = Late gadolinium enhancement**LV** = Left ventricular**LVOT** = Left ventricular outflow tract**MCE** = Myocardial contrast echocardiography**RV** = Right ventricular**SAM** = Systolic anterior motion**STE** = Speckle-tracking echocardiography**SPECT** = Single photon-emission computed tomography**TEE** = Transesophageal echocardiography**3D** = Three-dimensional**TTE** = Transthoracic echocardiography**2D** = Two-dimensional

- D. Dynamic Obstruction and Mitral Valve Abnormalities 487
- E. Mitral Regurgitation in HCM 488
- F. Myocardial Ischemia, Fibrosis, and Metabolism 488
 - i. Ischemia 488
 - ii. Fibrosis 488
 - iii. Imaging Metabolism 489
- G. Guidance of Septal Reduction Procedures 489
- H. Screening and Preclinical Diagnosis 489
- 4. Cardiac Computed Tomography 489
 - A. Cardiac Structure 489
 - B. Assessment of LV Systolic Function 490
 - C. Assessment of LV Diastolic Function 490
 - D. Dynamic Obstruction and Mitral Valve Abnormalities 490
 - E. Mitral Regurgitation in HCM 490
 - F. Myocardial Ischemia, Fibrosis, and Metabolism 490
 - G. Guidance of Septal Reduction Procedures 490
 - H. Screening and Preclinical Diagnosis 491
- 5. Hypertrophic Cardiomyopathy Imaging in the Pediatric Population 491
- 6. Role of Imaging in the Differential Diagnosis of Hypertrophic Cardiomyopathy 491
- 7. Recommendations for Clinical Applications 492
 - A. Cardiac Structure 492
 - B. Assessment of LV Systolic and Diastolic Function 493
 - C. Assessment of LVOT Obstruction 493
 - D. Evaluation of Patients Undergoing Invasive Therapy 493
 - E. Diagnosis of CAD in Patients With HCM 494
 - F. Screening 494

- G. Role of Imaging in Identifying Patients at High Risk for Sudden Cardiac Death 494

The purpose of this document is to review the strengths and applications of the current imaging modalities and provide recommendation guidelines for using these techniques to optimize the management of patients with HCM. The recommendations are based on observational studies, sometimes obtained in a small number of patients, and from the clinical experience of the writing group members, given the scarcity of multimodality imaging comparative effectiveness studies. Notwithstanding these recommendations, the writing group believes that the selection of a given imaging modality must be individualized.

1. INTRODUCTION


HCM is the most common genetic cardiomyopathy. Across multiple geographies and ethnicities, the prevalence is approximately 0.2%.¹ HCM is transmitted in an autosomal dominant inheritance pattern. The natural history is benign in the majority of patients, with a near normal life span. However, adverse outcomes, including sudden cardiac death, lifestyle-limiting symptoms secondary to dynamic left ventricular (LV) outflow tract (LVOT) obstruction and/or diastolic filling abnormalities, atrial fibrillation, and LV systolic dysfunction, occur in some patients.¹

The clinical diagnosis of HCM is based on the demonstration of LV hypertrophy in the absence of another disease process that can reasonably account for the magnitude of hypertrophy present.¹ Many patients are diagnosed serendipitously when a cardiac murmur or electrocardiographic abnormality prompts echocardiographic evaluation. Others present with dyspnea, chest pain, and/or presyncope. Sudden cardiac death occurs in approximately 1% of patients with HCM each year, and detecting patients at risk for sudden cardiac death is one of the most challenging clinical dilemmas. At the current time, a set of clinical risk factors¹ and imaging results are considered in the context of each patient's specific circumstances to help each patient decide whether an implantable cardioverter-defibrillator (ICD) represents an appropriate choice for that patient.¹

The management of HCM is based on a thorough understanding of the underlying anatomy and pathophysiology. In addition, careful assessment for concomitant structural heart disease is crucial to allow appropriate patient selection for advanced therapies.

Various imaging modalities can be used to assess cardiac structure and function, the presence and severity of dynamic obstruction, the presence of mitral valve abnormalities, and the severity of mitral regurgitation, as well as myocardial ischemia, fibrosis, and metabolism. In addition, imaging can be used to guide treatment, screening and preclinical diagnosis and to detect phenocopies.

2. ECHOCARDIOGRAPHY**A. Cardiac Structure**

LV volumes and the pattern of hypertrophy can be well defined by echocardiography (Figure 1, Video 1  view video clip online, Table 1). Ventricular volumes in HCM are usually normal or slightly reduced. Traditionally, the biplane Simpson's method has been applied to the measurement of LV volumes and ejection fraction (EF).² Recently, real-time three-dimensional (3D) echocardiography has been shown to provide more accurate means of quantification,³ though there is a paucity of data on its accuracy in HCM. All imaging windows should be used to accurately define the areas of increased wall thickness. Hypertrophied segments often have slightly increased

ORGANIZATION OF THE WRITING GROUP AND EVIDENCE REVIEW

The writing group was composed of acknowledged experts in hypertrophic cardiomyopathy (HCM) and its imaging representing the ASE, the American Society of Nuclear Cardiology, the Society for Cardiovascular Magnetic Resonance, and the Society of Cardiovascular Computed Tomography. The document was reviewed by the ASE Guidelines and Standards Committee and four official reviewers nominated by the American Society of Nuclear Cardiology, Society for Cardiovascular Magnetic Resonance, Society of Cardiovascular Computed Tomography, and the American College of Cardiology Foundation.

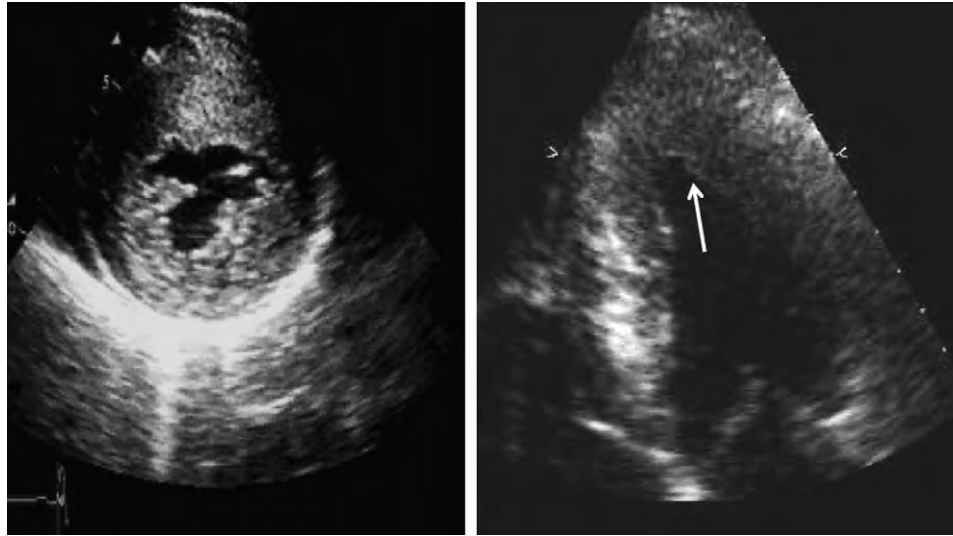


Figure 1 (Left) Parasternal short-axis view from a patient with severe asymmetric HCM involving the anterior septal and anterior lateral walls. (Right) Apical four-chamber view from a patient with apical HCM. The arrow points to the hypertrophy in the distal lateral wall.

Table 1 Echocardiographic evaluation of patients with HCM

1. Presence of hypertrophy and its distribution; report should include measurements of LV dimensions and wall thickness (septal, posterior, and maximum)
2. LV EF
3. RV hypertrophy and whether RV dynamic obstruction is present
4. LA volume indexed to body surface area
5. LV diastolic function (comments on LV relaxation and filling pressures)
6. Pulmonary artery systolic pressure
7. Dynamic obstruction at rest and with Valsalva maneuver; report should identify the site of obstruction and the gradient
8. Mitral valve and papillary muscle evaluation, including the direction, mechanism, and severity of mitral regurgitation; if needed, TEE should be performed to satisfactorily answer these questions
9. TEE is recommended to guide surgical myectomy, and TTE or TEE for alcohol septal ablation
10. Screening

brightness in comparison with segments having normal end-diastolic wall thickness.

LV hypertrophy, although usually asymmetric, can also be concentric. The distribution of hypertrophy can be in any pattern and at any location, including the right ventricle. Although septal predominance is more common, hypertrophy can be isolated to the LV free wall or apex (Figure 1). The presence of hypertrophy localized to the anterolateral wall can be missed, and careful imaging and extra care during interpretation are needed. When the extent of hypertrophy is difficult to visualize, having a high index of suspicion and meticulous imaging of the LV apex and/or the use of LV cavity opacification by intravenous contrast aids in the accurate diagnosis⁴ (Videos 2 and 3 [▶] view video clips online). In particular, apical HCM and apical aneurysms can be missed without contrast. Transthoracic echocardiography (TTE) combined with the intravenous injection of an echocardiographic contrast agent should be performed in patients with HCM with suspected apical hypertrophy, to define the extent of

hypertrophy and to diagnose apical aneurysms and clots.⁴⁻⁸ It is possible to express the severity of hypertrophy using semiquantitative scores,^{5,6} which are based on wall thickness measurements by two-dimensional (2D) imaging in parasternal short-axis views at end-diastole. In the presence of adequate-quality images and expertise, 3D echocardiography provides the most accurate echocardiographic approach for quantifying LV mass.

B. Assessment of LV Systolic Function

LV EF is usually normal or increased in patients with HCM and should be assessed in all imaging studies. Of note, patients with HCM with significant hypertrophy can have small LV end-diastolic volumes and therefore reduced stroke volumes despite having normal EFs. Overt LV systolic dysfunction, termed the “dilated or progressive phase of HCM,” “end-stage HCM,” or “burnt-out HCM,” is usually defined as an LV EF < 50% and occurs in a minority (2%–5%) of patients. Prognosis is markedly worse in the presence of LV systolic dysfunction.⁷ Likewise, the development of an apical aneurysm is an uncommon but important complication that can be readily recognized with contrast echocardiography.⁸

In addition to 2D and 3D imaging, Doppler methods have been used to assess for the presence of subclinical LV systolic dysfunction. Doppler tissue imaging measures the velocity of myocardial motion in systole and in diastole. Reduced systolic (Sa) and reduced early diastolic (Ea or e') velocities can occur before the onset of overt hypertrophy.^{9,10} Doppler tissue imaging can also be used to measure myocardial strain and strain rate, which unlike tissue Doppler velocities are not affected by translation and tethering. Strain rate imaging has been shown to be useful in differentiating nonobstructive HCM from hypertensive LV hypertrophy.¹¹ However, tissue Doppler–derived strain imaging has technical limitations due to its angle dependence. Speckle-tracking echocardiography (STE) directly assesses myocardial motion from B-mode (2D) images and is independent of angulation between the ultrasound beam and the plane of motion. Several studies have shown reductions in strain (Figures 2 and 3) in patients with HCM compared with controls.^{12,13} In terms of rotational motion, STE allows for quantification of the

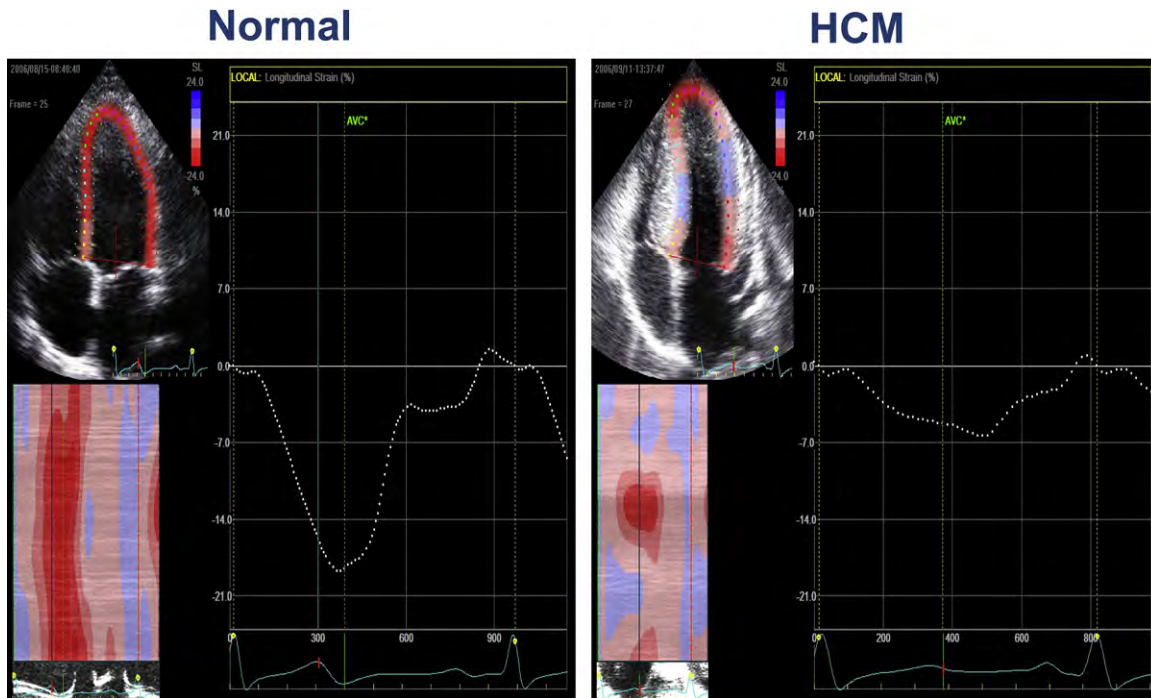


Figure 2 LV global longitudinal strain by STE in a control subject (*left*) and a patient with HCM and hyperdynamic left ventricle (*right*). LV global strain is markedly reduced at 7% in the patient with HCM. AVC, Aortic valve closure.

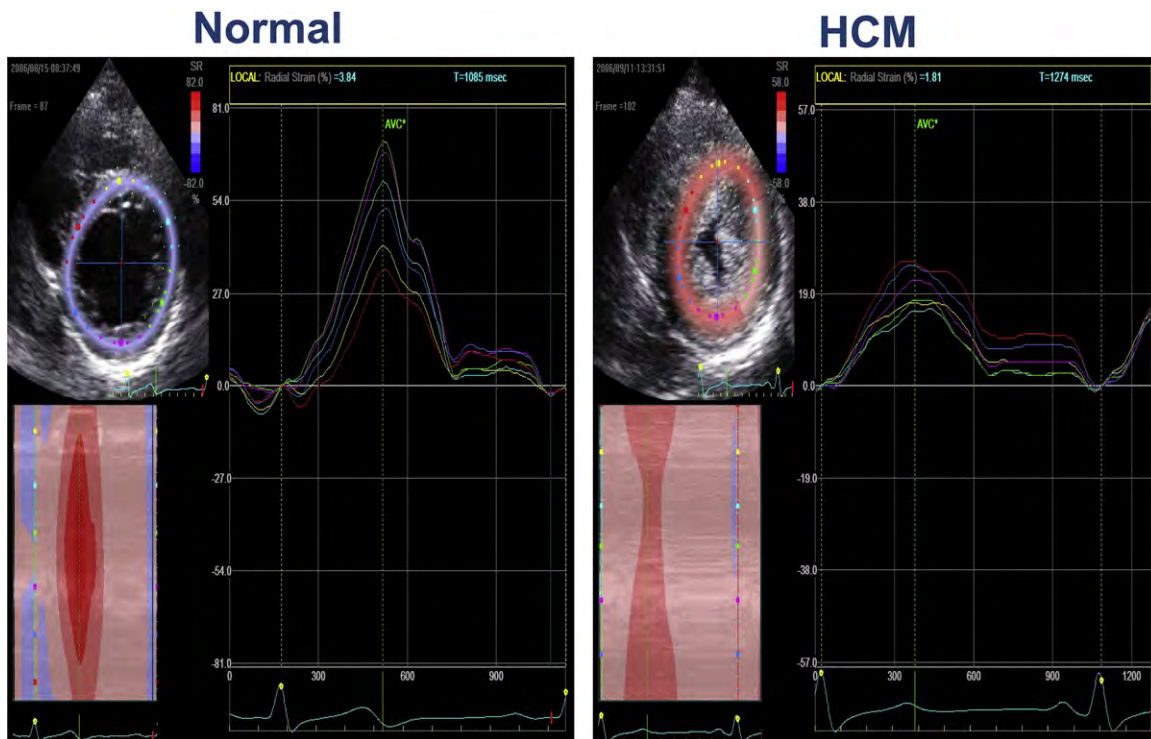


Figure 3 (*Left*) Radial strain in the LV short-axis view from six myocardial segments by STE in a control subject. (*Right*) Strain from a patient with HCM and hyperdynamic left ventricle. Radial strain is markedly reduced in all six segments in the patient with HCM. AVC, Aortic valve closure.

twisting (or wringing) motion of the heart. Observing LV torsion in normal subjects from an apical perspective, the base rotates clockwise while the apex rotates counterclockwise, creating a coordinated “wringing” motion of the left ventricle. Rotation

velocities of twisting and untwisting are usually similar in patients with HCM as a group and in control subjects (Figure 4), although individual variations exist. Although the extent of rotation is usually normal, there can be differences in the direction of rotation. For example,

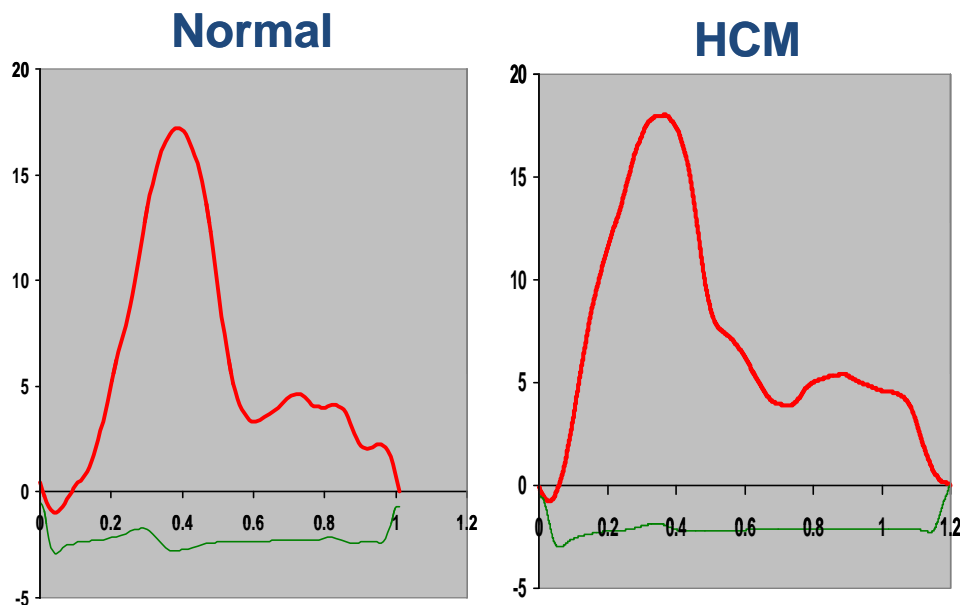


Figure 4 Twist by STE in a control subject (*left*) and a patient with HCM (*right*). Both exhibit an initial clockwise rotation followed by a counterclockwise rotation of 17°.

mid-LV rotation in patients with HCM occurs in a clockwise direction, opposite to the direction seen in normal subjects.¹³

Although STE is a promising method to evaluate myocardial function, there are significant differences between strain values across the 17 LV segments in normal individuals. Therefore, the variation of regional strain across the left ventricle necessitates the use of site-specific normal ranges, and the routine use of STE is not recommended at the present time.

C. Assessment of LV Diastolic Function

LV and left atrial (LA) filling abnormalities have been reported in patients with HCM irrespective of the presence and extent of LV hypertrophy. The assessment of LV diastolic function in HCM can be limited by the relatively weak correlations between the mitral inflow and pulmonary venous flow velocities and invasive parameters of LV diastolic function.^{14,15} However, the atrial reversal velocity and its duration (Figure 5) recorded from the pulmonary veins have a significant correlation with LV end-diastolic pressure.¹⁵

Previous studies have noted reasonable correlations between E/e' ratio and LV filling pressures.¹⁵ This was found across a wide range of annular velocities, including in patients in whom lateral annular e' velocity was >8 cm/sec (Figures 5 and 6). A recent study noted modest correlations in patients with HCM with severely impaired LV relaxation and markedly reduced annular velocities.¹⁶ The E/e' ratio has also been correlated with exercise tolerance in adults¹⁷ and children¹⁸ with HCM. In addition, septal e' velocity appears to be an independent predictor of death and ventricular dysrhythmia in children with HCM.¹⁸

A comprehensive approach is recommended when predicting LV filling pressures in patients with HCM,¹⁹ taking into consideration the above velocities and ratios, as well as pulmonary artery pressures and LA volume, particularly in the absence of significant mitral regurgitation and atrial fibrillation, as the latter two conditions lead to LA enlargement in the presence of a normal LA pressure.

LA size provides important prognostic information in HCM.²⁰⁻²² LA enlargement in HCM is multifactorial in origin, with important

contributions from the severity of mitral regurgitation, the presence of diastolic dysfunction, and possibly atrial myopathy,¹ because LA volume has been shown to be the more accurate index of LA size, LA volume indexed to body surface area should be assessed in accordance with ASE guidelines.²

There are three main mechanical functions of the left atrium: (1) reservoir function (during ventricular systole and isovolumic relaxation), (2) conduit function (during early diastole), and (3) contractile (booster pump) function (during atrial systole). The assessment of LA function via Doppler echocardiographic techniques has been performed by indirect methods using pulmonary venous inflow signals and LA volumes by 2D and 3D echocardiography during the different atrial phases.¹⁹ Other indirect measurements of LA function have included the calculation of LA ejection force and kinetic energy, which are increased in patients with obstructive HCM and are reduced (though not normalized) after relief of obstruction.²³

Strain imaging of the left atrium allows for more direct assessment of LA function. Longitudinal strain of the LA by tissue Doppler and 2D strain during all three atrial phases was assessed in HCM.²⁴ LA strain values were reduced in all three atrial phases and were significantly lower in patients with HCM compared with those with secondary LV hypertrophy. In general, 2D atrial strain is more reproducible and less time-consuming than tissue Doppler strain, but it is not recommended at the present time for routine clinical application.

D. Dynamic Obstruction and Mitral Valve Abnormalities

Primary structural abnormalities of the mitral valve apparatus in HCM include hypertrophy of the papillary muscles, resulting in anterior displacement of the papillary muscles, and intrinsic increase in mitral leaflet area and elongation.^{25,26} In addition, abnormalities of the mitral valve apparatus predispose the leaflets to be swept into the LVOT by drag forces created by a hyperdynamic EF.²⁷ This results in systolic anterior motion (SAM) of the mitral valve or chordate,

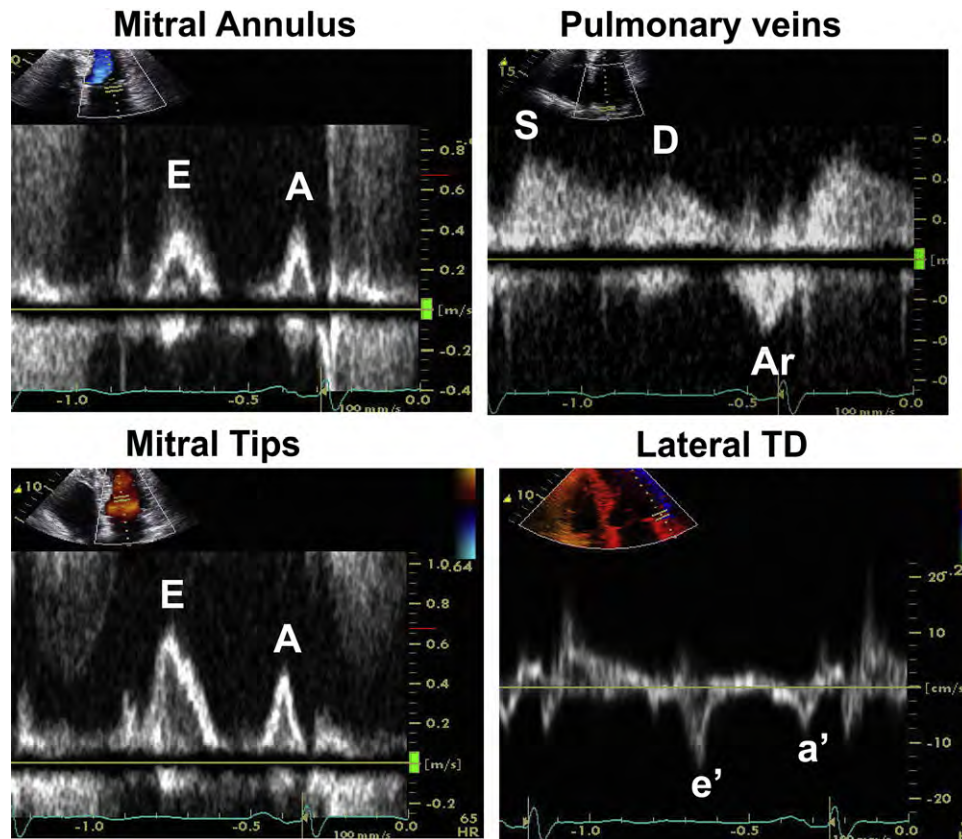


Figure 5 Assessment of LV diastolic function in a patient with HCM with elevated LV end-diastolic pressure but normal LA pressure. Mitral inflow shows a short mitral A duration at the level of the mitral annulus, whereas the Ar velocity in pulmonary venous flow is increased in amplitude and duration. Lateral annular e' velocity is normal, and the ratio of peak E velocity (at the level of mitral tips) to e' velocity is <8 , consistent with normal LA pressure. (Right) Tissue Doppler (TD) velocities. A, Peak mitral late diastolic velocity; a' , late diastolic TD velocity; Ar, atrial reversal signal in pulmonary veins; E, peak mitral early diastolic velocity; e' , early diastolic TD velocity; D, diastolic velocity in pulmonary veins; S, systolic velocity in pulmonary veins.

which is the mitral valve abnormality that is characteristic of obstructive HCM. Of note, significant obstruction is caused by valvular rather than chordal SAM. SAM is defined as systolic motion of the mitral leaflets into the LVOT (Figure 7) resulting in turbulent flow, appreciated as a mosaic pattern by color flow Doppler. SAM also results in distortion of mitral leaflet coaptation, resulting in mitral regurgitation (Figure 7). The maximal instantaneous gradient, reflecting the severity of LVOT obstruction, is determined by measuring the peak LVOT velocity. This is measured by continuous-wave Doppler. Care should be taken to avoid contamination of the LVOT signal with the mitral regurgitation jet (Figure 8).

Distinguishing a dynamic LVOT gradient from fixed LVOT obstruction by a subvalvular membrane is important. In addition, concomitant aortic valve stenosis should be excluded by examination of the aortic valve anatomy, including transesophageal echocardiography (TEE) if necessary, and the use of pulsed-wave Doppler at the aortic annular level, paying particular attention to early systole, as the aortic valve may demonstrate premature leaflet closure or fluttering due to the LVOT obstruction. Examination of the LVOT for diseases causing fixed obstruction, such as a membrane, is another important reason to consider TEE. These patients should be identified, as they are surgical candidates. Helpful clues for the presence of fixed subvalvular stenosis on TTE include an early peaking LVOT signal by continuous-wave Doppler similar to that of aortic stenosis, as well as aortic regurgitation,

which is uncommon in patients with HCM who have not had surgical myectomy.

Midcavitary obstruction can occur with and without LVOT obstruction in ventricles with hyperdynamic function and/or concentric hypertrophy. This is frequently observed in elderly patients with a sigmoid septum. The site of obstruction is determined by pulsed-wave and color Doppler showing high velocities at the site of obstruction (velocity aliasing by pulsed-wave Doppler). LVOT obstruction contributes to dynamic systolic dysfunction in obstructive HCM, as manifested by the midsystolic drop in LV ejection velocities at the entrance of the LVOT and the reduced longitudinal strain, both of which improve with treatment of obstruction.²⁷

A number of abnormalities contribute to SAM. These include the anterior displacement of the papillary muscles and the reduced posterior leaflet restraint. These mechanisms were highlighted in both in vitro and in vivo studies of mitral valve models that mimicked the anteriorly displaced papillary muscles in obstructive HCM.²⁸ Anterior displacement of the papillary muscles shifts the mitral leaflets anteriorly toward the LVOT and leads to chordal and leaflet laxity. As drag forces generated by the left ventricle pull the anteriorly displaced and elongated leaflets into the outflow tract in early systole, the distal one half to one third of the leaflets form an angle anteriorly into the LVOT, creating a "funnel" composed of both leaflets (Figure 7). The coaptation point between the anterior and posterior leaflets is

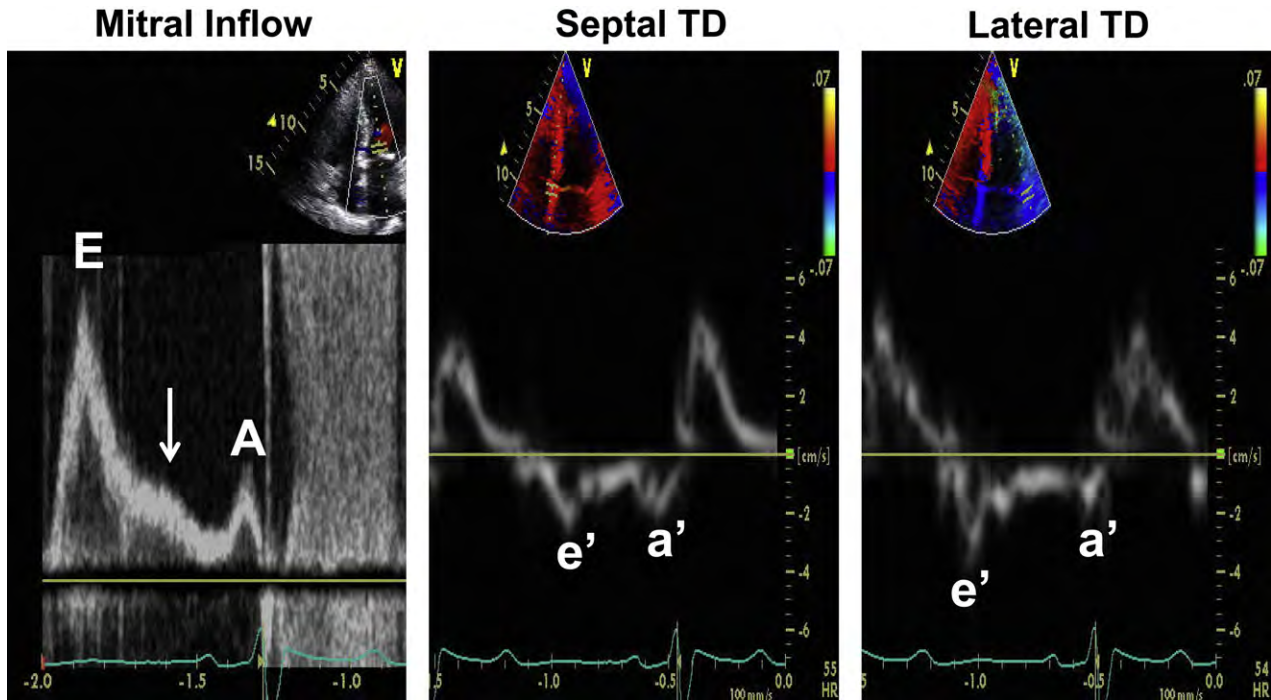


Figure 6 Assessment of LV diastolic function in a patient with HCM with elevated LA pressure. Mitral inflow shows a restrictive inflow pattern (E velocity, 140 cm/sec). The *arrow* points to an L velocity in mid-diastole, which is observed in the presence of impaired relaxation and increased filling pressures. Lateral annular and septal annular tissue Doppler (TD) velocities (both *e'* and *a'*) are markedly reduced consistent with severely impaired LV relaxation. The markedly increased E/*e'* ratio is consistent with increased LA pressure > 20 mm Hg. The reduced mitral A velocity with its short deceleration time and the severely reduced *a'* velocity are consistent with increased LV end-diastolic pressure. A, Peak mitral late diastolic velocity; *a'*, late diastolic TD velocity; E, peak mitral early diastolic velocity; *e'*, early diastolic TD velocity.

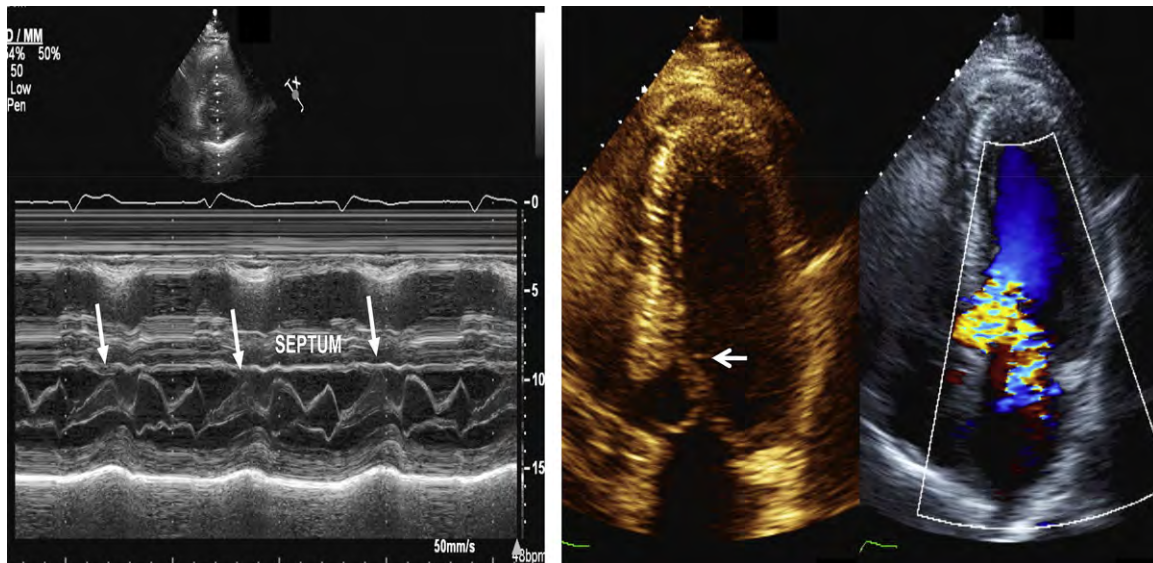


Figure 7 (Left) M-mode recording of SAM and mitral leaflet septal contact (*arrows*). (Right) SAM on 2D echocardiography (*arrow*). In the same panel, color Doppler shows the high velocities across the LVOT in mosaic color and the eccentric mitral regurgitation jet that is directed posterolaterally.

typically eccentric because of the greater anterior leaflet motion relative to the posterior leaflet.

The drag forces that create SAM play an important role in the generation of an LVOT gradient. The extent of septal hypertrophy and

resultant narrowing of the LVOT also contribute to the LVOT gradient. In addition to the role of drag forces on the mitral valve leaflets created by LV contraction, Venturi forces created as flow enters the narrowed LVOT may contribute to obstruction. But SAM often begins

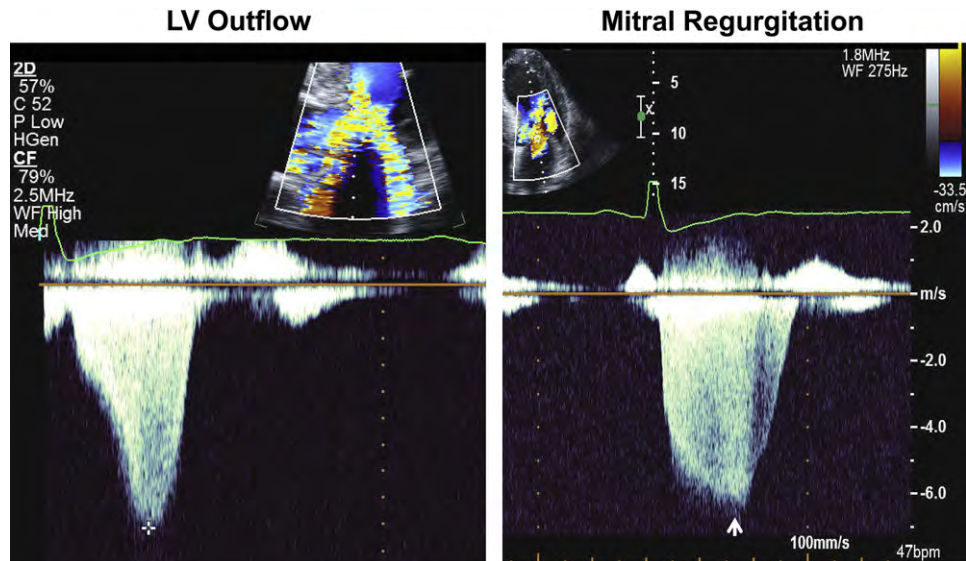


Figure 8 Continuous-wave (CW) Doppler recordings of peak velocity across the LVOT (cross: 4.5 m/sec) (left) and peak velocity of mitral regurgitation signal (arrow: 6.3 m/sec) (right). The concave-to-the-left contour of the Doppler CW jet causes a decrease in the LVOT orifice size as systole progresses and as the mitral valve is pushed further into the septum. Identification of this contour can be useful to differentiate high CW jets of dynamic LVOT obstruction from mitral regurgitation and from valvular aortic stenosis.

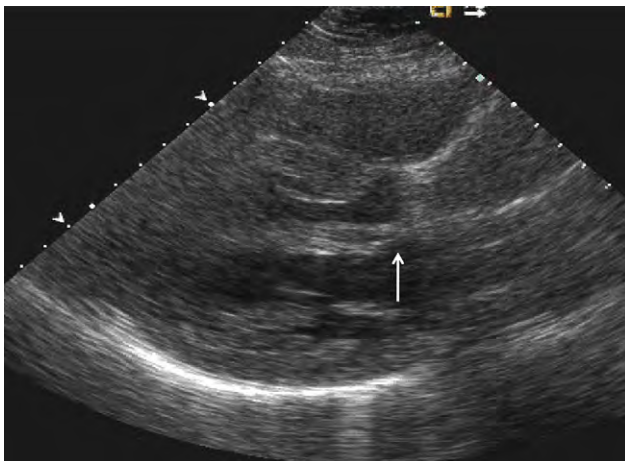


Figure 9 Anomalous insertion of the papillary muscle, which inserts directly into the anterior mitral leaflet (arrow).

before the aortic valve opens, at a time when LVOT velocities are low.²⁷ Moreover, the velocity of LVOT Doppler flow at SAM onset does not differ from velocities observed in the outflow tract of normal subjects. This indicates that though Venturi forces are present in the outflow tract, they are not a major contributor to SAM. Recognition by echocardiography of the importance of drag forces as the dominant cause of SAM led to a modification of myectomy, which is now extended past the tips of the mitral valve and in some cases to the base of the papillary muscles.

Anomalous insertion of the papillary muscles in which one or both heads of the papillary muscles insert directly (with absent chordae tendineae) into the ventricular aspect of the mitral leaflets can occur in up to 13% of patients with HCM and can contribute to LVOT obstruction (Figure 9, Video 4 [\[video clip online\]](#)). The recognition of these abnormalities can be facilitated using off-axis views and consideration of TEE if valvular pathology cannot be discerned. The

echocardiographic report should contain a clear statement about the papillary muscle size (if hypertrophy is present) and if there is direct insertion into the mitral leaflets contributing to LVOT obstruction.

E. Mitral Regurgitation in HCM

Because the anterior leaflet motion is greater than that of the posterior leaflet during SAM, an interleaflet gap occurs, resulting in a posteriorly directed jet of mitral regurgitation, which can be significant (moderate or greater depending on the extent of the gap). The gap is created between the leaflets because of the failure of the posterior leaflet to move toward the outflow tract as much as the anterior leaflet. This is because the anterior leaflet has the greater surface area and hence greater redundancy and mobility.²⁵ The degree of mitral regurgitation relates to the extent of mismatch of anterior to posterior leaflet length and the decreased mobility of the posterior leaflet to move anteriorly.²⁹ The mismatch can be quantified by measuring the coaptation length between the two leaflets, which is shorter with the above-described posterior leaflet abnormalities. Dynamic obstruction also affects the severity of mitral regurgitation,³⁰ such that mitral regurgitation is dynamic in HCM and is affected by the same factors that influence the severity of obstruction.

Not all mitral regurgitation associated with HCM is related to SAM. Patients with HCM can have intrinsic valvular abnormalities, such as mitral valve prolapse, leaflet thickening secondary to injury from repetitive septal contact or turbulent regurgitation jet, chordal rupture, chordal elongation or thickening, and infectious etiologies.³⁰ Importantly, the presence of a central or an anteriorly directed jet should prompt careful evaluation of the mitral valve apparatus by TEE to identify intrinsic valvular abnormalities.

There are specialized situations, such as in the operating room or intensive care unit, in which the pathophysiologic settings can mimic obstructive HCM. An example of this is the postoperative repair of a myxomatous mitral valve in a patient with basal septal hypertrophy or sigmoid septum, in which the left ventricle is underfilled coming off bypass. In this situation, a number of factors converge and produce

SAM along with LVOT obstruction. These include elongated mitral leaflets, a narrow LVOT, a small LV cavity, and hyperdynamic EF. In general, these can be reversed with volume loading, afterload increase, and stopping inotropic agents. Similarly, SAM with dynamic obstruction can be seen in patients on inotropic drugs, who are volume depleted, and in the elderly with basal septal hypertrophy or as part of the clinical presentation of stress-induced cardiomyopathy.

F. Myocardial Ischemia, Fibrosis, and Metabolism

In general, there is a limited role for echocardiography in diagnosing myocardial ischemia in HCM. Large areas of regional fibrosis can lead to segmental dysfunction manifested by reduced strain. However, a reduction in strain also occurs in segments without replacement fibrosis and has a reduced specificity for this diagnosis.

Measurement of coronary flow reserve in the left anterior descending coronary artery is feasible with transthoracic imaging. Abnormal flow reserve can be due to macrovascular and microvascular coronary artery disease (CAD). The technique requires experience, and an abnormal flow reserve has low positive predictive value in identifying patients with epicardial CAD. It is not yet feasible to use echocardiography for studying myocardial metabolism.

G. Echocardiography for Guidance of Septal Reduction Procedures

i. Surgical Myectomy. Direct cardiac visualization during myectomy is hampered by both the transaortic approach and the empty heart, potentially leading to imprecision in the extent of the myectomy. These limitations may result in either an inadequate resection, resulting in persistent LVOT obstruction, or too large a resection, which may inflict ventricular septal defect, complete heart block, or both. Therefore, intraoperative TEE has become an essential accompaniment to surgical myectomy, as it contributes to surgical planning, aids in determining the adequacy of repair, and detects complications.

Both the safety and efficacy of septal myectomy are improved with intraoperative TEE, which provides a road map of septal anatomy and geometry to the surgeon.^{25,30,31} Important information obtained from TEE includes the maximum thickness of the septum (Figure 10), the distance of maximum thickness from the aortic annulus, the location of the endocardial fibrous plaque (friction or impact lesion), and the apical extent of the septal bulge. Moreover, functional and intrinsic mitral valve abnormalities are well characterized by TEE. Importantly, TEE can identify mitral valve abnormalities and guide the necessary repairs or replacement.³² In particular, TEE can more clearly identify the direct insertion of papillary muscles into the middle or base of the anterior mitral leaflet. Surgical techniques have been developed to address this pathology and avoid postoperative residual obstruction, including the release and selective resection of anomalous papillary muscle connections. Also, selected patients coming to surgery have very long redundant mitral valve leaflets. In these selected patients, anterior mitral leaflet plication has been successfully used to limit SAM. Horizontal anterior leaflet plication has emerged as a safe and useful technique when used in selected patients who are identified preoperatively by echocardiography and in the operating room by direct inspection. It decreases leaflet length and slack and stiffens the leaflet against deformation. Immediately after cardiopulmonary bypass, TEE is repeated to assess evidence of residual obstruction, or more than mild mitral regurgitation, so that further resection or repair can be performed.

Uncommon complications, including iatrogenic ventricular septal defects, may occur, and immediate recognition by TEE can lead to successful repair. Although the exact mechanism is unknown, aortic regurgitation (usually of mild severity) can occur, perhaps due to direct injury to the leaflets or destabilization of the annulus by beginning the myectomy too close to the right coronary cusp.³²

ii. Alcohol Septal Ablation. Alcohol septal ablation is an alternative to surgery when medical therapy has failed or is not tolerated. This technique involves the injection of alcohol into a proximal septal perforator branch of the left anterior descending coronary artery to produce a localized myocardial infarction of the thickened proximal ventricular septum involved in causing dynamic obstruction (Figure 11). The use of myocardial contrast echocardiography (MCE) with the injection of echocardiographic contrast agent into the proposed target septal arteries to delineate the vascular distribution of the individual perforator branches is one of the important modifications to septal ablation and is key to the success of the procedure, as defined by at least a 50% reduction in LVOT gradient (Figure 12, Table 2).

Because there is considerable individual variation in the number, size, and vascular territory of the septal perforators, it is important to determine the vessel or vessels that should receive the alcohol injection. The initial method to identify the target septal perforator was to evaluate the gradient decrease during probatory balloon inflation. This has now been replaced at most centers by intraprocedural MCE under transthoracic or transesophageal echocardiographic guidance.^{33,34}

After the target septal perforator is identified and cannulated, a balloon catheter is advanced into the vessel and inflated to prevent backflow. Subsequently, 1 to 2 cm³ of a diluted echocardiographic contrast agent (e.g., Definity, Lantheus Medical Imaging, North Billerica, MA; Optison, GE Healthcare, Milwaukee, WI; Levovist, Berlex Laboratories, Montville, NJ) is injected through the balloon catheter followed by a 1-mL to 2-mL saline flush during continuous imaging. The contrast agent should be diluted with normal saline to optimize myocardial opacification and minimize attenuation.⁸ Details of the dilution vary with the contrast agent used. Agitated radiographic contrast can be used instead of an ultrasound contrast agent.⁸ The optimal target territory of the basal septum should also include the color Doppler region of maximal flow acceleration in the area of mitral leaflet and septal contact. Typically, MCE produces a demarcated area with increased echo density in the basal septum and an acoustic shadowing effect. In addition, it is important to document the absence of perfusion of myocardial segments remote from the targeted areas for ablation, including the LV anterior wall, right ventricular (RV) free wall, and papillary muscles.

In patients treated before the introduction of intraprocedural MCE, the main reason for unsatisfactory gradient reduction was suboptimal scar location. Intraprocedural guidance using MCE can lead to changes in the perforator vessel selected for ethanol injection³⁵ and even cancellation of the procedure, and some of these patients may be referred for surgery. This may be the case when the target septal perforator also supplies papillary muscles or in settings when it is not possible to cannulate the target septal vessel.

At most centers, TTE is used for intraprocedural guidance. Multiple views, including apical four-chamber and three-chamber views and parasternal short-axis and long-axis views, are recommended to delineate opacification of both target and nontarget regions. Limitations of TTE include the difficulty of continuous monitoring during the procedure and suboptimal images in the supine position on the

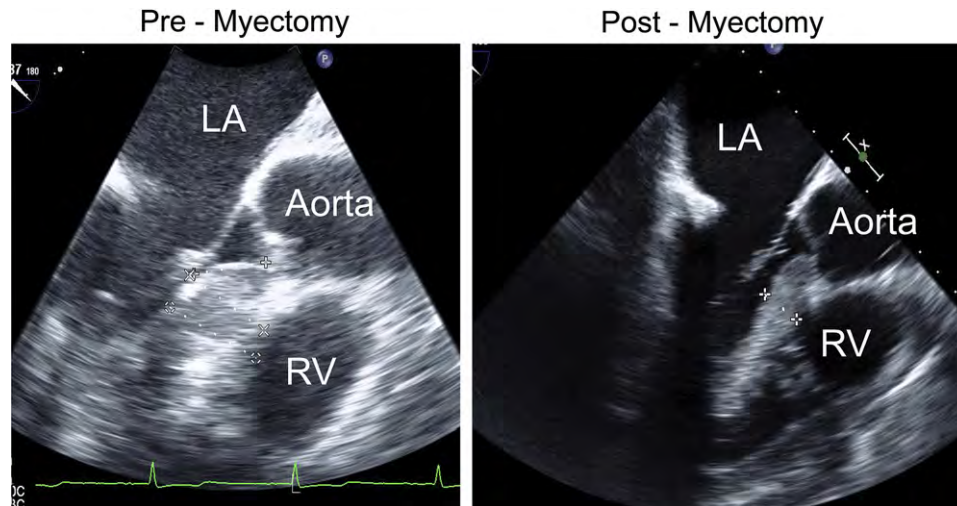


Figure 10 TEE of septal measurements before myectomy (*left*) (thickness, 2.9 cm) and after myectomy (*right*) (thickness, 1.5 cm). LA, Left atrium; RV, right ventricle.

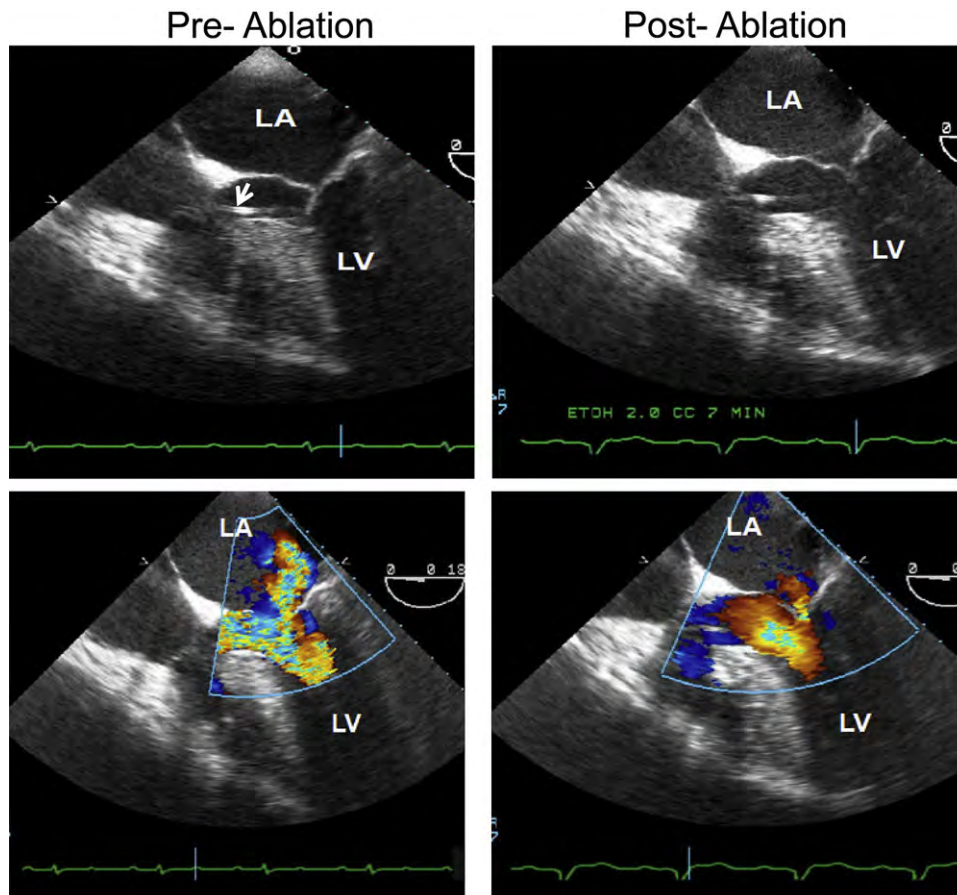


Figure 11 Transesophageal echocardiographic images from a patient who underwent alcohol septal ablation. Before ablation, 2D image shows narrowed LVOT with SAM (*top left*). (*Top right*) Two-dimensional images after ablation. Color Doppler before ablation shows high-velocity signals in mosaic color with eccentric mitral regurgitation directed posterolaterally (*bottom left*). After ablation, velocities are much lower across the LVOT, and mitral regurgitation appears trivial (*bottom right*). The arrow points to the catheter across the LVOT, which is used to measure LV pressure during the procedure. LA, Left atrium; LV, left ventricle.

catheterization table. Some groups prefer TEE because it generally provides higher quality images. TEE usually requires general anesthesia, which can alter loading conditions and therefore LVOT gradients.

If TEE is used, the apical four-chamber view (deep gastric at 0°) and longitudinal view (midesophageal, aortic valve level, 120°–130°) should be used. These views may be supplemented by the transgastric

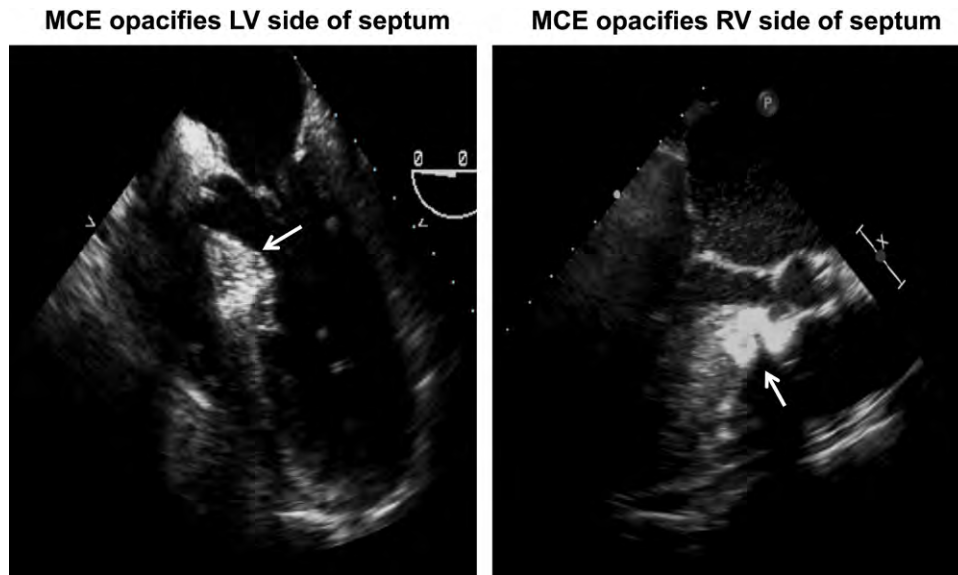


Figure 12 Myocardial contrast echocardiographic (MCE) images from two patients with HCM undergoing alcohol septal ablation. (Left) Opacification of the LV side of the basal septum (arrow), which is involved in the contact with the anterior mitral leaflet and the desired location to induce infarction. (Right) Opacification of the RV side of the septum (arrow), which is not the location that affects dynamic obstruction.

Table 2 Advantages of MCE during alcohol septal ablation

- | |
|------------------------------------|
| 1. Shorter intervention time |
| 2. Shorter fluoroscopy time |
| 3. Fewer occluded vessels |
| 4. Smaller amount of ethanol used |
| 5. Smaller infarct size |
| 6. Lower likelihood of heart block |
| 7. Higher likelihood of success |

short-axis view to assess for possible perfusion of the papillary muscles or the right ventricle.³⁶ The deep transgastric view is useful for measuring the intracavitary gradient with TEE, though it is usually more challenging than with TTE. There are preliminary data on intracardiac imaging during septal ablation.³⁷ Intracardiac imaging provides high-quality near-field imaging and can be performed by interventional cardiologists. Because of the complex nature of the LVOT anatomy, 3D echocardiography can provide additional information. However, the added benefit of 3D TEE during alcohol ablation has not yet been defined.

Intraprocedural echocardiography is also useful for evaluating the results of the procedure.^{36,38} The region of the basal septum, which is infarcted by the alcohol infusion, is typically intensely echo dense. This region of the septum should also have reduced thickening and excursion. There is usually a reduction or elimination of mitral regurgitation when it is due to SAM.³⁸ Most important, there should be elimination or reduction of dynamic obstruction.³⁸

iii. Permanent Pacing. Although pacing is no longer considered a primary treatment for most patients with obstructive HCM, it may be useful in select patients and is essential in a subset who develops high-grade atrioventricular block after septal reduction therapy. There is seldom need for echocardiographic guidance of pacemaker implantation. However, if there are doubts about whether the RV lead is positioned in the RV apex or there are concerns about

perforation, TTE should be performed.³⁹ Echocardiography is important for the evaluation and follow-up of response to this intervention and selection of the most optimal atrioventricular delay.³⁹

H. Screening and Preclinical Diagnosis

At the present time, echocardiography is the most practical technique for HCM screening. Although it is felt that the most active phase of hypertrophy development occurs during adolescence, it is appreciated that late-onset hypertrophy (into the fifth or sixth decade of life) can also occur. Therefore, periodic screening is recommended at intervals of every 12 months during adolescence and every 5 years in adults,⁴⁰ as well as at the onset of symptoms suggestive of HCM. All myocardial segments, not only the septum, should be carefully examined for evidence of hypertrophy on these screening examinations. Cardiovascular magnetic resonance (CMR) should be considered in patients with technically challenging echocardiograms, and in patients in whom electrocardiographic results is or have become abnormal, with still normal results on echocardiography.

Studies in transgenic animal models have noted the presence of abnormal myocardial function before the development of hypertrophy.⁴¹ These observations have led to the investigation of Doppler tissue imaging in the preclinical diagnosis of HCM in individuals carrying sarcomeric protein mutations encoding HCM. Some studies have shown annular e' velocity to be promising,^{9,10,42} whereas one study noted that a' velocity is abnormally reduced in preclinical HCM.⁴³ Limitations to this approach include the lower specificity in older individuals or those with coexisting disease. Furthermore, it is difficult to interpret Doppler data and provide counsel to subjects who carry the mutation but who still have normal velocity values. Given the variable penetrance, these subjects may never develop HCM including abnormal myocardial function. Alternatively, it is possible that the abnormality in cardiac function is present but at a mild degree that is not amenable to diagnosis by myocardial imaging. Therefore, abnormal Doppler velocities do not establish the diagnosis

Table 3 Nuclear imaging of patients with HCM

1. Myocardial perfusion
2. LV volumes and EF by radionuclide angiography and gated SPECT
3. Monitoring medical and nonmedical therapy for dynamic obstruction, when echocardiography and CMR are not available (changes in LV volumes, EF, and filling rates with medical and invasive therapy for dynamic obstruction)
4. Coronary flow reserve by PET
5. Cardiac metabolism by PET (research application)
6. Myocardial receptors and neurotransmission by SPECT or PET (research application)

of HCM but can help identify gene carriers who may benefit from closer follow-up.

3. NUCLEAR IMAGING

A. Cardiac Structure

Gated blood-pool radionuclide angiography can provide measurements of LV volumes and EF and RV volumes and EF. Thickened myocardium without a definable cause, usually in an asymmetric pattern with predominant septal involvement, can easily be identified by radionuclide angiography. Gated single photon-emission computed tomography (SPECT) can also provide similar data (Table 3). However, echocardiography and CMR have higher spatial resolution and provide accurate measurements. Accordingly, the use of nuclear imaging for the sole purpose of assessment of cardiac structure is no longer recommended.

B. Radionuclide Angiography for LV Systolic Function

Gated blood-pool radionuclide angiography provides reliable and reproducible measurements of LV EF in patients with HCM. In most patients, radionuclide angiographic findings suggestive of HCM include normal or supranormal EF, disproportionate septal thickening, and systolic ventricular cavity obliteration. A small subset of patients develop LV systolic dysfunction late in the course of disease; in such patients, EF falls below normal and can be easily detected by radionuclide angiography. However, the routine application of radionuclide angiography for the sole purpose of EF assessment is often not needed given the availability of echocardiography and CMR.

C. Radionuclide Angiography for LV Diastolic Function

Quantitative parameters of LV filling are derived from the time-activity curve, which closely approximates the changes in LV volume during diastole. High-temporal resolution methods are preferred to avoid underestimation of LV filling. Peak filling rate is the most widely used radionuclide angiographic parameter of diastolic function and represents the maximum value of the first derivative of the time-activity curve. Improvement in LV filling and reduction in symptoms have been observed after therapy with calcium channel blockers, such as verapamil,^{44,45} though these drugs can lead to aggravation of diastolic dysfunction in some patients with increased LV early diastolic filling parameters due to increased LV filling pressures.⁴⁶

Echocardiography, which allows beat-to-beat measurement of diastolic filling patterns as well as the less load dependent indices of LV relaxation, is the technique of choice for assessing diastolic function in HCM.

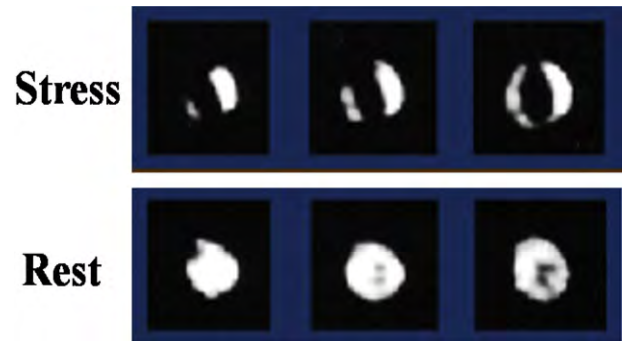


Figure 13 Three consecutive short-axis thallium tomograms from apex to base are displayed for stress (*top*) and rest reinjection (*bottom*) in a patient with HCM but not CAD. There are multiple exercise-induced thallium perfusion defects in the anterior, septal, and inferior regions that normalize on reinjection images (reversible defects), consistent with myocardial ischemia. In addition, there is apparent exercise-induced LV cavity dilatation with extensive hypertrophy.

D. Dynamic Obstruction and Mitral Valve Abnormalities

Nuclear techniques cannot show the presence of SAM or assess the severity and location of dynamic obstruction. However, the scan can show the presence of a hyperdynamic left ventricle with cavity obliteration.

E. Mitral Regurgitation in HCM

It is not possible to visualize the mechanisms behind mitral regurgitation using nuclear imaging. However, it is possible to quantify the severity of mitral regurgitation in patients with isolated lesions (i.e., no concomitant significant valvular regurgitation aside from mitral regurgitation) as the difference between LV and RV stroke volumes. Echocardiography is the recommended and preferred modality for that objective, given the limitations of the other techniques.

F. Myocardial Ischemia, Fibrosis, and Metabolism

i. SPECT. Ischemia in patients with HCM, in the absence of epicardial coronary artery stenosis, may be due to intramural small-vessel abnormalities, abnormal myocellular architecture, massive hypertrophy, and abnormalities of the intramural microcirculation leading to inadequate myocardial blood flow, particularly during increased myocardial oxygen demand with exertion. Myocardial oxygen demand is also increased by LV hypertrophy and outflow tract obstruction in many patients. Myocardial ischemia can be induced by exercise, vasodilators such as adenosine, and dobutamine. However, because of concerns of inducing and possibly aggravating the severity of dynamic obstruction with untoward hemodynamic effects, dobutamine is not preferred in conjunction with perfusion imaging in patients with HCM. The presence and severity of ischemia can be assessed by reversible abnormalities in regional thallium uptake (Figure 13) and is a well-established pathophysiologic feature of HCM in adults.⁴⁷⁻⁴⁹ It has been associated with potentially lethal arrhythmias, adverse LV remodeling, and systolic dysfunction, even in the absence of epicardial disease.^{49,50} In addition to the above mechanisms, impaired LV relaxation and increased LV end-diastolic pressure can compress the coronary microcirculation and further restrict coronary

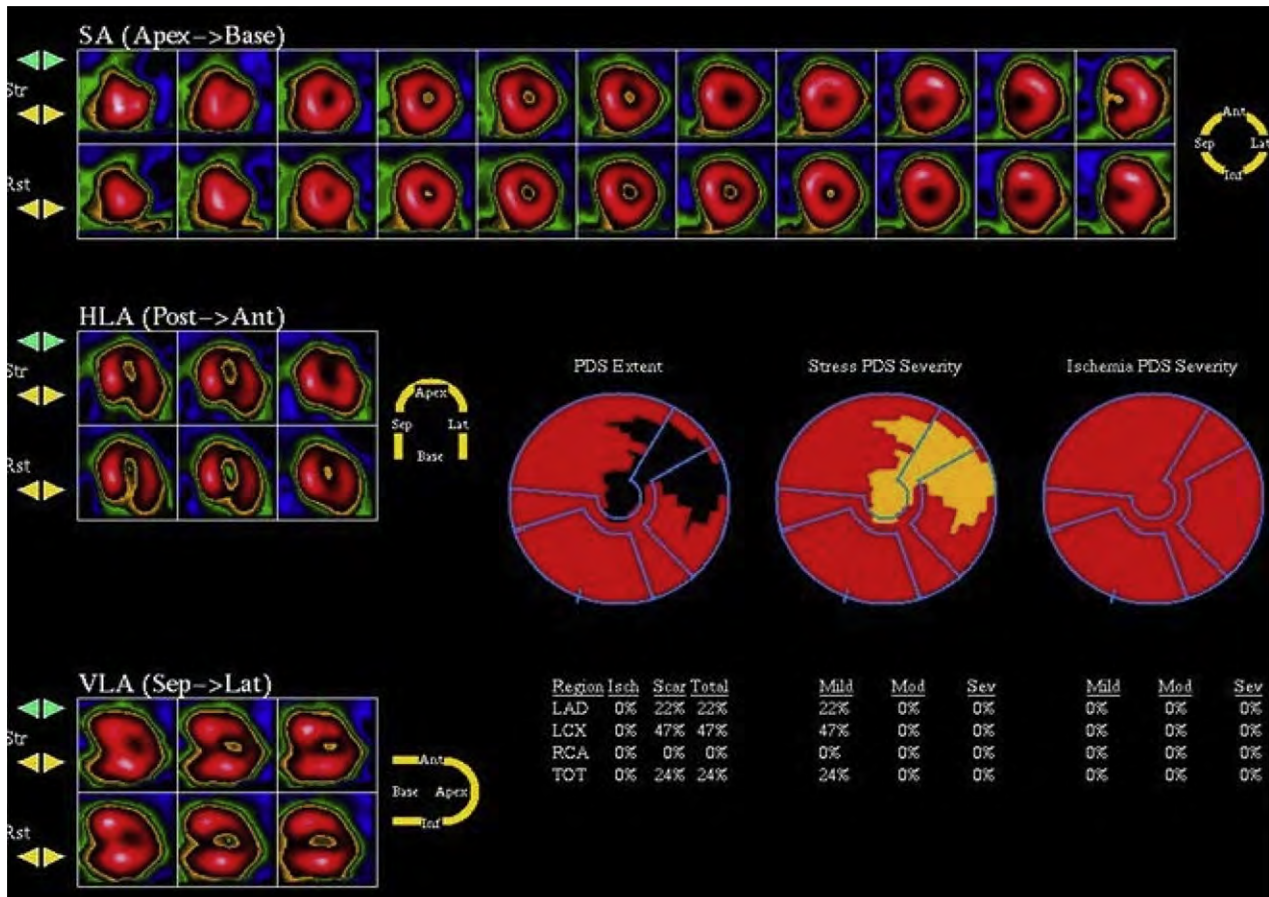


Figure 14 Single photon-emission computed tomographic perfusion imaging from a patient with HCM. Septal (Sep) thickness is increased, as is the count activity (*hot spot*) in the septum relative to lateral (Lat) wall. The computer analysis software registered a fixed perfusion defect (*scar*) (PDS) in the lateral and apical regions upon normalization to the septum. Ant, anterior; HLA, horizontal long-axis; LAD, left anterior descending coronary artery; LCX, left circumflex coronary artery; RCA, right coronary artery; TOT, total; VLA, vertical long-axis. Reproduced with permission from *J Am Coll Cardiol*.³⁹

artery blood flow.⁵⁰⁻⁵⁵ Recurrent myocardial ischemia can cause myocardial injury and scarring (characterized as fixed defects), which can potentially reduce the threshold for ventricular arrhythmias. In particular, fixed defects have been associated with syncope, larger LV cavity dimensions, and reduced exercise capacity.⁵⁶

In a selected group of young patients with HCM, sudden cardiac arrest or syncope was shown to be frequently related to myocardial ischemia.⁴⁹ However, the relation between ischemia and clinical events was not observed in all studies.⁵⁶ In addition, SPECT can have reduced specificity for diagnosing epicardial coronary lesions. False-positive results (Figure 14) without actual ischemia can occur because of increased radioactive isotope uptake in regions with hypertrophy (such as the septum) and the apparent lower counts in other segments compared with regions with segmental hypertrophy.³⁹ While routine performance of stress perfusion imaging in conjunction with SPECT is not recommended, on the other hand, in HCM patients with chest pain and low probability of CAD, stress SPECT imaging can be considered.

ii. Positron Emission Tomography (PET). Although SPECT cameras are more widely available for clinical studies in HCM

patients, the assessment of regional myocardial perfusion defects with SPECT is limited to assessing the distribution of the radiotracer in the myocardium in relative terms, rather than quantifying myocardial blood flow in absolute terms, in milliliters per minute per gram. Although the quantification of regional myocardial blood flow with PET has become an indispensable tool in cardiovascular research, it is used less frequently in clinical practice. The main drawbacks are the cost and accessibility of PET cameras as well as the radiotracers, which require either a cyclotron or an expensive generator for isotope production.

In patients with HCM with normal coronary arteries, myocardial perfusion positron emission tomographic studies have shown that although resting myocardial blood flow, in milliliters per gram per minute, may be similar to normal control subjects, the augmentation of blood flow with vasodilation (e.g., dipyridamole) may be significantly blunted. In addition, such abnormal myocardial blood flow reserve with vasodilation was shown to be more pronounced in the sub-endocardial regions, consistent with so called “apparent” transient ischemic cavity dilatation.^{52,55} Such quantifiable abnormalities in myocardial blood flow reserve, in the absence of epicardial CAD, could be attributed to myocardial ischemia from microvascular dysfunction and have prognostic importance.⁵⁰ Overall cumulative

survival free from unfavorable outcomes in these patients with HCM was associated with the level of hyperemic myocardial blood flow achieved during pharmacologic vasodilatation. Patients with HCM with the greatest attenuated myocardial blood flow responses to dipyridamole were more likely to subsequently develop LV remodeling, decreased LV EFs, and severe heart failure symptoms. In conclusion, routine positron emission tomographic screening of HCM patients for underlying myocardial ischemia cannot be advocated on the basis of the current literature but may be considered in selected patients with angina or heart failure, irrespective of LV EF.

iii. Imaging Metabolism. In the future, radiotracers that assess myocardial metabolism,⁵⁷ sympathetic innervations,⁵⁸⁻⁶⁰ and β -adrenergic receptor density⁶¹ may further elucidate the pathophysiology of HCM and its role in the progression of LV dysfunction and remodeling, the development of heart failure, and sudden cardiac death. However, the clinical utility of these radiotracers in HCM is currently preliminary and observational.

G. Guidance of Septal Reduction Procedures

Nuclear imaging is not needed for case selection for septal reduction therapy given its limitations with respect to imaging the mitral valve and the evaluation of dynamic obstruction, as discussed above. However, the technique has provided important insight into LV function and perfusion after these procedures.^{62,63} Among symptomatic patients with HCM who underwent myocardial perfusion SPECT before and after septal myectomy or mitral valve replacement, 85% had thallium perfusion defects before surgery, of whom 65% exhibited complete normalization or improvement in the magnitude and distribution of perfusion defects.⁵² This was associated with an improvement in lung uptake and transient cavity dilatation after the surgery.

When alcohol ablation was used for septal reduction, there was a decrease in LVOT gradient immediately after alcohol ablation, with the subsequent development of fixed septal perfusion defects in 97% of patients 6 weeks after treatment, without affecting LV EF.⁶² When the effect of alcohol septal ablation on septal perfusion defects and LV EF was examined 8 months after ablation, the basal septal perfusion defect decreased from 9.4% of the LV myocardium from early after alcohol ablation to 5.2%, without causing an increase in LV outflow obstruction or recurrence of symptoms.⁶³ The routine performance of nuclear imaging for the assessment of cardiac function post invasive therapy is not recommended unless there are technical limitations with echocardiography and CMR studies.

H. Screening and Preclinical Diagnosis

There is no role at the present time for nuclear imaging in the screening of patients for HCM and preclinical diagnosis.

3. CARDIOVASCULAR MAGNETIC RESONANCE

A. Cardiac Structure

CMR has emerged as an important 3D tomographic imaging technique, which provides images of the heart at high spatial and temporal resolution, in any plane and without ionizing radiation.⁶⁴⁻⁹¹ Current cine CMR imaging sequences are breath-hold and retrospectively or prospectively electrocardiographically gated acquisitions acquired in nearly identical imaging planes as that of 2D echocardiography.⁶⁶

Table 4 CMR imaging of patients with HCM

1. LV morphology including extent and distribution of hypertrophy
2. RV morphology
3. Mitral valve apparatus and papillary muscles
4. Global and regional LV function
5. Evaluation of LVOT obstruction (limited role in presence of echocardiography) and mitral regurgitation mechanism and severity
6. Myocardial ischemia evaluation with stress perfusion imaging
7. Contrast-enhanced CMR for focal fibrosis and differentiation of phenocopies
8. Monitoring of invasive therapy (myectomy and alcohol septal ablation)
9. Screening
10. Vascular-ventricular interactions

Furthermore, LV short-axis stacks are thin myocardial slices (typically 7 mm) providing complete tomographic coverage of the entire myocardium. Cine imaging sequences (without contrast injection) produce sharp contrast between the bright blood pool and the dark myocardium and therefore can provide detailed characterization of the HCM phenotype, including accurate wall thickness measurements⁶⁷⁻⁶⁹ and highly reproducible measurements of ventricular volumes and mass (Table 4).

CMR is particularly useful for characterizing the presence, location, and extent of LV hypertrophy in HCM (Figure 15), which can be limited to one or two LV segments in approximately 10% of the HCM population.⁶⁷ Although maximal LV wall thickness measurements are often similar between echocardiography and CMR, focal regions of increased wall thickness may not be well visualized by 2D echocardiography but can be detected by CMR in a subset of patients with HCM. The basal anterolateral free wall is one location in the left ventricle where hypertrophy may not be well seen by echocardiography, because the lateral epicardial border in this region is difficult to differentiate (because of the loss of spatial resolution) from the adjacent thoracic parenchyma in the short-axis orientation.⁶⁹ The LV apex is another region of the myocardium where CMR may provide an advantage over echocardiography in identifying hypertrophy.⁶⁸ Likewise, CMR can identify the presence of apical aneurysms in patients with HCM, which can have management implications.⁷⁵ CMR can also provide accurate characterization of the extent of LV hypertrophy. A recent study noted diffuse hypertrophy involving >50% of the left ventricle and eight or more segments in 54% of patients with HCM.⁶⁷ The technique is very helpful in the identification of segments with massive hypertrophy (>30 mm), which carries implications for ICD implantation. Therefore, CMR imaging should be considered in the evaluation of patients with HCM in whom the LV myocardium is not well visualized.

CMR in HCM has demonstrated that up to one third of patients have increased RV wall thickness and mass,⁷⁶ and if the septomarginal area is involved, RV outflow tract obstruction may be observed. Papillary muscle number and mass are also increased in patients with HCM.⁷⁷ Furthermore, there appears to be a small subset of patients with HCM in whom LV hypertrophy is focal and limited (with normal LV mass) but who demonstrate substantially hypertrophied papillary muscles. CMR assessment of papillary muscles has provided insight into the mechanism of outflow obstruction by demonstrating that the presence of an apically displaced anterolateral or double bifid

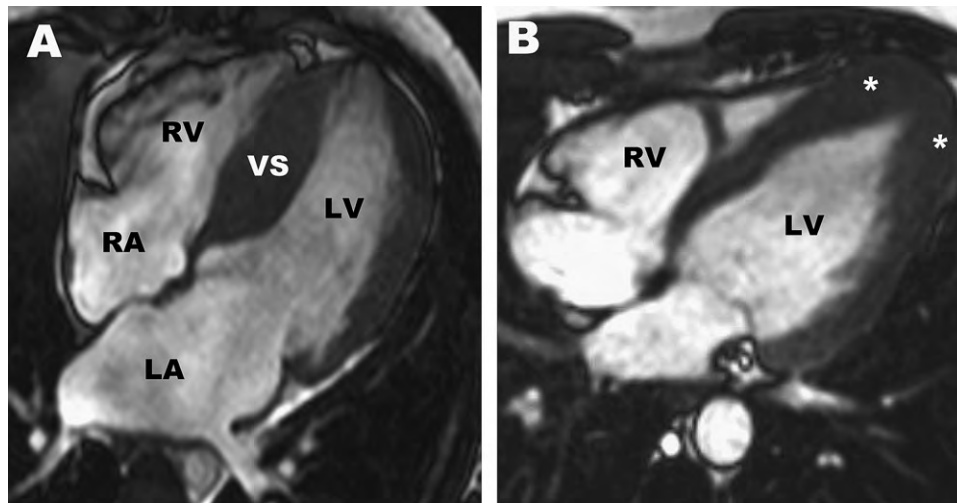


Figure 15 (A) Four-chamber end-diastolic CMR image of a 27-year-old asymptomatic patient with HCM with predominately ventricular septal hypertrophy (maximal wall thickness, 24 mm). (B) Four-chamber end-diastolic CMR image in a 16-year-old patient demonstrates increased left ventricular wall thickness confined to the apex (asterisks), consistent with a diagnosis of apical HCM. LV, Left ventricle; RA, right atrium; RV, right ventricle; VS, interventricular septum.

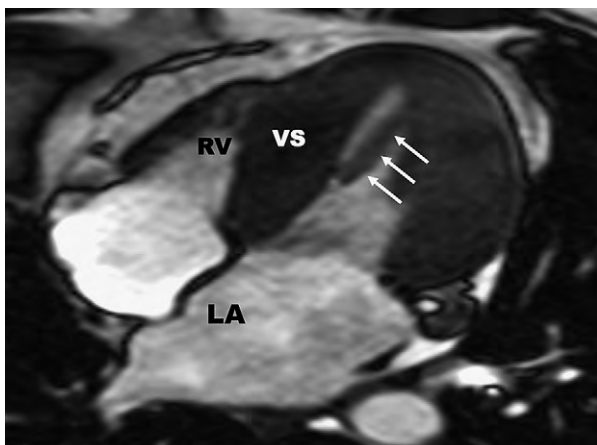


Figure 16 Apically displaced papillary muscle in HCM. Four-chamber midsystolic cine CMR image in a 44-year-old man with a resting LVOT gradient of 85 mm Hg and an apically displaced papillary muscle (arrows), which contributes to the mechanism of outflow obstruction by positioning the plane of the mitral valve closer to the ventricular septum. LA, Left atrium; RV, right ventricle; VS, interventricular septum.

papillary muscle is associated with a significantly higher likelihood of having a resting LVOT gradient⁷⁸ (Figure 16).

B. Assessment of LV Systolic Function

CMR measurements of ventricular volumes and EF are accurate and reproducible. In addition, quantitative measurements of regional systolic and diastolic function can be obtained using myocardial tagging methods.^{79,80} A limited number of studies using this technique in patients with HCM have confirmed that regional differences in myocardial function are present.⁷⁹ However, the clinical utility of myocardial tagging in discriminating HCM from forms of secondary hypertrophy (i.e., hypertensive cardiomyopathy or athlete's heart) or whether abnormalities identified by tagging are present before the development of LV hypertrophy has not been well established.

C. Assessment of LV Diastolic Function

It is possible to measure mitral inflow, pulmonary vein, and mitral annular velocities by CMR. Likewise, LV filling rates can be computed. However, the specific applications of these velocities by CMR in patients with HCM have not been evaluated, and this indication is not recommended at the present time.

With the increasing use of CMR, we are gaining further insights into the complex ventricular-vascular interactions in HCM. It was recently demonstrated that the LVOT and aortic root are oriented at a steeper angle to the left ventricle in patients with HCM compared with controls⁸¹ and that the angle was independently associated with the LVOT gradient. Recently, pulsed-wave velocity using phase-contrast CMR demonstrated increased aortic stiffness in patients with HCM in comparison with controls and that aortic stiffness was higher in patients with HCM with replacement fibrosis than in those without late gadolinium enhancement (LGE).⁸² Further work has demonstrated that increased aortic stiffness adversely affects exercise capacity, independent of LV morphology, diastolic function, and LVOT gradient.⁸³

D. Dynamic Obstruction and Mitral Valve Abnormalities

Cine CMR can accurately identify the presence of mitral-septal contact in both long-axis and basal short-axis images. Furthermore, a systolic signal void jet can often be observed in the region of mitral-septal contact, a result of high-velocity flow, supporting the presence of subaortic obstruction (Video 5 [▶] view video clip online). To characterize the magnitude of subaortic obstruction in HCM, phase velocity flow-mapping sequences can be applied to determine peak velocity through the LVOT. However, only a small number of studies have assessed the accuracy of CMR-derived LVOT velocities compared with continuous-wave Doppler-derived pressure gradients.⁸⁴ Therefore, it is uncertain how well CMR-derived outflow tract velocities correspond to those obtained by Doppler echocardiography.⁸⁵ In addition, a number of technical limitations related to the phase velocity flow-mapping sequence make it difficult to apply it reliably in clinical scenarios. At the present time, CMR-derived velocities can be assessed only under basal conditions, which represents a major limitation,

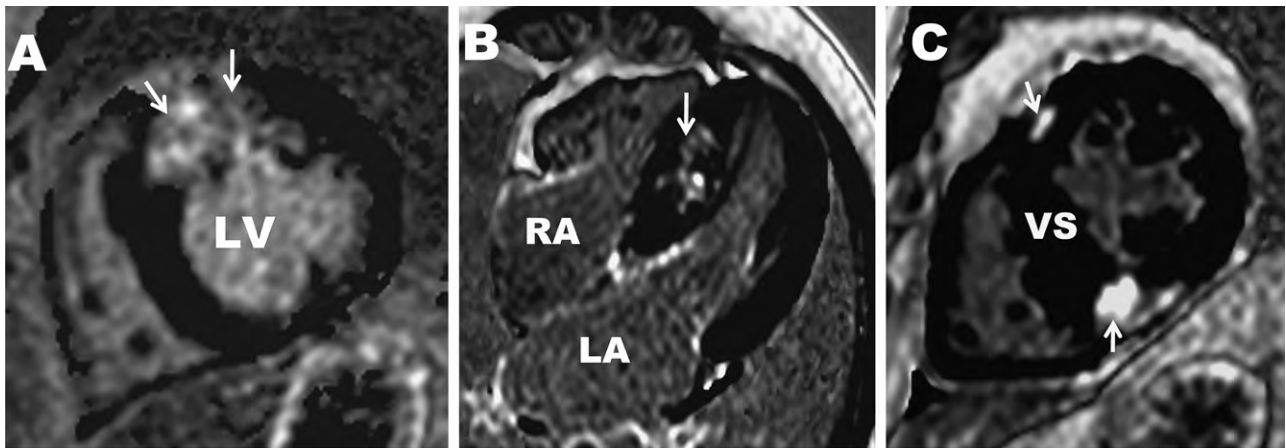


Figure 17 Contrast-enhanced CMR with LGE in HCM. **(A)** Asymptomatic 58-year-old woman with a large transmurular area of LGE in the basal anterior septum and anterior wall. **(B)** Diffuse and patchy area of LGE in the midmyocardial area of the ventricular septum in a 21-year-old man. **(C)** LGE confined to the area of RV free wall insertion into the anterior and posterior ventricular septum. *LA*, Left atrium; *LV*, left ventricle; *RA*, right atrium; *VS*, interventricular septum.

because one third of patients with HCM have outflow obstruction only during provocation. For these reasons, management decisions related to outflow obstruction should be predicated on pressure gradients derived from Doppler echocardiography.

E. Mitral Regurgitation in HCM

It is possible to visualize the mitral valve apparatus and assess the severity and mechanism of mitral regurgitation by CMR (Video 5), although formal quantification of the severity of mitral regurgitation is more commonly performed by echocardiography. CMR also can provide important information on the size and location of papillary muscles, as described above. These findings can be of potential value in planning surgery for the treatment of dynamic obstruction. Therefore, CMR should be considered in patients with HCM with suboptimal visualization of the mitral valve or papillary muscles by echocardiography, if patients decline TEE, or when the latter procedure is contraindicated.

F. Myocardial Ischemia, Fibrosis, and Metabolism

i. Ischemia. With the use of gadolinium-based contrast agents, myocardial blood flow under resting and stress conditions can be assessed using CMR.⁷⁰ Advances in CMR perfusion sequences now permit accurate qualitative and quantitative assessment of myocardial blood flow at rest and during pharmacologic stress (typically using adenosine). Stress CMR has demonstrated blunted myocardial blood flow in response to vasodilator stress in patients with HCM, which appears greater in the subendocardial layer in comparison with the subepicardial layer and is present in both hypertrophied and nonhypertrophied segments. There are currently no data relating CMR-derived measures of myocardial ischemia to clinical outcomes. Routine vasodilator stress CMR is not clinically recommended at this time.

ii. Fibrosis. Contrast-enhanced CMR with LGE sequences can detect areas of focally abnormal myocardial substrate in patients with HCM.^{72,74,86,88} Areas of LGE can be planimeted and the amount quantified and expressed as a percentage of total LV mass. Selected reports in native hearts after transplantation of patients with end-stage HCM have demonstrated concordance between *in vivo* LGE CMR images and gross and histopathologic evidence of fibrosis.⁸⁷

However, it still remains uncertain whether all LGE in patients with HCM with normal or hyperdynamic EF represents myocardial fibrosis. Similarly, the LGE technique misses background diffuse myocardial fibrosis changes, although new CMR techniques show promise in the quantification of diffuse myocardial fibrosis.

The prevalence of LGE in HCM is approximately 50% to 80% and when present occupies on average 10% of the overall LV myocardial volume.^{72,74,86,88} There is no specific pattern of LGE characteristic for HCM, although predominately the distribution of LGE in HCM does not correspond to a coronary vascular distribution, as in patients who have had myocardial infarctions. LGE is most often located in the ventricular septum but not uncommonly can be confined to only the LV free wall or insertion points of the RV free wall and ventricular septum (Figure 17).⁷⁴ LGE is more common in segments with hypertrophy and in patients with HCM with larger LV mass indices.^{72,74,86}

A number of studies have demonstrated a relationship between the extent of LGE and adverse LV remodeling associated with systolic dysfunction. The magnitude of LGE is greatest in patients with HCM in the end-stage phase of the disease (EF < 50%) and is less prevalent in patients with hyperdynamic EFs.^{72,74,86,88} However, it is still unclear if the extent of LGE can be used to prospectively identify patients with HCM at risk for progressing toward systolic dysfunction. Likewise, a number of cross-sectional studies have demonstrated a significant association between the presence of LGE and ventricular tachyarrhythmias (including rapid ventricular tachycardia) on ambulatory 24-hour Holter electrocardiography.^{71,73} However, it is not clear whether the extent of LGE provides greater predictive value in identifying patients with HCM at risk for sudden death compared with only the presence of LGE. Prognostic data with regard to LGE and cardiovascular outcome have now been evaluated in recent prospective short-term studies.^{86,88} In one of these studies, a statistically nonsignificant trend toward an increased adverse cardiovascular event rate was observed in patients with HCM with LGE.⁸⁶ A significant relationship was observed between LGE and either sudden death or appropriate ICD discharge⁸⁸ in a more recent study. However, given the small number of adverse events, it is necessary to obtain longer follow-up in larger study cohorts to have the statistical robustness necessary to determine if LGE is indeed an independent predictor of adverse events in HCM.

Therefore it is not recommended for routine clinical decision making at this time.

iii. Imaging Metabolism. Nuclear magnetic resonance has been used to evaluate myocardial metabolism in few patients with HCM.^{89,90} However, additional studies are needed to elucidate the pathophysiology of HCM and the development of progressive remodeling and heart failure as they relate to myocardial metabolism. Therefore, the clinical application of nuclear magnetic resonance in HCM is not recommended at the present time.

G. Guidance of Septal Reduction Procedures

CMR can identify accessory papillary muscles, which are thought to contribute to the obstruction and which require resection for optimal relief of outflow gradients. Therefore, CMR can be a useful guide for preoperative surgical planning. CMR short-axis and long-axis cine imaging can demonstrate the myectomy trough in the area corresponding to the site of resection.

Contrast-enhanced CMR can accurately quantify the amount of tissue necrosis after septal ablation as well as provide important information regarding the relationship between the location of scarring and LVOT morphology. On average, the amount of myocardial infarct produced is 10% of the total LV mass.⁹¹ CMR can determine the mechanism of suboptimal results after alcohol septal ablation, because in few patients, tissue necrosis involves predominately the RV side of the septum at the midventricular level, with septal thinning occurring distal to the area of mitral-septal contact, and resulting in the persistence of dynamic obstruction. CMR has demonstrated that LVOT gradient reduction after alcohol septal ablation results in LV remodeling associated with a reduction in mass of the ventricular septum and regions of myocardium remote from the area of infarction.⁹² The routine performance of CMR after septal reduction therapy is not recommended, but it can be of value in selected patients when questions arise about LV function and remodeling after the procedure that could not be satisfactorily answered by echocardiography, or when gradients recur late after the procedure.

H. Screening and Preclinical Diagnosis

A variety of potential morphologic abnormalities identified by CMR may be present in preclinical (genotype [+]/phenotype [–]) patients with HCM. Specifically, crypt formations localized predominately in the inferior septum have been demonstrated by CMR in preclinical patients, although the etiology of these structural abnormalities remains uncertain.⁹³ However, additional investigations are necessary to further clarify the prevalence and clinical significance of these CMR-derived morphologic abnormalities among preclinical patients with HCM, as some of these findings may be present in normal individuals.

At present, there are no systematic data evaluating the efficacy of CMR compared with echocardiography with regard to family screening for the detection of HCM. Given that CMR can identify LV hypertrophy not seen by echocardiography, CMR could still be considered in the evaluation of at risk family members, if there are suboptimal echocardiographic images, when all LV regions are not well visualized, when abnormal results of additional testing such as electrocardiography raise the suspicion of a diagnosis of HCM despite normal results on echocardiography, or in particularly high-risk family pedigrees in which a diagnosis of HCM remains equivocal but would have direct and immediate implications on treatment strategies such as implanta-

Table 5 Cardiac CT in patients with HCM

1. LV morphology in patients with suboptimal echocardiographic studies and who cannot undergo CMR (eg, because of ICD or pacemaker)
2. Computed tomographic angiography for CAD evaluation
3. Can provide information on coronary anatomy and mitral annulus if needed before and after septal ablation (usually not needed in the presence of echocardiography and CMR)

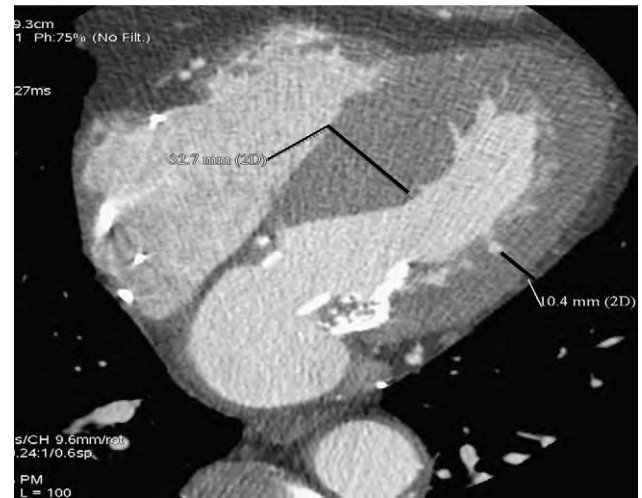


Figure 18 High contrast resolution on gated cardiac CT allows clear delineation of the myocardium, with sharp separation of contrast (white) and the myocardium (gray) and therefore can provide detailed characterization of the HCM phenotype. This patient with asymmetric septal hypertrophy had undergone pacemaker implantation, so CMR imaging was not possible. The lines and measurements refer to septal wall and lateral wall thickness.

tion of ICD for primary prevention of sudden death or exclusion from organized competitive sports.

4. CARDIAC COMPUTED TOMOGRAPHY

A. Cardiac Structure

Cardiac computed tomography (CT) is a 3D tomographic imaging technique that provides images of the heart with good spatial and temporal resolution.⁹⁴ Because of isotropic imaging, LV short-axis and long-axis views can be created in 0.4-mm thin slices, providing complete tomographic coverage of the entire myocardium (Table 5).

High contrast resolution allows clear delineation of the myocardium, with sharp separation of contrast (white) and the myocardium (gray), and therefore can provide detailed characterization of the HCM phenotype (Figure 18), including accurate wall thickness measurements and highly reproducible measurements of ventricular volumes, EF, and mass.^{95,96} The performance of 64-channel coronary computed tomographic angiography in patients with cardiomyopathy of uncertain etiology has been studied and compared with both CMR and invasive angiography,⁹⁷ but no studies systematically evaluating patients with HCM have been reported.

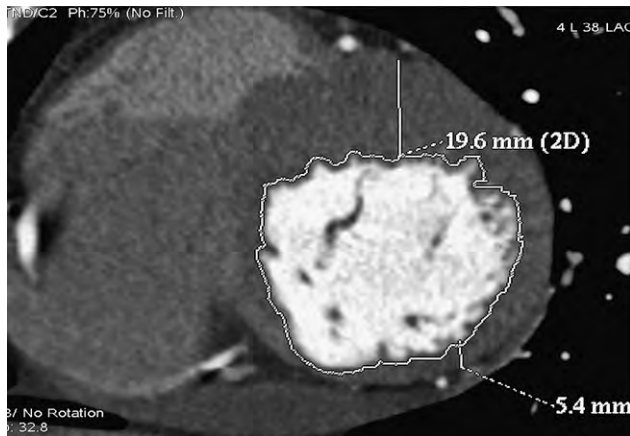


Figure 19 Short-axis cardiac computed tomographic image demonstrating asymmetric myocardial hypertrophy. The measurements shown are those of the anterior septum (19.6 mm) and inferolateral wall (5.4 mm).

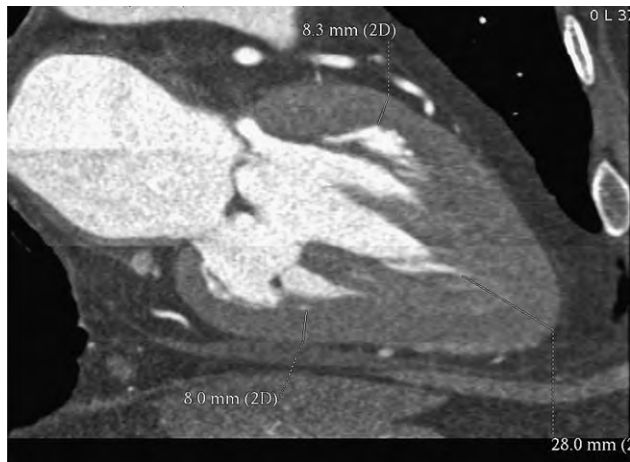


Figure 20 All cardiac structures including papillary muscles are well visualized in this contrast computed tomographic reconstruction, which demonstrates apical hypertrophy. The anterior and inferior walls have normal end-diastolic wall thickness (8.3 and 8 mm, respectively), while the apex shows severe hypertrophy (28 mm) on cardiac CT.

Cardiovascular CT permits the simultaneous imaging of the coronary arteries, the presence of myocardial bridging, RV and LV volumes and mass, and both global and regional function.^{98,99} All cardiac structures including papillary muscles are well visualized (Figure 19). Apical (Figure 20), septal, and papillary muscle hypertrophy can be readily delineated. CT provides accurate characterization of the extent of LV hypertrophy, including the identification of patients with marked hypertrophy (maximum wall thickness > 30 mm), which can be helpful for selection of patients for ICD therapy.

In summary, there are some advantages to cardiac CT in selected patients. Specifically, although poor acoustic windows may limit echocardiography, cardiac CT can reliably identify all LV segments and provide accurate measurements of wall thickness. Because of the higher spatial resolution of CT over CMR and echocardiography, it is at least equivalent or more likely superior with respect to volume

and mass measurements. However, CMR has superior tissue characterization capabilities.

At present, there are no systematic data evaluating the efficacy of cardiac CT compared with echocardiography or CMR with regard to evaluation or detection of HCM, so cardiac CT is generally not clinically recommended. Nevertheless, cardiac CT can be a useful modality in selected scenarios, including suboptimal echocardiographic images and when CMR is contraindicated (e.g., pacemaker or ICD implantation, when claustrophobia prohibits CMR, or when patients cannot hold their breath for long periods). In these scenarios, cardiac CT can be used, though the concern remains with higher radiation exposure with retrospective electrocardiographic gating, so prospective triggering should be used whenever possible.¹⁰⁰

B. Assessment of LV Systolic Function

Cardiac CT provides an accurate assessment of LV volumes and EF. However, there are no data on its specific application in HCM.

C. Assessment of LV Diastolic Function

Cardiac CT is not indicated at this time for the assessment of LV diastolic function, because of its limited temporal resolution.

D. Dynamic Obstruction and Mitral Valve Abnormalities

Cardiac CT has been used to evaluate the 3D shape, size, and motion of the mitral annulus¹⁰¹ and can delineate the presence of SAM of the anterior mitral valve leaflet in the multiphase images as well as the presence and extent of annular calcification.

Cardiac CT is not indicated at the present time for the evaluation of dynamic obstruction in patients with HCM, because of the ability to acquire such data by echocardiography and CMR without exposure to radiation.

E. Mitral Regurgitation in HCM

Papillary muscle abnormalities that affect mitral valve function can be assessed by CT. These abnormalities include the position and extent of hypertrophy of papillary muscles. However, the application of the technique for the assessment of mitral regurgitation in patients with HCM has not been evaluated.

F. Myocardial Ischemia, Fibrosis, and Metabolism

CT can readily image the coronary arteries, identify the presence, location, and extent of stenotic lesions, and identify the presence of myocardial bridging. It should be considered in the diagnostic workup of patients with HCM with chest pain who have intermediate to high probability of epicardial CAD. CT has no role at the present time for the evaluation of myocardial fibrosis and metabolism.

G. Guidance of Septal Reduction Procedures

CT can simultaneously image the length of the coronary arteries and the LV myocardium, allowing for the clear depiction of the relationship of the coronary arteries to the LV myocardium. This information can be useful for surgical myectomy and the planning and evaluation of alcohol septal ablation in HCM.¹⁰² Although this is a promising role, routine cardiac CT is not indicated at the present time for this objective.

H. Screening and Preclinical Diagnosis

There is no role at the present time for CT in the screening of patients for HCM and preclinical diagnosis.

5. HYPERTROPHIC CARDIOMYOPATHY IMAGING IN THE PEDIATRIC POPULATION

Two-dimensional echocardiography is the major diagnostic modality used in the noninvasive evaluation of HCM in the pediatric population.^{103,104} Anatomic and physiologic features of HCM that are the hallmarks of this disease in adults are also characteristically prominent in children, including asymmetric thickening of the ventricular myocardium, dynamic LVOT obstruction, systolic and diastolic ventricular dysfunction, SAM of the mitral valve and chordal apparatus, and variable degrees of mitral regurgitation. In both children and adults, the anatomic pattern of hypertrophy (the "septal curvature") has been shown to correlate with the presence of genetic mutation.¹⁰⁵

Echocardiography also plays a pivotal role in excluding other causes of hypertrophy. Children with congenital heart disease, including coarctation of the aorta and valvular or subvalvular aortic stenosis, often present with significant LV hypertrophy due to increased afterload. Systemic diseases in the pediatric population can elicit marked hypertrophy, including systemic hypertension, renal arterial stenosis, pheochromocytoma, and metabolic or storage diseases. Syndromes including Noonan syndrome, LEOPARD syndrome, and Friedreich's ataxia can also present with asymmetric or concentric forms of hypertrophy, mimicking sarcomeric HCM.

Recent studies have shown that LA volume has a similar association to disease severity in children with HCM, and is significantly related to the grade of diastolic dysfunction, clinical symptoms, and decreased exercise capacity.¹⁰⁶ After surgical myectomy in children with significant LVOT obstruction, LA volume has been shown to correlate with improved exercise performance and long-term outcomes.¹⁰⁷

Doppler echocardiography plays a major role in the evaluation of children with HCM. Routine pulsed-wave mitral inflow and pulmonary venous inflow Doppler reflects impaired myocardial relaxation. Reduced early transmitral filling, prolonged isovolumic relaxation time, and prolonged atrial reversal in pulmonary venous flow are all characteristic of abnormal diastolic function in pediatric patients with HCM. The presence of a mid-diastolic transmitral filling wave may also be present in patients with HCM with markedly impaired relaxation.¹⁰⁸ In children with HCM, annular systolic and early diastolic tissue Doppler velocities at the septal and lateral mitral annulus are significantly decreased.¹⁸ The septal E/e' ratio has been shown to be a clinical predictor of increased risk for death, cardiac arrest, or ventricular tachycardia in children with HCM. It correlated closely with clinical symptoms and was inversely related to peak oxygen consumption.¹⁸

Novel echocardiographic methods that evaluate myocardial deformation have been reported in healthy children^{109,110} and in young patients with HCM.^{111,112} Children with HCM demonstrate decreased systolic deformation, with the most marked abnormalities of strain and strain rate noted in the most hypertrophied myocardial segments. However, even myocardial segments without evidence of hypertrophy have impaired deformation compared with healthy controls. Similar analyses of myocardial deformation in children with varying etiologies of LV

hypertrophy demonstrate decreased systolic deformation regardless of the underlying etiology, suggesting that hypertrophy has more influence on myocardial deformation than the cause of the hypertrophy.

6. ROLE OF IMAGING IN THE DIFFERENTIAL DIAGNOSIS OF HYPERTROPHIC CARDIOMYOPATHY

The diagnosis of HCM is based on the presence of LV hypertrophy in the absence of another disease process that is capable of producing a similar magnitude of hypertrophy. Cardiac amyloidosis, glycogen-storage diseases, Anderson-Fabry disease, and Friedreich's ataxia can all cause hypertrophy but usually have concomitant noncardiac signs and symptoms that help steer the clinician toward the systemic disease process, including abnormally elevated creatine kinase, preexcitation pattern on electrocardiography, skeletal myopathy, skin involvement, or cerebral, cerebellar, or retinal disease or sensory-neural deficits. Cardiac morphology can also be helpful, because most of these other conditions produce concentric hypertrophy, while HCM produces asymmetric hypertrophy in most cases. LVOT obstruction is less common in these other conditions. CMR with gadolinium enhancement can facilitate identification of some of these systemic diseases. For example, adult patients with Anderson-Fabry disease have LGE confined largely to the basal inferolateral wall, which is unusual for sarcomeric HCM.¹¹³ Furthermore, CMR may also help clarify the diagnosis of LV noncompaction in patients initially diagnosed with (or presumed to have) apical HCM. CMR can demonstrate the presence of prominent trabeculations consistent with the diagnosis of LV noncompaction.¹¹⁴

It can be difficult to determine whether hypertrophy is due to hypertension or caused by HCM. However, hypertension usually results in concentric rather than asymmetric hypertrophy. It is also rare for hypertension to produce wall thickness in excess of 18 to 19 mm, whereas it is quite common for HCM patients to have wall thicknesses > 20 mm.

In some elderly subjects, discrete hypertrophy may be localized to the upper septum, with or without a sigmoid septal morphology. The latter is identified by a generally ovoid LV cavity and a concave septum toward the left ventricle, with a pronounced basal septal bulge. Sometimes, the sigmoid septum occurs in the presence of normal septal thickness. Although these patients can have dynamic obstruction, they are much less likely to have sarcomeric protein mutations.

A relatively common concern has to do with the differentiation of possible HCM from the physiologic myocardial hypertrophy that develops in response to intense athletic training.¹¹⁵ Because HCM is the most common cause of sudden death among athletes in North America, patients with HCM are counseled against participation in competitive athletics.^{1,116} However, the large body sizes of many advanced athletes and the potential for physiologic hypertrophy can result in a picture similar to HCM. Therefore, the implications of distinguishing these two situations are important. Studies of elite-level athletes have shown that it is quite rare (<1.5%) for even the most advanced athletes to demonstrate LV wall thicknesses > 12 mm.¹¹⁷⁻¹¹⁹ Another common morphologic feature of athlete's heart is chamber dilation, such that the end-diastolic dimensions are at or exceed the usual normal range,¹¹⁹ whereas patients with HCM have small LV cavity dimensions. The pattern of hypertrophy is usually concentric or eccentric in athletes.

Table 6 Summary of clinical applications

	Echocardiography	Nuclear imaging	CMR	Cardiac CT
1. LV dimensions, wall thickness	Recommended as initial test	Not recommended	Recommended with inadequate echocardiography	Rarely needed if echocardiography and CMR are not feasible
2. LV EF and regional function	Recommended as initial test	Not needed if echocardiography and CMR are available	Recommended with inadequate echocardiography	Not needed if echocardiography and CMR are available
3. LV filling pressures	Recommended	Not recommended as it provides only indirect evidence	Not recommended	Cannot be used for this purpose
4. Pulmonary artery pressure	Recommended	Cannot be used for this purpose	Cannot be used for this purpose	Cannot be used for this purpose
5. LA volume and function	Recommended	Cannot be used for this purpose	Recommended with inadequate echocardiography	Rarely needed if echocardiography and CMR are not feasible
6. Dynamic obstruction	Recommended	Cannot be used for this purpose	Recommended with inadequate echocardiography	Cannot be used for this purpose
7. Mitral regurgitation	Recommended	Not recommended	Recommended with inadequate echocardiography	Not recommended
8. Ischemia/CAD (if clinically indicated)	Considered if nuclear and CT not feasible	Recommended	Research application	Recommended if epicardial CAD in question
9. Cardiac metabolism and neurotransmission	Cannot be used for this purpose	Research application	Research application	Cannot be used for this purpose
10. Monitoring of invasive therapy	Recommended	Rarely needed if echocardiography and CMR are not feasible	Recommended with inadequate echocardiography	Rarely needed if echocardiography and CMR are not feasible
11. Image replacement fibrosis	Research application	Not recommended	Recommended test	Cannot be used for this purpose
12. Screening	Recommended	Not recommended	Recommended with inadequate echocardiography	Not recommended

Because HCM is a pathologic process, whereas athletic training results in physiologic adaptation, the goal of cardiac imaging is to look for other evidence of pathology that would favor the diagnosis of HCM. To this end, extreme LA enlargement and myocardial dysfunction (systolic and diastolic) do not occur in athlete's heart but are common features of HCM. Doppler tissue imaging,¹²⁰ coronary flow reserve,¹²¹ and gadolinium imaging have all been reported to allow distinction of athlete's heart from HCM. Ultimately, cessation of training can result in regression of hypertrophy in athletes, with no impact on wall thickness in patients with HCM.

The evaluation of aortic valve disease in patients with HCM with coexisting dynamic obstruction and aortic stenosis can be challenging with TTE. High-resolution transesophageal echocardiographic images can be used to measure the aortic valve area by planimetry.

7. RECOMMENDATIONS FOR CLINICAL APPLICATIONS

A. Assessment of Morphology

A comprehensive echocardiographic examination is the appropriate imaging modality to consider in patients with HCM (Table 6). The report should specifically include LV dimensions, wall thickness

(including end-diastolic thickness of the septum, inferolateral wall, and maximum thickness in any segment), pattern (asymmetric, concentric), and distribution of LV hypertrophy (segments involved and whether apical hypertrophy is present). Not infrequently, RV hypertrophy occurs as well, and RV wall thickness should be measured in subcostal or the parasternal images.² Contrast echocardiography, if needed, should be used as described above in the "Echocardiography" section. In most patients, this basic assessment can be readily obtained by echocardiography.

In patients with suboptimal images, CMR should be performed. In addition, CMR may be considered in the initial evaluation of patients when any segment of the LV myocardium is not well visualized by echocardiography. CMR is currently not a diagnostic option in patients with ICDs or pacemakers (but newer pacemakers may permit CMR evaluation). In these cases, cardiac CT can be used for morphologic characterization.

Repeat echocardiographic evaluation is usually considered with any change in clinical status. because a small subset of patients can develop progressive LV dilatation along with decreases in EF, serial assessment may be considered every 1 to 2 years, even in asymptomatic patients. In addition, it is useful to assess changes in septal thickness and LV dimensions and volumes after septal reduction therapy, particularly in patients with residual symptoms.

Key Points.

1. **Echocardiography is the initial imaging modality of choice for the evaluation of cardiac morphology.**
2. **CMR is recommended with suboptimal echocardiographic images and in patients with incomplete and/or unsatisfactory assessment of individual segmental wall thickness by echocardiography. CMR may be considered in selected patients with high index of suspicion for HCM.**
3. **Cardiac CT is recommended when echocardiographic images are inadequate and when CMR is contraindicated, as in patients with ICDs or pacemakers.**
4. **The imaging report should include measurement results of LV dimensions, wall thickness (including maximum wall thickness), and pattern of hypertrophy and its severity and distribution.**

B. Assessment of LV Systolic and Diastolic Function

Echocardiographic assessment of LV EF is feasible in most patients. CMR should be considered in patients with suboptimal images. In the presence of suboptimal echocardiographic images and a contraindication to CMR, radionuclide angiography or cardiac CT may be considered. Measurement of myocardial deformation and torsion is feasible with tissue Doppler and speckle tracking by echocardiography, as well as CMR. At the present time, routine measurement of strain and torsion is not recommended. However, it remains a useful research tool for understanding the pathophysiology of HCM and the effects of treatment on myocardial function.

The vast majority of patients with HCM have diastolic dysfunction, and echocardiography is the recommended imaging modality because of its versatility and high temporal resolution. A comprehensive assessment as recommended in the recent ASE guidelines¹⁹ is feasible in most patients. Conclusions should be included in the report as to the status of LV relaxation, filling pressures, LA volume, and pulmonary artery pressures. Filling rates, whether by CMR or radionuclide angiography, although feasible, have limitations in this population, as discussed above.

Key Points.

1. **Echocardiography is the initial imaging modality of choice for the evaluation of LV EF, which should be included in the report.**
2. **CMR is recommended with suboptimal echocardiographic images.**
3. **Cardiac CT or radionuclide angiography can be considered for EF assessment when echocardiographic images are inadequate and CMR is contraindicated.**
4. **Echocardiography is the only modality recommended for the evaluation of LV diastolic function, and a comprehensive approach should be followed per the recent ASE and European Association of Echocardiography guidelines.¹⁹**

C. Assessment of LVOT Obstruction

In approximately 70% of patients, dynamic LVOT obstruction due to the combination of hypertrophy, abnormal blood flow vectors, and SAM of the mitral valve is an important feature. Obstruction is highly load dependent and is augmented in states of reduced preload (as in hypovolemia), reduced afterload, or increased contractility. The day-to-day variability of LVOT gradient can exceed 30 mm Hg.

Echocardiography is the imaging modality of choice to assess the hemodynamics of dynamic obstruction. LVOT obstruction should be assessed by pulsed-wave Doppler to localize the site of obstruction

and continuous-wave Doppler to estimate the peak gradient, taking care to avoid the mitral regurgitation jet. Of note, dynamic obstruction can also occur at the midcavity level and at the ventricular apex. For patients with gradients < 30 mm Hg, it is important to perform provocative maneuvers. A significant increase in LVOT velocity can be recorded during the strain phase of the Valsalva maneuver (due to decreased preload) or with amyl nitrite, which decreases afterload in many patients. It is important to proceed to stress echocardiography on symptomatic patients without significant dynamic obstruction at rest, because exercise-induced gradients are often much higher than those provoked by the Valsalva maneuver.

For patients who can exercise, the more physiologic treadmill stress test should be performed, because it provides data not only on dynamic obstruction but also on exercise tolerance and the changes in blood pressure with exercise.¹²² Stress testing using supine bicycle protocols can be considered in selected patients who are unable to perform upright exercise and can facilitate the measurement of LV filling pressures and pulmonary artery systolic pressure at rest and during exercise.¹⁹ However, given the increased venous return in a supine position, LVOT gradients can be lower during supine bicycle protocols. Although low-dose dobutamine echocardiography (up to 20 $\mu\text{g}/\text{kg}/\text{min}$) can be used as a method of provocation for patients unable to exercise but with symptoms (in the absence of a gradient at rest), such patients are best assessed at more experienced centers. This method of provocation is similar to using isoproterenol in the catheterization laboratory to provoke dynamic obstruction. Pharmacologic provocation needs to be done with careful imaging to ensure that the observed Doppler signal is due not to cavity obliteration but to SAM. Importantly, identifying and treating provokable obstruction results in an improvement in qualitative and quantitative measurements of exercise tolerance and hemodynamic status.¹²³

Because of the technical limitations of CMR and limited experience, LVOT gradients by Doppler echocardiography are recommended for clinical decisions, but CMR may be considered in more challenging clinical scenarios, as in patients with suspected subvalvular pathology or those with previous intervention.

Key Points.

1. **Echocardiography is the recommended test. Pulsed-wave Doppler is used to localize site of obstruction, and continuous-wave Doppler is needed to determine peak gradient.**
2. **In symptomatic patients with LVOT gradients < 30 mm Hg at rest, gradients can be provoked by the Valsalva maneuver, amyl nitrite (when available), and if possible with exercise (preferably treadmill exercise).**
3. **CMR may be considered in more challenging clinical scenarios, as in patients with suspected subvalvular pathology or those with previous intervention.**

D. Evaluation of Patients Undergoing Invasive Therapy

In symptomatic patients, the goal of imaging is to characterize the interplay among the three entities resulting in SAM and LVOT obstruction: septal thickness and excursion and mitral valve and papillary muscle geometry.¹²⁴ Although 2D TTE is sufficient in many cases, 3D echocardiography and CMR are rapidly emerging as useful adjuncts, especially for the assessment of mitral valve and papillary muscle morphology. Once the decision has been made to proceed with surgery, intraoperative TEE is important for operative planning, including an estimate of the amount of myocardium that needs to be removed and the length of the anterior mitral leaflet. It is also

Table 7 Risk factors for sudden cardiac death

Risk factor	Imaging modality
1. Maximum wall thickness ≥ 3 cm	Echocardiography, CMR, cardiac CT
2. End-stage HCM (EF < 50%)	Echocardiography, radionuclide angiography, CMR, cardiac CT
3. Apical aneurysms	Contrast echocardiography, CMR, and cardiac CT
4. LVOT gradient ≥ 30 mm Hg	Doppler echocardiography
5. Perfusion defects	SPECT (though no association in some studies)
6. Reduced coronary flow reserve	PET (observations limited to very few patients)
7. LGE (presence and extent)	CMR (evidence not conclusive)

important after surgery to determine if residual SAM, dynamic obstruction (either spontaneously or using isoproterenol), and mitral regurgitation are present, which may necessitate further intervention.

For patients undergoing alcohol septal ablation, contrast echocardiography is essential to help identify the culprit septal segments and avoid inducing infarction in remote sites. Follow-up echocardiography after either procedure can be considered to assess the effects of either procedure on LV hypertrophy, EF, diastolic function, and mitral regurgitation. Both SPECT and LGE CMR can be used to determine the presence, distribution, and extent of scar after septal ablation. CMR has the advantage of better spatial resolution while avoiding radioactive isotopes. However, the routine performance of SPECT and CMR is not recommended. CMR can be considered in the presence of suboptimal echocardiographic images or in patients with residual obstruction.

Key Points.

- Echocardiography is recommended before septal reduction therapy to assess septal thickness and mitral valve and papillary muscle pathology.**
- In patients undergoing surgical myectomy, intraoperative TEE is needed to guide surgery. In the operating room after myectomy, TEE is recommended to determine the presence of SAM, residual obstruction, mitral regurgitation, and ventricular septal defects.**
- Intracoronary contrast echocardiography is essential before alcohol septal ablation to help identify the culprit septal segments and avoid inducing infarction in other sites.**

E. Diagnosis of CAD in Patients With HCM

Although stress echocardiography can be used to evaluate for regional dysfunction with exercise, there are few studies that have examined its accuracy in this population. There are also concerns about its lower sensitivity in patients with LV hypertrophy and potentially lower wall stress. The use of vasodilator stress testing in conjunction with SPECT does not have the same limitations of echocardiography. However, false-positive results can occur because of increased counts from the septum due to asymmetric hypertrophy and the approach of normalizing counts to this site. Furthermore, true perfusion defects can occur because of microvascular and not epicardial CAD. The presence of normal wall motion on gated studies in areas with spuriously low counts can help avoid erroneous conclusions. CMR stress testing with vasodilators has been applied in other populations, but there remains little information about the validity of this approach in HCM. Computed tomographic angiography provides a direct assessment of the coronary arteries and can identify changes in the coronary circulation after septal ablation.

Key Points.

- In patients with HCM with chest pain and low probability of CAD, stress SPECT can be considered.**
- Coronary angiography, including computed tomographic angiography, is recommended in patients with chest pain and intermediate pretest probability of CAD.**

F. Screening

Key Points.

- Echocardiography is recommended as the initial screening modality in first-degree relatives.**
- Echocardiography should be performed at yearly intervals during adolescence and every 5 years in adults.**
- CMR is indicated with technically challenging echocardiographic studies or when a complete satisfactory evaluation of all myocardial segments by echocardiography is not feasible.**

G. Role of Imaging in Identifying Patients at High Risk for Sudden Cardiac Death

Massive LV hypertrophy is among the currently recognized risk factors that can be identified by imaging. A maximum wall thickness ≥ 3 cm is one of the major risk factors and can be reliably obtained by echocardiography, CMR, and cardiac CT. These imaging modalities can also identify additional subgroups of patients with HCM who remain at high risk for events, including those with "end-stage" HCM and patients with apical aneurysms (Table 7).

The presence of an LVOT gradient ≥ 30 mm Hg on echocardiography has been associated with a higher likelihood of mortality.¹²⁵ However, the load-dependent labile nature of the gradient limits its utility in clinical practice. It is uncertain whether LGE on CMR predicts sudden cardiac death, though it has been associated with clinical risk factors and ventricular arrhythmias. Of note, none of the four short-term follow-up studies^{6,88,126,127} of LGE in HCM demonstrated that LGE is an independent predictor of sudden death. These studies used composite end points made up of a number of clinical events that were grouped. Furthermore, it is unclear whether the presence or a threshold amount of LGE is enough. It is our belief that the current data do not support routine LGE for risk stratification to make decisions about ICD therapy for primary prevention. However, LGE may be of potential value in selected patients when risk stratification for sudden cardiac death is not conclusive.

Perfusion defects on SPECT and reduced coronary flow reserve on PET are additional findings, though only a few studies in a small

number of patients have reported on these findings. Accordingly, the writing group recommends using echocardiography to determine maximum wall thickness, LV EF, the presence of apical aneurysm, and the severity of dynamic obstruction. CMR is recommended in patients with suboptimal images and when myocardial segments are not adequately visualized by echocardiography.

NOTICE AND DISCLAIMER

This report is made available by the ASE as a courtesy reference source for its members. This report contains recommendations only and should not be used as the sole basis to make medical practice decisions or for disciplinary action against any employee. The statements and recommendations contained in this report are primarily based on the opinions of experts, rather than on scientifically verified data. The ASE makes no express or implied warranties regarding the completeness or accuracy of the information in this report, including the warranty of merchantability or fitness for a particular purpose. In no event shall the ASE be liable to you, your patients, or any other third parties for any decision made or action taken by you or such other parties in reliance on this information. Nor does your use of this information constitute the offering of medical advice by the ASE or create any physician-patient relationship between the ASE and your patients or anyone else.

REFERENCES

1. Maron BJ, McKenna WJ, Danielson GK, Kappenberger LJ, Kuhn HJ, Seidman CE, et al. ACC/ESC clinical expert consensus panel on hypertrophic cardiomyopathy: a report of the American College of Cardiology Task Force on Clinical Expert Consensus Documents and the European Society of Cardiology Committee for Practice Guidelines (Committee to Develop an Expert Consensus Panel on Hypertrophic Cardiomyopathy). *J Am Coll Cardiol* 2003;42:1687-713.
2. Lang RM, Bierig M, Devereux RB, Flachskampf FA, Foster E, Pellikka PA, et al. Recommendations for chamber quantification: a report from the American Society of Echocardiography's Guidelines and Standards Committee and the Chamber Quantification Writing Group, developed in conjunction with the European Association of Echocardiography, a branch of the European Society of Cardiology. *J Am Soc Echocardiogr* 2005;18:1440-63.
3. Caselli S, Pelliccia A, Maron M, Santini D, Puccio D, Marcantonio A, et al. Differentiation of hypertrophic cardiomyopathy from other forms of left ventricular hypertrophy by means of three-dimensional echocardiography. *Am J Cardiol* 2008;102:616-20.
4. Olszewski R, Timperley J, Szmigielski C, Monaghan M, Nihoyannopoulos P, Senior R, et al. The clinical applications of contrast echocardiography. *Eur J Echocardiogr* 2007;8:S13-23.
5. Wigle ED, Sasson Z, Henderson MA, Ruddy TD, Fulop J, Rakowski H, et al. Hypertrophic cardiomyopathy: the importance of the site and the extent of hypertrophy. A review. *Prog Cardiovasc Dis* 1985;28:1-83.
6. Spirito P, Maron BJ. Relation between extent of left ventricular hypertrophy and occurrence of sudden cardiac death in hypertrophic cardiomyopathy. *J Am Coll Cardiol* 1990;15:1521-6.
7. Thaman R, Gimeno JR, Murphy RT, Kubo T, Sachdev B, Mogensen J, et al. Prevalence and clinical significance of systolic impairment in hypertrophic cardiomyopathy. *Heart* 2005;91:920-5.
8. Mulvagh SL, Rakowski H, Vannan MA, Abdelmoneim SS, Becher H, Bierig SM, et al. American Society of Echocardiography consensus statement on the clinical applications of ultrasonic contrast agents in echocardiography. *J Am Soc Echocardiogr* 2008;21:1179-201.
9. Nagueh SF, Bachinski LL, Meyer D, Hill R, Zoghbi WA, Tam JW, et al. Tissue Doppler imaging consistently detects myocardial abnormalities in patients with hypertrophic cardiomyopathy and provides a novel means for an early diagnosis before and independently of hypertrophy. *Circulation* 2001;104:128-30.
10. Cardim N, Perrot A, Ferreirat T, Pereira A, Osterziel KJ, Reis RP, et al. Usefulness of Doppler myocardial imaging for identification of mutation carriers of familial hypertrophic cardiomyopathy. *Am J Cardiol* 2002;90:128-32.
11. Kato TS, Noda A, Izawa H, Yamada A, Obata K, Nagata K, et al. Discrimination of nonobstructive hypertrophic cardiomyopathy from hypertensive left ventricular hypertrophy on the basis of strain rate imaging by tissue Doppler ultrasonography. *Circulation* 2004;110:3808-14.
12. Serri K, Reant P, Lafitte M, Berhouet M, Le Bouffos V, Roudaut R, et al. Global and regional myocardial function quantification by two-dimensional strain: application in hypertrophic cardiomyopathy. *J Am Coll Cardiol* 2006;47:1175-81.
13. Carasso S, Yang H, Woo A, Vannan MA, Jamorski M, Wigle ED, et al. Systolic myocardial mechanics in hypertrophic cardiomyopathy: novel concepts and implications for clinical status. *J Am Soc Echocardiogr* 2008;21:675-83.
14. Nishimura RA, Appleton CP, Redfield MM, Ilstrup DM, Holmes DR Jr, Tajik AJ. Noninvasive Doppler echocardiographic evaluation of left ventricular filling pressures in patients with cardiomyopathies: a simultaneous Doppler echocardiographic and cardiac catheterization study. *J Am Coll Cardiol* 1996;28:1226-33.
15. Nagueh SF, Lakkis NM, Middleton KJ, Spencer WH III, Zoghbi WA, Quinones MA. Doppler estimation of left ventricular filling pressures in patients with hypertrophic cardiomyopathy. *Circulation* 1999;99:254-61.
16. Geske JB, Sorajja P, Nishimura RA, Ommen SR. Evaluation of left ventricular filling pressures by Doppler echocardiography in patients with hypertrophic cardiomyopathy: correlation with direct left atrial pressure measurement at cardiac catheterization. *Circulation* 2007;116:2702-8.
17. Matsumura Y, Elliott PM, Virdee MS, Sorajja P, Doi Y, McKenna WJ. Left ventricular diastolic function assessed using Doppler tissue imaging in patients with hypertrophic cardiomyopathy: relation to symptoms and exercise capacity. *Heart* 2002;87:247-51.
18. McMahon CJ, Nagueh SF, Pignatelli RH, Denfield SW, Dreyer WJ, Price JF, et al. Characterization of left ventricular diastolic function by tissue Doppler imaging and clinical status in children with hypertrophic cardiomyopathy. *Circulation* 2004;109:1756-62.
19. Nagueh SF, Appleton CP, Gillebert TC, Marino PN, Oh JK, Smiseth OA, et al. Recommendations for the evaluation of left ventricular diastolic function by echocardiography. *J Am Soc Echocardiogr* 2009;22:107-33.
20. Nistri S, Olivotto I, Betocchi S, Losi MA, Valsecchi G, Pinamonti B, et al, on behalf of the Participating Centers. Prognostic significance of left atrial size in patients with hypertrophic cardiomyopathy (from the Italian Registry for Hypertrophic Cardiomyopathy). *Am J Cardiol* 2006;98:960-5.
21. Woo A, Williams WG, Choi R, Wigle ED, Rozenblyum E, Fedwick K, et al. Clinical and echocardiographic determinants of long-term survival after surgical myectomy in obstructive hypertrophic cardiomyopathy. *Circulation* 2005;111:2033-41.
22. Losi MA, Betocchi S, Barbati G, Parisi V, Tocchetti CG, Pastore F, et al. Prognostic significance of left atrial volume dilatation in patients with hypertrophic cardiomyopathy. *J Am Soc Echocardiogr* 2009;22:76-81.
23. Nagueh SF, Lakkis NM, Middleton KJ, Killip D, Zoghbi WA, Quinones MA, et al. Changes in left ventricular filling and left atrial function six months after nonsurgical septal reduction therapy for hypertrophic obstructive cardiomyopathy. *J Am Coll Cardiol* 1999;34:1123-8.
24. Paraskevidis IA, Panou F, Papadopoulos C, Farmakis D, Parisis J, Ikonomidis I, et al. Evaluation of left atrial longitudinal function in patients with hypertrophic cardiomyopathy: a tissue Doppler imaging and two-dimensional strain study. *Heart* 2009;95:483-9.

25. Grigg LE, Wigle ED, Williams WC, Daniel LB, Rakowski H. Transesophageal Doppler echocardiography in obstructive hypertrophic cardiomyopathy: clarification of pathophysiology and importance in intraoperative decision making. *J Am Coll Cardiol* 1992;20:42-52.
26. Klues HG, Maron BJ, Dolla AL, Roberts WC. Diversity of structural mitral valve alterations in hypertrophic cardiomyopathy. *Circulation* 1992;85:1651-60.
27. Sherrid MV, Wever-Pinzon O, Shah A, Chaudhry FA. Reflections of inflections in hypertrophic cardiomyopathy. *J Am Coll Cardiol* 2009;54:212-9.
28. Levine RA, Vlahakes GJ, Lefebvre X, Guerrero JL, Cape EG, Yoganathan AP, et al. Papillary muscle displacement causes systolic anterior motion of the mitral valve. Experimental validation and insights into the mechanism of subaortic obstruction. *Circulation* 1995;91:1189-95.
29. Schwammenthal E, Nakatani S, He S, Hopmeyer J, Sagie A, Weyman AE, et al. Mechanism of mitral regurgitation in hypertrophic cardiomyopathy: mismatch of posterior to anterior leaflet length and mobility. *Circulation* 1998;98:856-65.
30. Yu EH, Omran AS, Wigle D, Williams WC, Siu SC, Rakowski H. Mitral regurgitation in hypertrophic obstructive cardiomyopathy: relationship to obstruction and relief with myectomy. *J Am Coll Cardiol* 2000;36:2219-25.
31. Ommen SR, Park SH, Click RL, Freeman WK, Schaff HV, Tajik AJ. Impact of intraoperative transesophageal echocardiography in the surgical management of hypertrophic cardiomyopathy. *Am J Cardiol* 2002;90:1022-4.
32. Smedira NG, Lytle BW, Lever HM, Rajeswaran J, Krishnaswamy G, Kaple RK, et al. Current effectiveness and risks of isolated septal myectomy for hypertrophic obstructive cardiomyopathy. *Ann Thorac Surg* 2008;85:327-46.
33. Nagueh SF, Lakkis NM, He ZX, Middleton KJ, Killip D, Zoghbi WA, et al. Role of myocardial contrast echocardiography during non-surgical septal reduction therapy for hypertrophic obstructive cardiomyopathy. *J Am Coll Cardiol* 1998;32:225-9.
34. Faber L, Seggewiss H, Gleichmann U. Percutaneous transluminal septal myocardial ablation in hypertrophic obstructive cardiomyopathy: results with respect to intra-procedural myocardial contrast echocardiography. *Circulation* 1998;98:2415-21.
35. Faber L, Ziemssen P, Seggewiss H. Targeting percutaneous transluminal septal ablation for hypertrophic obstructive cardiomyopathy by intraprocedural echocardiographic monitoring. *J Am Soc Echocardiogr* 2000;13:1074-9.
36. Kuhn H, Gietzen FH, Schafers M, Freick M, Gockle B, Strunk-Muller C, et al. Changes in the left ventricular outflow tract after transcatheter ablation of septal hypertrophy (TASH) for hypertrophic obstructive cardiomyopathy as assessed by transesophageal echocardiography and by measuring myocardial glucose utilization and perfusion. *Eur Heart J* 1999;20:1808-17.
37. Pedone C, Vijayakumar M, Lighthart JMZ, Valgimigli M, Biagini E, De Jong N, et al. Intracardiac echocardiographic guidance during percutaneous transluminal septal myocardial ablation in patients with obstructive hypertrophic cardiomyopathy. *Interv J Cardiovasc Interv* 2005;7:134-7.
38. Flores-Ramirez R, Lakkis NM, Middleton KJ, Killip D, Spencer WH III, Nagueh SF. Echocardiographic insights into the mechanisms of relief of left ventricular outflow tract obstruction after nonsurgical septal reduction therapy in patients with hypertrophic obstructive cardiomyopathy. *J Am Coll Cardiol* 2001;37:208-14.
39. Nagueh SF, Mahmarian JJ. Noninvasive cardiac imaging in patients with hypertrophic cardiomyopathy. *J Am Coll Cardiol* 2006;48:2410-22.
40. Maron BJ, Seidman JC, Seidman CE. Proposal for contemporary screening strategies in families with hypertrophic cardiomyopathy. *J Am Coll Cardiol* 2004;44:2125-32.
41. Nagueh SF, Kopelen HA, Lim DS, Zoghbi WA, Quiñones MA, Roberts R, et al. Tissue Doppler imaging consistently detects myocardial contraction and relaxation abnormalities, irrespective of cardiac hypertrophy, in a transgenic rabbit model of human hypertrophic cardiomyopathy. *Circulation* 2000;102:1346-50.
42. Ho CY, Sweitzer NK, McDonough B, Maron BJ, Casey SA, Seidman JC, et al. Assessment of diastolic function with Doppler tissue imaging to predict genotype in preclinical hypertrophic cardiomyopathy. *Circulation* 2002;105:2992-7.
43. Michels M, Soliman OI, Kofflard MJ, Hoedemaekers YM, Dooijes D, Maajoer-Krakauer D, et al. Diastolic abnormalities as the first feature of hypertrophic cardiomyopathy in Dutch myosin-binding protein C founder mutations. *J Am Coll Cardiol* 2009;2:58-64.
44. Bonow RO, Ostrow HG, Rosing DR, Cannon RO, Lipson LC, Maron BJ, et al. Effects of verapamil on left ventricular systolic and diastolic function in patients with hypertrophic cardiomyopathy: pressure-volume analysis with a nonimaging scintillation probe. *Circulation* 1983;68:1062-73.
45. Bonow RO, Dilsizian V, Rosing DR, Maron BJ, Bacharach SL, Green MV. Verapamil-induced improvement in left ventricular diastolic filling and increased exercise tolerance in patients with hypertrophic cardiomyopathy: short- and long-term effects. *Circulation* 1985;72:853-64.
46. Nishimura RA, Schwartz RS, Holmes DR Jr., Tajik AJ. Failure of calcium channel blockers to improve ventricular relaxation in humans. *J Am Coll Cardiol* 1993;21:182-8.
47. O'Gara PT, Bonow RO, Maron BJ, Damske BA, Van Lingen A, Bacharach SL, et al. Myocardial perfusion abnormalities in patients with hypertrophic cardiomyopathy: assessment with thallium-201 emission computed tomography. *Circulation* 1987;76:1214-23.
48. Udelson JE, Bonow RO, O'Gara PT, Maron BJ, Van Lingen A, Bacharach SL, et al. Verapamil prevents silent myocardial perfusion abnormalities during exercise in asymptomatic patients with hypertrophic cardiomyopathy. *Circulation* 1989;79:1052-60.
49. Dilsizian V, Bonow RO, Epstein SE, Fananapazir L. Myocardial ischemia detected by thallium scintigraphy is frequently related to cardiac arrest and syncope in young patients with hypertrophic cardiomyopathy. *J Am Coll Cardiol* 1993;22:796-804.
50. Cecchi F, Olivetto I, Gistri R, Lorenzoni R, Chiriatti G, Camici PG. Coronary microvascular dysfunction and prognosis in hypertrophic cardiomyopathy. *N Engl J Med* 2003;349:1027-35.
51. Cannon RO, Dilsizian V, O'Gara PT, Udelson JE, Schenke WH, Quyyumi A, et al. Myocardial metabolic, hemodynamic and electrocardiographic significance of reversible thallium-201 abnormalities in hypertrophic cardiomyopathy. *Circulation* 1991;83:1660-7.
52. Cannon RO, Dilsizian V, O'Gara PT, Udelson JE, Tucker E, Panza JA, et al. Impact of operative relief of outflow obstruction on thallium perfusion abnormalities in hypertrophic cardiomyopathy. *Circulation* 1992;85:1039-45.
53. Maron BJ, Wolfson JK, Epstein SE, Roberts WC. Intramural ("small vessel") coronary artery disease in hypertrophic cardiomyopathy. *J Am Coll Cardiol* 1986;8:545-57.
54. Cannon RO III, Rosing DR, Maron BJ, Leon MB, Bonow RO, Watson RM, et al. Myocardial ischemia in patients with hypertrophic cardiomyopathy: contribution of inadequate vasodilator reserve and elevated left ventricular filling pressures. *Circulation* 1985;71:234-43.
55. Camici P, Chiriatti G, Lorenzoni R, Bellina RC, Gistri R, Italiani G, et al. Coronary vasodilation is impaired in both hypertrophied and nonhypertrophied myocardium of patients with hypertrophic cardiomyopathy: a study with nitrogen-13 ammonia and positron emission tomography. *J Am Coll Cardiol* 1991;17:879-86.
56. Yamada M, Elliott PM, Kaski JC, Prasad K, Gane JN, Lowe CM, et al. Dipyridamole stress thallium-201 perfusion abnormalities in patients with hypertrophic cardiomyopathy. Relationship to clinical presentation and outcome. *Eur Heart J* 1998;19:500-7.
57. Zhao C, Shuke N, Okizaki A, Yamamoto W, Sato J, Ishikawa Y, et al. Comparison of myocardial fatty acid metabolism with left ventricular function and perfusion in cardiomyopathies by 123I-BMIPP SPECT and 99mTc-tetrafosmin electrocardiographically gated SPECT. *Ann Nucl Med* 2003;17:541-8.
58. Terai H, Shimizu M, Ino H, Yamaguchi M, Uchiyama K, Oe K, et al. Changes in cardiac sympathetic nerve innervations and activity in pathophysiological transition from typical to end-stage hypertrophic cardiomyopathy. *J Nucl Med* 2003;44:1612-7.

59. Schafers M, Durka D, Rhodes CG, Lammertsma AA, Hermansen F, Schober O, et al. Myocardial presynaptic and postsynaptic autonomic dysfunction in hypertrophic cardiomyopathy. *Circ Res* 1998;82:57-62.
60. Sipola P, Vanninen E, Aronen HJ, Lauerma K, Simula S, Jääskeläinen P, et al. Cardiac adrenergic activity is associated with left ventricular hypertrophy in genetically homogeneous subjects with hypertrophic cardiomyopathy. *J Nucl Med* 2003;44:487-93.
61. Choudhury L, Guzzetti S, Lefroy DC, Nihoyannopoulos P, McKenna WJ, Oakley CM, et al. Myocardial beta adrenoceptors and left ventricular function in hypertrophic cardiomyopathy. *Heart* 1996;75:50-4.
62. Keng FYJ, Chang SM, Cwajg E, He ZX, Lakkis NM, Nagueh SF, et al. Gated SPECT in patients with hypertrophic obstructive cardiomyopathy undergoing transcatheter ethanol septal ablation. *J Nucl Cardiol* 2002; 9:594-600.
63. Aqel RA, Hage FG, Zohghi GJ, Tabereaux PB, Lawson D, Heo J, et al. Serial evaluations of myocardial infarct size after alcohol septal ablation in hypertrophic cardiomyopathy and effects of the changes on clinical status and left ventricular outflow pressure gradients. *Am J Cardiol* 2008;101:1328-33.
64. Lima JA, Desai MY. Cardiovascular magnetic resonance imaging: current and emerging applications. *J Am Coll Cardiol* 2004;44:1164-71.
65. Hendel RC, Patel MR, Kramer CM, Poon M, Hendel RC, Carr JC, et al. ACCF/ACR/SCCT/SCMR/ASNC/NASCI/SCAI/SIR 2006 appropriateness criteria for cardiac computed tomography and cardiac magnetic resonance imaging: a report of the American College of Cardiology Foundation Quality Strategic Directions Committee Appropriateness Criteria Working Group, American College of Radiology, Society of Cardiovascular Computed Tomography, Society for Cardiovascular Magnetic Resonance, American Society of Nuclear Cardiology, North American Society for Cardiac Imaging, Society for Cardiovascular Angiography and Interventions, and Society of Interventional Radiology. *J Am Coll Cardiol* 2006;48:1475-97.
66. Kramer CM, Barkhausen J, Flamm SD, Kim RJ, Nagel E. Standardized cardiovascular magnetic resonance imaging (CMR) protocols, society for cardiovascular magnetic resonance: Board of Trustees Task Force on Standardized Protocols. *J Cardiovasc Magn Reson* 2008;10:35.
67. Maron MS, Maron BJ, Harrigan C, Buros J, Gibson CM, Olivetto I, et al. Hypertrophic cardiomyopathy phenotype revisited after 50 years with cardiovascular magnetic resonance. *J Am Coll Cardiol* 2009;54: 220-8.
68. Moon JC, Fisher NG, McKenna WJ, Pennell DJ. Detection of apical hypertrophic cardiomyopathy by cardiovascular magnetic resonance in patients with non-diagnostic echocardiography. *Heart* 2004;90:645-9.
69. Rickers C, Wilke NM, Jerosch-Herold M, Casey SA, Panse P, Panse N, et al. Utility of cardiac magnetic resonance imaging in the diagnosis of hypertrophic cardiomyopathy. *Circulation* 2005;112:855-61.
70. Petersen SE, Jerosch-Herold M, Hudsmith LE, Robson MD, Francis JM, Doll HA, et al. Evidence for microvascular dysfunction in hypertrophic cardiomyopathy: new insights from multiparametric magnetic resonance imaging. *Circulation* 2007;115:2418-25.
71. Adabag AS, Maron BJ, Appelbaum E, Harrigan CJ, Buros JL, Gibson CM, et al. Occurrence and frequency of arrhythmias in hypertrophic cardiomyopathy in relation to delayed enhancement on cardiovascular magnetic resonance. *J Am Coll Cardiol* 2008;51:1369-74.
72. Choudhury L, Mahrholdt H, Wagner A, Choi KM, Elliott MD, Klocke FJ, et al. Myocardial scarring in asymptomatic or mildly symptomatic patients with hypertrophic cardiomyopathy. *J Am Coll Cardiol* 2002;40: 2156-64.
73. Kwon DH, Setser RM, Popovic ZB, Thamilarsan M, Sola S, Schoenhagen P, et al. Association of myocardial fibrosis, electrocardiography and ventricular tachyarrhythmia in hypertrophic cardiomyopathy: a delayed contrast enhanced MRI study. *Int J Cardiovasc Imaging* 2008; 24:617-25.
74. Moon JC, McKenna WJ, McCrohon JA, Elliott PM, Smith GC, Pennell DJ. Toward clinical risk assessment in hypertrophic cardiomyopathy with gadolinium cardiovascular magnetic resonance. *J Am Coll Cardiol* 2003; 41:1561-7.
75. Maron MS, Finley JJ, Bos JM, Hauser TH, Manning WJ, Haas TS, et al. Prevalence, clinical significance, and natural history of left ventricular apical aneurysms in hypertrophic cardiomyopathy. *Circulation* 2008;118: 1541-9.
76. Maron MS, Hauser TH, Dubrow E, Horst TA, Kissinger KV, Udelson JE, et al. Right ventricular involvement in hypertrophic cardiomyopathy. *Am J Cardiol* 2007;100:1293-8.
77. Harrigan CJ, Appelbaum E, Maron BJ, Buros JL, Gibson CM, Lesser JR, et al. Significance of papillary muscle abnormalities identified by cardiovascular magnetic resonance in hypertrophic cardiomyopathy. *Am J Cardiol* 2008;101:668-73.
78. Kwon DH, Setser RM, Thamilarsan M, Popovic ZV, Smedira NG, Schoenhagen P, et al. Abnormal papillary muscle morphology is independently associated with increased left ventricular outflow tract obstruction in hypertrophic cardiomyopathy. *Heart* 2008;94:1295-301.
79. Ennis DB, Epstein FH, Kellman P, Fananapazir L, McVeigh ER, Arai AE. Assessment of regional systolic and diastolic dysfunction in familial hypertrophic cardiomyopathy using MR tagging. *Magn Reson Med* 2003;50:638-42.
80. Kim YJ, Choi BW, Hur J, Lee HJ, Seo JS, Kim TH, et al. Delayed enhancement in hypertrophic cardiomyopathy: comparison with myocardial tagging MRI. *J Magn Reson Imaging* 2008;27:1054-60.
81. Kwon DH, Smedira NG, Popovic ZB, Lytle BW, Setser R, Thamilarsan M, et al. Steep left ventricle to aortic root angle and hypertrophic obstructive cardiomyopathy: Study of a novel association using 3-dimensional multi-modality imaging. *Heart* 2009;95:1784-91.
82. Boonyasirinant T, Rajiah P, Setser RM, Lieber ML, Lever HM, Desai MY, et al. Aortic stiffness is increased in hypertrophic cardiomyopathy with myocardial fibrosis: novel insights in vascular function from magnetic resonance imaging. *J Am Coll Cardiol* 2009;54:255-62.
83. Austin BA, Popovic Z, Kwon D, Thamilarsan M, Boonyasirinant T, Flamm SD, et al. Aortic stiffness independently predicts exercise capacity in hypertrophic cardiomyopathy: a multimodality imaging study. *Heart* 2010;96:1303-10.
84. Schulz-Menger J, Abdel-Aty H, Busjahn A, Wassmuth R, Pilz B, Dietz R, et al. Left ventricular outflow tract planimetry by cardiovascular magnetic resonance differentiates obstructive from non-obstructive hypertrophic cardiomyopathy. *J Cardiovasc Magn Reson* 2006;8:741-6.
85. O'Brien KR, Cowan BR, Jain M, Stewart RA, Kerr AJ, Young AA. MRI phase contrast velocity and flow errors in turbulent stenotic jets. *J Magn Reson Imaging* 2008;28:210-8.
86. Maron MS, Harrigan C, Buros J, Gibson CM, Hanna C, Lesser JR, et al. Clinical profile and significance of delayed enhancement in hypertrophic cardiomyopathy. *Circulation: Heart Failure* 2008;1:184-91.
87. Moon JC, Reed E, Sheppard MN, Elkington AG, Ho SY, Burke M, et al. The histologic basis of late gadolinium enhancement cardiovascular magnetic resonance in hypertrophic cardiomyopathy. *J Am Coll Cardiol* 2004;43:2260-4.
88. Rubinshtein R, Glockner JF, Ommen SR, Araoz PA, Ackerman MJ, Sorajja P, et al. Characteristics and clinical significance of late gadolinium enhancement by contrast-enhanced magnetic resonance imaging in patients with hypertrophic cardiomyopathy. *Circ Heart Fail* 2009;3: 51-8.
89. Jung WJ, Sieverding L, Breuer J, Hoess T, Widmaier S, Schmidt O, et al. 31P NMR spectroscopy detects metabolic abnormalities in asymptomatic patients with hypertrophic cardiomyopathy. *Circulation* 1998;97: 2536-42.
90. Crilley JG, Boehm EA, Blair E, Rajagopalan B, Blamire AM, Styles P, et al. Hypertrophic cardiomyopathy due to sarcomeric gene mutations is characterized by impaired energy metabolism irrespective of the degree of hypertrophy. *J Am Coll Cardiol* 2003;41:1776-82.
91. Valeti US, Nishimura RA, Holmes DR, Araoz PA, Glockner JF, Breen JF, et al. Comparison of surgical septal myectomy and alcohol septal ablation with cardiac magnetic resonance imaging in patients with hypertrophic obstructive cardiomyopathy. *J Am Coll Cardiol* 2007;49:350-7.
92. van Dockum WG, Beek AM, ten Cate FJ, ten Berg JM, Bondarenko O, Gotte MJ, et al. Early onset and progression of left ventricular remodeling

- after alcohol septal ablation in hypertrophic obstructive cardiomyopathy. *Circulation* 2005;111:2503-8.
93. Germans T, Wilde AA, Dijkmans PA, Chai W, Kamp O, Pinto YM, et al. Structural abnormalities of the inferoseptal left ventricular wall detected by cardiac magnetic resonance imaging in carriers of hypertrophic cardiomyopathy mutations. *J Am Coll Cardiol* 2006;48:2518-23.
 94. Mark DB, Berman DS, Budoff MJ, Carr JJ, Gerber TC, Hecht HS, et al. ACCF/ACR/AHA/NASCI/SAIP/SCAI/SCCT 2010 expert consensus document on coronary computed tomographic angiography: a report of the American College of Cardiology Foundation Task Force on Expert Consensus Documents. *J Am Coll Cardiol* 2010;55:2663-99.
 95. Orakzai SH, Orakzai RH, Nasir K, Budoff MJ. Assessment of cardiac function using multidetector row computed tomography. *J Comput Assist Tomogr* 2006;30:555-63.
 96. Dewey M, Müller M, Eddicks S, Schnapauß D, Teige F, Rutsch W, et al. Evaluation of global and regional left ventricular function with 16-slice computed tomography, biplane cine ventriculography, and two-dimensional transthoracic echocardiography: comparison with magnetic resonance imaging. *J Am Coll Cardiol* 2006;48:2034-44.
 97. Mahnken AH, Koos R, Katoh M, Wildberger JE, Spuentrup E, Buecker A, et al. Assessment of myocardial viability in reperfused acute myocardial infarction using 16-slice computed tomography in comparison to magnetic resonance imaging. *J Am Coll Cardiol* 2005;45:2042-7.
 98. Mangalat D, Kalogeropoulos A, Georgiopolou V, Stillman A, Butler J. Value of cardiac CT in patients with heart failure. *Curr Cardiovasc Imaging Rep* 2009;2:410-7.
 99. Mao SS, Budoff MJ, Oudiz RJ, Bakhsheshi H, Wang SJ, Brundage BH. Effect of exercise on left and right ventricular ejection fraction and wall motion in patients with coronary artery disease: an electron beam computed tomography study. *Int J Cardiol* 1999;71:23-31.
 100. Gopal A, Mao SS, Karlsberg D, Young E, Waggoner J, Ahmadi N, et al. Radiation reduction with prospective ECG-triggering acquisition using 64-multidetector computed tomographic angiography. *Int J Cardiovasc Imaging* 2009;25:405-16.
 101. Alkadhi H, Desbiolles L, Stolzmann P, Leschka S, Scheffel H, Plass A, et al. Mitral annular shape, size, and motion in normals and in patients with cardiomyopathy: evaluation with computed tomography. *Invest Radiol* 2009;44:218-25.
 102. Okayama S, Uemura S, Soeda T, Horii M, Saito Y. Role of cardiac computed tomography in planning and evaluating percutaneous transluminal septal myocardial ablation for hypertrophic obstructive cardiomyopathy. *J Cardiovasc Comput Tomogr* 2010;4:62-5.
 103. Suda K, Kohl T, Kovalchin JP, Silverman NH. Echocardiographic predictors of poor outcome in infants with hypertrophic cardiomyopathy. *Am J Cardiol* 1997;80:595-600.
 104. Maron BJ. Hypertrophic cardiomyopathy in childhood. *Pediatr Clin North Am* 2004;51:1305-46.
 105. Binder J, Ommen SR, Gersh BJ, Van Driest SL, Tajik AJ, Nishimura RA, et al. Echocardiography-guided genetic testing in hypertrophic cardiomyopathy: septal morphological features predict the presence of myofibrillar mutations. *Mayo Clin Proc* 2006;81:459-67.
 106. Menon SC, Ackerman MJ, Cetta F, O'Leary PW, Eidem BW. Significance of left atrial volume in patients < 20 years of age with hypertrophic cardiomyopathy. *Am J Cardiol* 2008;102:1390-3.
 107. Menon SC, Ackerman MJ, Ommen SR, Cabalka AK, Hagler DJ, O'Leary PW, et al. Impact of septal myectomy on left atrial volume and left ventricular diastolic filling patterns: an echocardiographic study of young patients with obstructive hypertrophic cardiomyopathy. *J Am Soc Echocardiogr* 2008;21:684-8.
 108. Menon SC, Eidem BW, Dearani JA, Ommen SR, Ackerman MJ, Miller D. Diastolic dysfunction and its histopathological correlation in obstructive hypertrophic cardiomyopathy in children and adolescents. *J Am Soc Echocardiogr* 2009;22:1327-34.
 109. Weidemann F, Eyskens B, Jamal F, Mertens L, Kowalski M, D'Hooge J, et al. Quantification of regional right and left ventricular radial and longitudinal function in healthy children using ultrasound-based strain rate and strain imaging. *J Am Soc Echocardiogr* 2002;15:20-8.
 110. Lorch SM, Ludomirsky A, Singh GK. Maturational and growth-related changes in left ventricular longitudinal strain and strain rate measured by two-dimensional speckle tracking echocardiography in healthy pediatric population. *J Am Soc Echocardiogr* 2008;21:1207-15.
 111. Ganame J, Mertens L, Eidem BW, Claus P, D'Hooge J, Havemann LM, et al. Regional myocardial deformation in children with hypertrophic cardiomyopathy: morphological and clinical correlations. *Eur Heart J* 2007;28:2886-94.
 112. Ganame J, Pignatelli RH, Eidem BW, Claus P, D'Hooge J, McMahon CJ, et al. Myocardial deformation abnormalities in paediatric hypertrophic cardiomyopathy: are all aetiologies identical? *Eur J Echocardiogr* 2008;9:784-90.
 113. Moon JC, Sachdev B, Elkington AG, McKenna WJ, Mehta A, Pennell DJ, et al. Gadolinium enhanced cardiovascular magnetic resonance in Anderson-Fabry disease. Evidence for a disease specific abnormality of the myocardial interstitium. *Eur Heart J* 2003;24:2151-5.
 114. Kelley-Hedgpeh A, Towbin JA, Maron MS. Overlapping phenotypes: left ventricular noncompaction and hypertrophic cardiomyopathy. *Circulation* 2009;119:e588-9.
 115. Maron BJ. Distinguishing hypertrophic cardiomyopathy from athlete's heart: a clinical problem of increasing magnitude and significance. *Heart* 2005;91:1380-2.
 116. Maron BJ, Chaitman BR, Ackerman MJ, Bayés de Luna A, Corrado D, Crosson JE, et al. Recommendations for physical activity and recreational sports participation for young patients with genetic cardiovascular diseases. *Circulation* 2004;109:2807-16.
 117. Basavarajaiah S, Boraita A, Whyte G, Wilson M, Carby L, Shah A, et al. Ethnic differences in left ventricular remodeling in highly-trained athletes: relevance to differentiating physiological left ventricular hypertrophy from hypertrophic cardiomyopathy. *J Am Coll Cardiol* 2008;51:2256-62.
 118. Basavarajaiah S, Wilson M, Whyte G, Shah A, McKenna W, Sharma S. Prevalence of hypertrophic cardiomyopathy in highly trained athletes: relevance to pre-participation screening. *J Am Coll Cardiol* 2008;51:1033-9.
 119. Whyte GP, George K, Sharma S, Firoozi S, Stephens N, Senior R, et al. The upper limit of physiological cardiac hypertrophy in elite male and female athletes: the British experience. *Eur J Appl Physiol* 2004;92:592-7.
 120. Galanti G, Toncelli L, Del Furia F, Stefani L, Cappelli B, De Luca A, et al. Tissue doppler imaging can be useful to distinguish pathological from physiological left ventricular hypertrophy: a study in master athletes and mild hypertensive subjects. *Cardiovasc Ultrasound* 2009;7:48.
 121. Indermuhle A, Vogel R, Meier P, Wirth S, Stoop R, Mohaupt MG, et al. The relative myocardial blood volume differentiates between hypertensive heart disease and athlete's heart in humans. *Eur Heart J* 2006;27:1571-8.
 122. Maron MS, Olivetto I, Zenovich AG, Link MS, Pandian NG, Kuvin JT, et al. Hypertrophic cardiomyopathy is predominantly a disease of left ventricular outflow tract obstruction. *Circulation* 2006;114:2232-9.
 123. Lakkis N, Plana JC, Nagueh S, Killip D, Roberts R, Spencer WH III. Efficacy of nonsurgical septal reduction therapy in symptomatic patients with obstructive hypertrophic cardiomyopathy and provokable gradients. *Am J Cardiol* 2001;88:583-6.
 124. Kwon DH, Smedira NG, Thamilarasan M, Lytle BW, Lever H, Desai MY. Characteristics and surgical outcomes of symptomatic patients with hypertrophic cardiomyopathy with abnormal papillary muscle morphology undergoing papillary muscle reorientation. *J Thorac Cardiovasc Surg* 2010;140:317-24.
 125. Maron MS, Olivetto I, Betocchi S, Casey SA, Lesser JR, Losi MA, et al. Effect of left ventricular outflow tract obstruction on clinical outcome in hypertrophic cardiomyopathy. *N Engl J Med* 2003;348:295-303.
 126. O'Hanlon R, Grasso A, Roughton M, Moon JC, Clark S, Wage R, et al. Prognostic significance of myocardial fibrosis in hypertrophic cardiomyopathy using CMR. *J Am Coll Cardiol* 2010;56:867-74.
 127. Bruder O, Wagner A, Jensen CJ, Schneider S, Ong P, Kispert EM, et al. Myocardial scar visualized by cardiovascular magnetic resonance imaging predicts major adverse events in patients with hypertrophic cardiomyopathy. *J Am Coll Cardiol* 2010;56:875-87.