

Puzzling cases to learn from: Read with the experts

Dermot Phelan MD PhD FASE FESC FACC

Medical Director of Cardiovascular Imaging,

Director of Sports Cardiology Center,

Co-Director of HCM Center

Sanger Heart and Vascular Institute

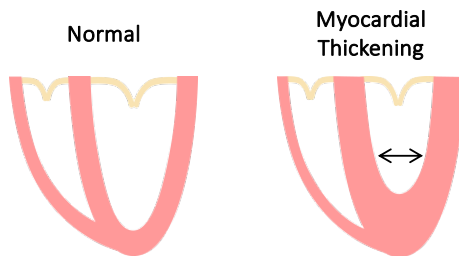
Atrium Health

No Disclosures



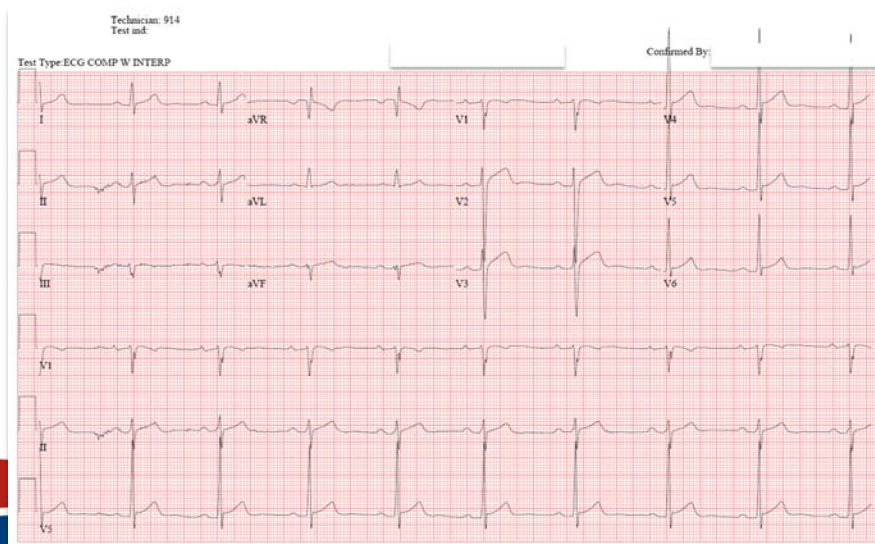
1

HCM or Athletes Heart?

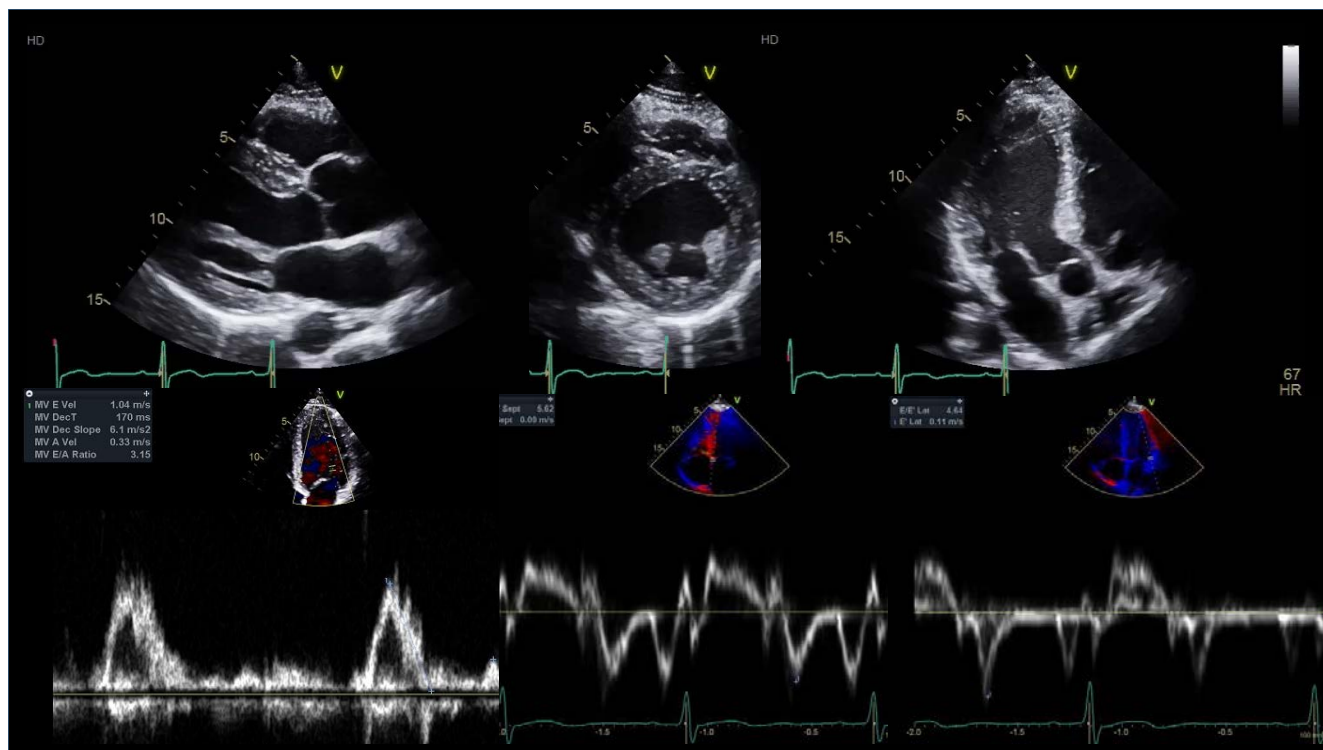


2

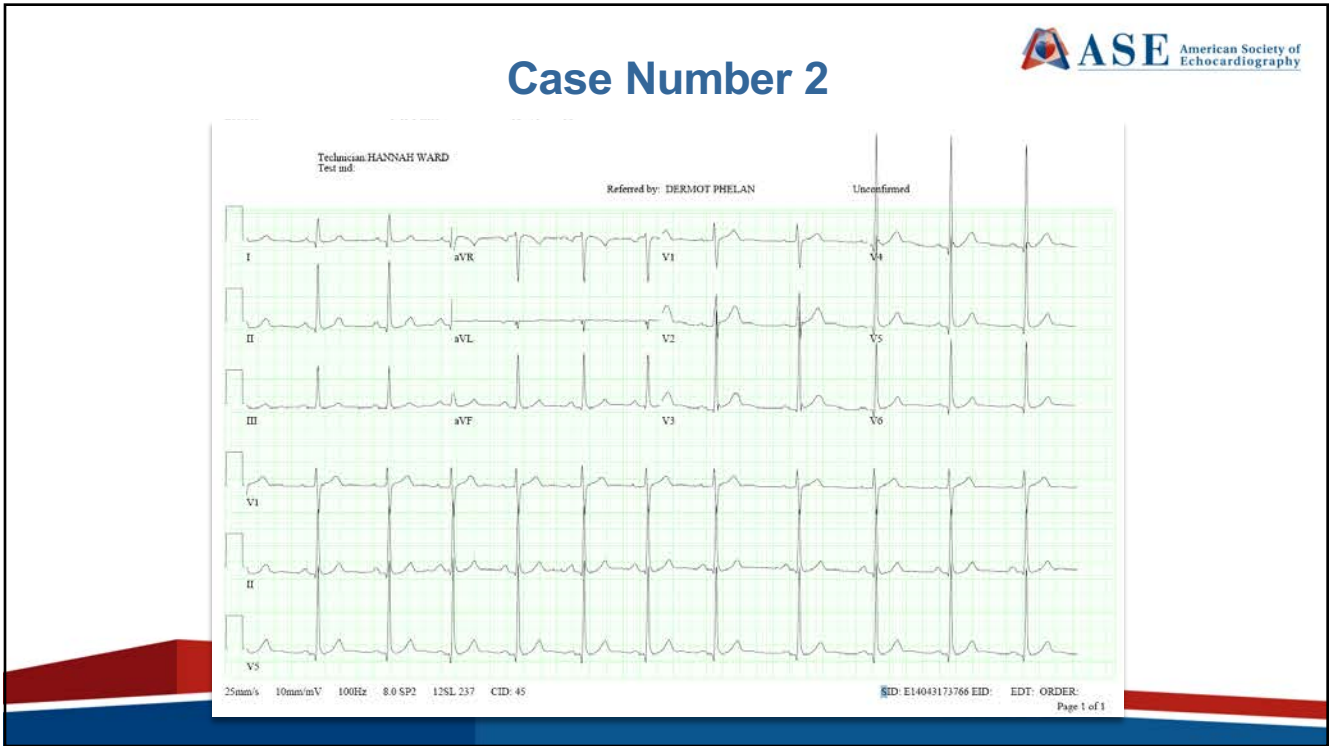
Case Number 1



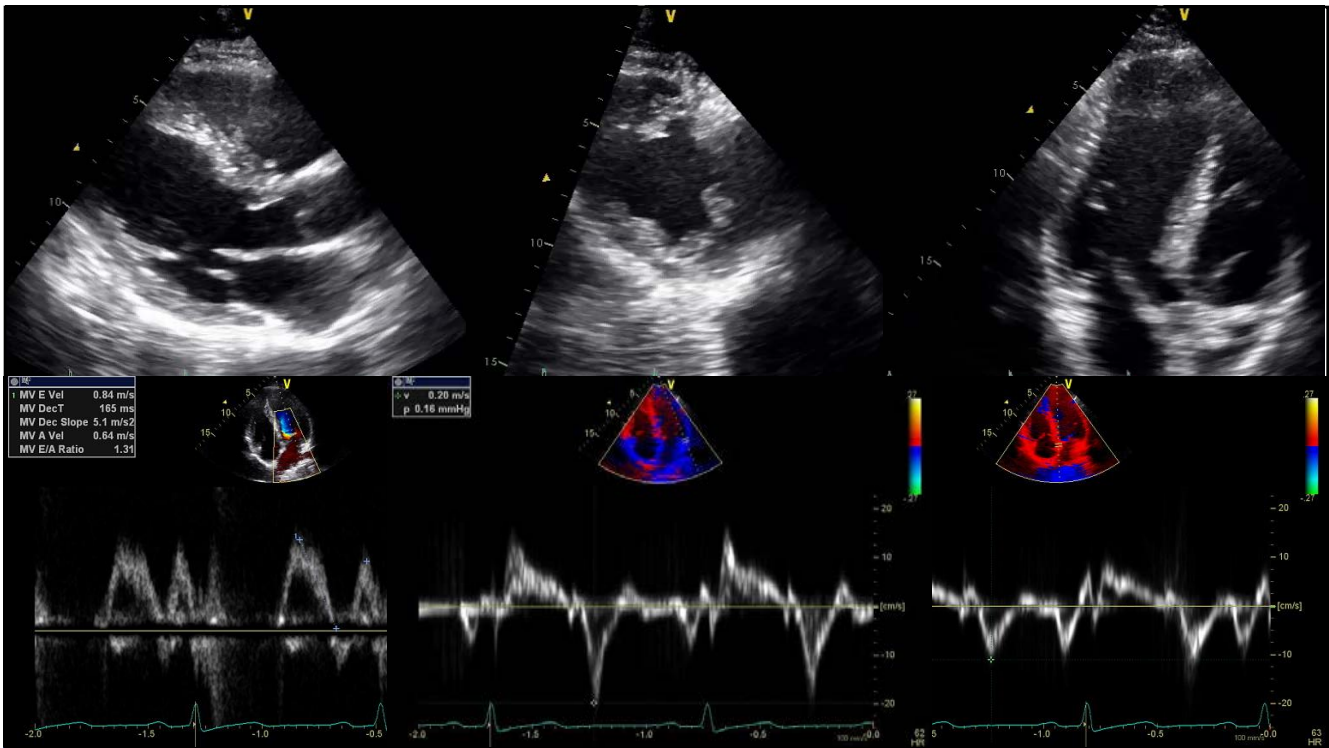
3



4

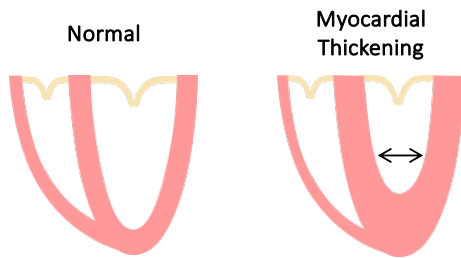


5



6

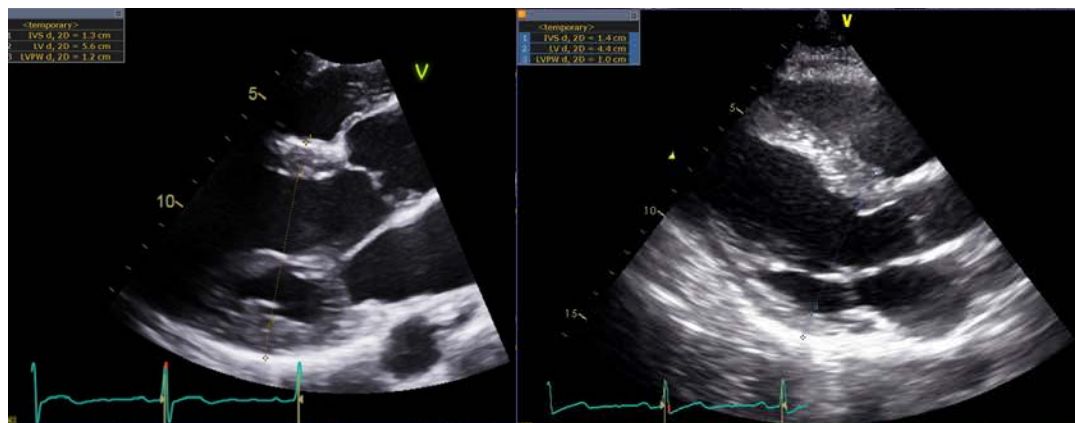
HCM or Athletes Heart?



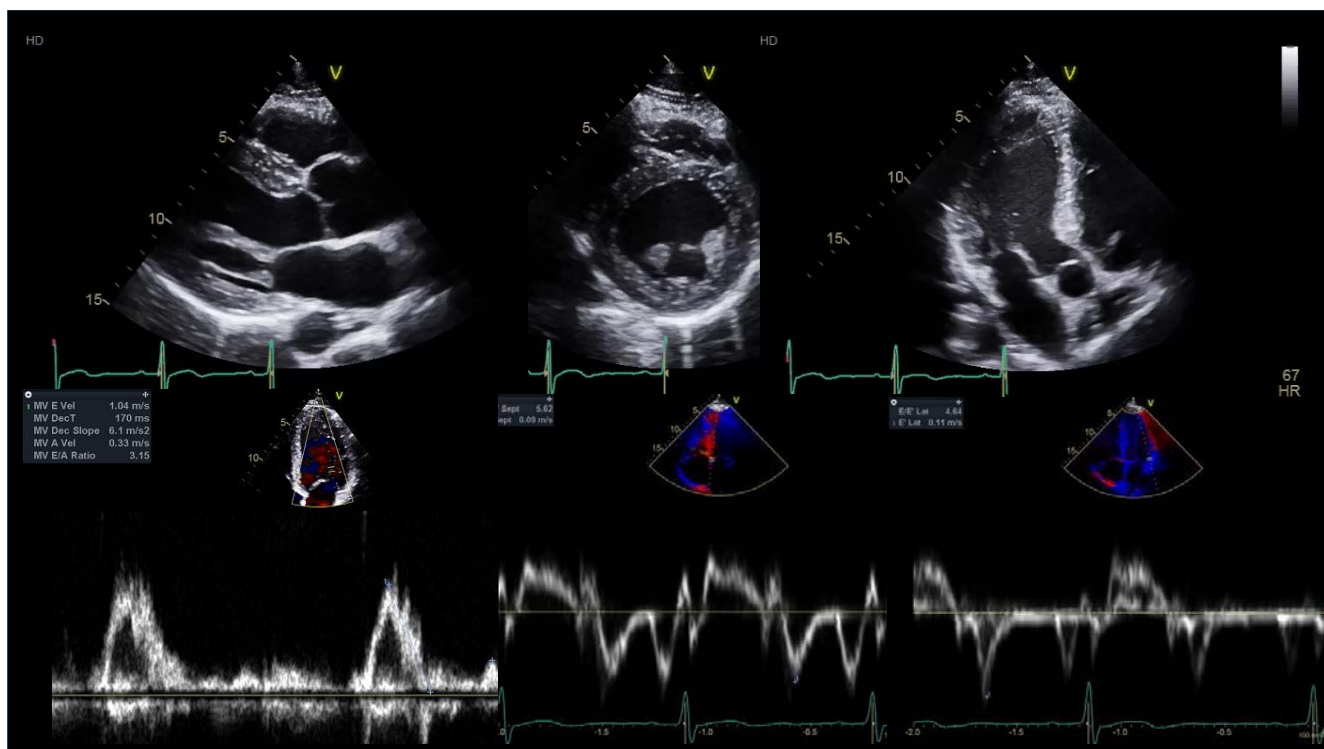
7

Case Number 1

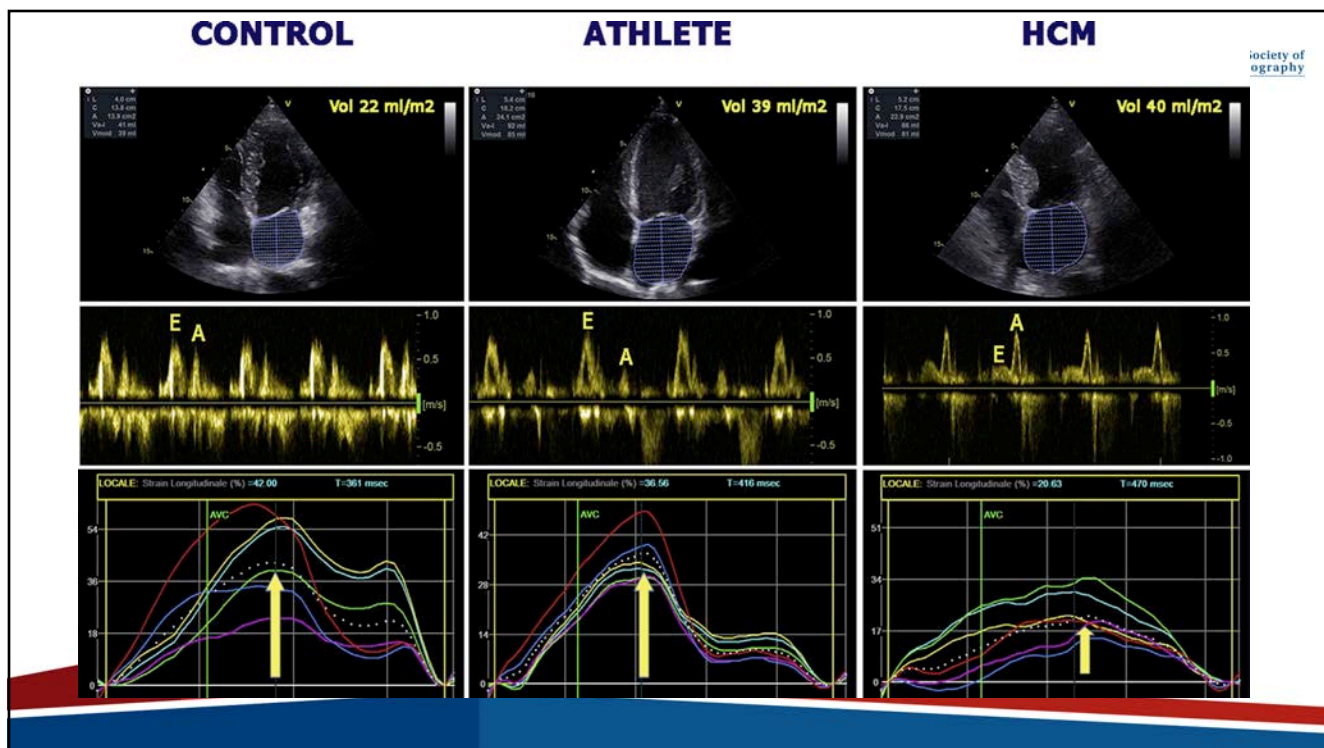
Case Number 2



8



9

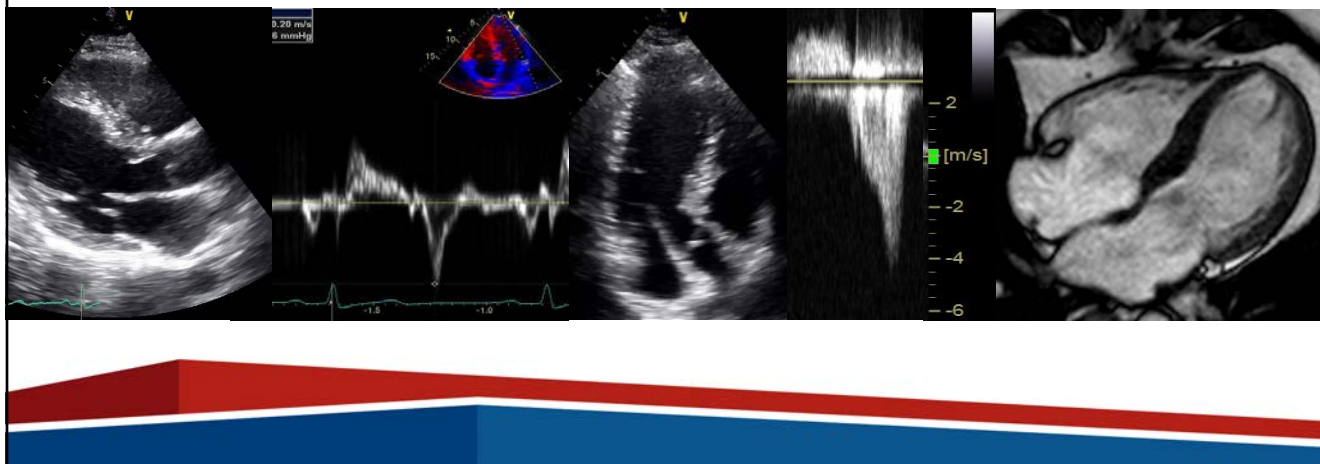


10

Case 2

Assess the Mitral Valve

21 year old collegiate soccer player presents with exertional syncope




11

Thank you for your attention

@DermotPhelanMD

dermot.phelan@atriumhealth.org



12