

# Recommendations for Evaluation of the Severity of Native Valvular Regurgitation with Two-dimensional and Doppler Echocardiography

A report from the American Society of Echocardiography's Nomenclature and Standards Committee and The Task Force on Valvular Regurgitation, developed in conjunction with the American College of Cardiology Echocardiography Committee, The Cardiac Imaging Committee Council on Clinical Cardiology, the American Heart Association, and the European Society of Cardiology Working Group on Echocardiography, represented by:

William A. Zoghbi, MD, Maurice Enriquez-Sarano, MD, Elyse Foster, MD, Paul A. Grayburn, MD, Carol D. Kraft, RDMS, Robert A. Levine, MD, Petros Nihoyannopoulos, MD, Catherine M. Otto, MD, Miguel A. Quinones, MD, Harry Rakowski, MD, William J. Stewart, MD, Alan Waggoner, MHS, RDMS, and Neil J. Weissman, MD

## **A. INTRODUCTION**

Valvular regurgitation has long been recognized as an important cause of morbidity and mortality. Although the physical examination can alert the clinician to the presence of significant regurgitation, diagnostic methods are often needed to assess the severity of valvular regurgitation and remodeling of the cardiac chambers in response to the volume overload state. Echocardiography with Doppler has recently emerged as the method of choice for the non-invasive detection and evaluation of the severity and etiology of valvular regurgitation. This document offers a critical review of echocardiographic and Doppler techniques used in the evaluation of valvular regurgitation in the adult patient, and provides recommendations for the assessment of severity of valvular regurgitation based on the scientific

These recommendations are endorsed by the American College of Cardiology (ACC), the American Heart Association (AHA), and the European Society of Cardiology (ESC). Representative from the ACC Echocardiography Committee: Elyse Foster, MD; representative from the Cardiac Imaging Committee, Council on Clinical Cardiology, AHA: Miguel A. Quinones, MD; representative from the ESC Working Group on Echocardiography: Petros Nihoyannopoulos, MD.

Copyright 2003 American Society of Echocardiography, Property of ASE. Reprint of these documents, beyond single use, is prohibited without the prior written authorization of the ASE. Illustrative cases of valvular regurgitation are available on the Web site of the American Society of Echocardiography at [www.aseuniversity.org/valveregurgitation.html](http://www.aseuniversity.org/valveregurgitation.html). Address document reprint requests to the American Society of Echocardiography, 1500 Sunday Drive, Suite 102, Raleigh, NC 27607, phone: (919) 787-5181.

J Am Soc Echocardiogr 2003;16:777-802.

Copyright 2003 by the American Society of Echocardiography.

0894-7317/2003/\$30.00 + 0

doi:10.1016/S0894-7317(03)00335-3

literature and a consensus of a panel of experts. Issues of medical management and timing of surgical intervention will not be addressed in this document, as these have been recently published.<sup>1</sup>

## **B. TWO-DIMENSIONAL AND DOPPLER ECHOCARDIOGRAPHY IN VALVULAR REGURGITATION: GENERAL CONSIDERATIONS**

Valvular regurgitation or incompetence results from various etiologies including valvular degeneration, calcification, fibrosis or infection, alteration of the valvular support apparatus or dilatation of the valve annulus. These conditions cause poor apposition of the valvular leaflets or cusps, and may lead to prolapse, flail, restricted leaflet motion or valvular perforation. With the advent of Doppler techniques that are sensitive to detection of regurgitation, trivial and physiologic valvular regurgitation— even in a structurally normal valve, is now well recognized and is noted to occur frequently in right-sided valves. The following sections describe general considerations of the role of echocardiographic and Doppler techniques in the evaluation of regurgitant lesions.

### **1. Role of Two-dimensional Echocardiography**

Two-dimensional (2D) echocardiography allows an evaluation of the valvular structure as well as the impact of the volume overload on the cardiac chambers. Calcifications, tethering, flail motion or vegetations can be readily assessed, which can give indirect clues as to the severity of regurgitation. While prolapse, vegetations or calcifications are not necessarily associated with significant regurgitation, a flail leaflet almost always is. In the cases of

non-diagnostic transthoracic studies, transesophageal echocardiography (TEE) improves the visualization of the valvular structure and delineates the mechanism and severity of regurgitation.

The duration (acute or chronic) and severity of valvular regurgitation are among the most important determinants of the adaptive changes that occur in the cardiac chambers in response to the regurgitant volume. Thus, a chronic significant regurgitation is usually accompanied by an increase in size and hypertrophy of the involved cardiac chambers whereas significant regurgitation of acute onset from a condition such as endocarditis may not result acutely in this remodeling. While cardiac chamber remodeling is not specific for the degree of regurgitation (ie. occurs in coronary artery disease, congestive cardiomyopathy etc.), its absence in the face of chronic regurgitation should imply a milder degree of valvular insufficiency.

Once a diagnosis of significant regurgitation is established, serial 2D echocardiography is currently the method of choice for assessing the progression of the mechanical impact of regurgitation on cardiac chamber structure and function. Recommendations for determination of ventricular volumes and ejection fraction have been previously published.<sup>2</sup> These, along with clinical evaluation are needed for adequate timing of surgical intervention.

## 2. Doppler Methods for Evaluation of Valvular Regurgitation

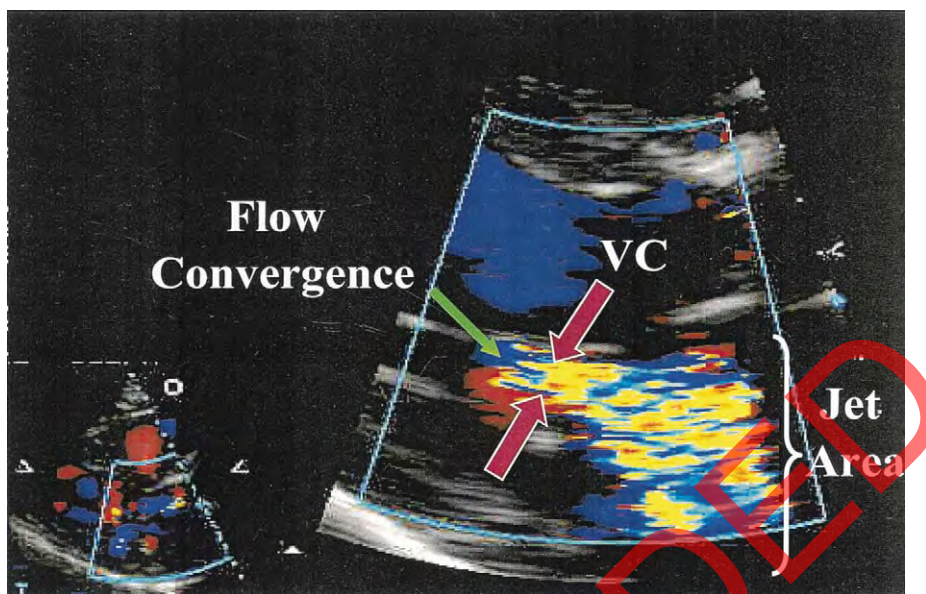
Doppler echocardiography is the most common technique used for the detection and evaluation of severity of valvular regurgitation. Several indexes have been developed to assess the severity of regurgitation using Color Doppler, Pulsed wave (PW) and Continuous wave (CW) Doppler. Details of the Doppler techniques and the methods involved in obtaining these parameters are described in a recently published document from the American Society of Echocardiography on quantification of Doppler Echocardiography.<sup>3</sup> The following summarizes the salient features of these techniques for the purposes of evaluation and quantitation of valvular regurgitation.

**a. Color Doppler.** Color flow Doppler is widely used for the detection of regurgitant valve lesions. This technique provides visualization of the origin of the regurgitation jet and its width (vena contracta), the spatial orientation of the regurgitant jet area in the receiving chamber and, in cases of significant regurgitation, flow convergence into the regurgitant orifice (Figure 1). Experience has shown that attention to these three components of the regurgitation lesion by color Doppler—as opposed to the traditional regurgitant jet area alone—significantly improves the overall accuracy of estimation and quantitation of the severity of regurgitation with color

Doppler techniques. The size of the regurgitation jet by color Doppler and its temporal resolution however, are significantly affected by transducer frequency and instrument settings such as gain, output power, Nyquist limit, size and depth of the image sector.<sup>4</sup> Thus, full knowledge by the sonographer and interpreting echocardiographer of these issues is necessary for optimal image acquisition and accuracy of interpretation.

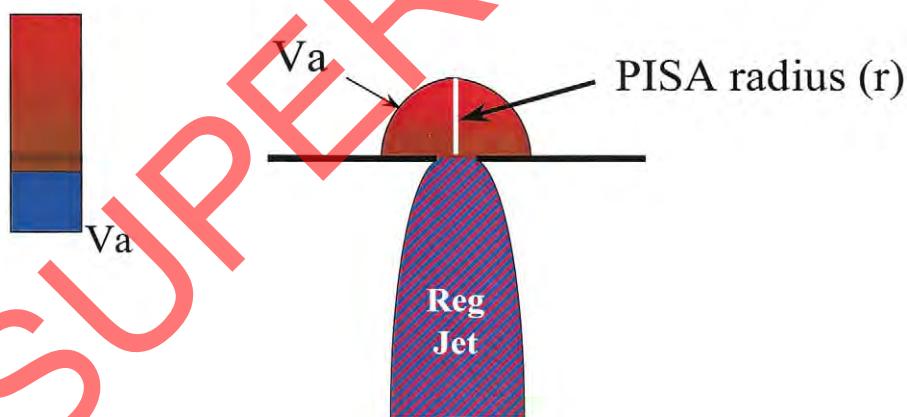
**Jet area.** Visualization of the regurgitant jet area in the receiving chamber can provide a rapid screening of the presence and direction of the regurgitant jet and a semi-quantitative assessment of its severity. In general, a larger area may translate into a more significant regurgitation. However, the sole reliance on this parameter can be quite misleading. Numerous technical, physiologic and anatomic factors affect the size of the regurgitant area and therefore alter its accuracy as an index of regurgitation severity.<sup>4</sup> Jet size is affected by instrument factors, especially pulse repetition frequency (PRF) and color gain. Standard technique is to use a Nyquist limit (aliasing velocity) of 50-60 cm/sec, and a color gain that just eliminates random color speckle from non-moving regions. Jet area is inversely proportional to PRF, and substantial error can be introduced with use of higher or lower settings than the nominal settings to which echocardiographers have become accustomed. Regarding hemodynamic factors, eccentric, wall-impinging jets appear significantly smaller than centrally directed jets of similar hemodynamic severity, mainly because they flatten out on the wall of the receiving chamber. Their presence however, should also alert to the possibility of structural abnormalities of the valve (eg. prolapse, flail, or perforation), frequently in the leaflet or cusp opposite to the direction of the jet. Lastly, Color flow area is also influenced by flow momentum—the product of flow rate and velocity. Thus a jet may appear larger by increasing the driving pressure across the valve; hence the importance of measuring blood pressure for left heart lesions at the time of the echocardiographic examination, particularly in the intraoperative setting.

**Vena contracta.** The vena contracta is the narrowest portion of a jet that occurs at or just downstream from the orifice (Figure 1). It is characterized by high velocity, laminar flow and is slightly smaller than the anatomic regurgitant orifice due to boundary effects. Thus, the cross-sectional area of the vena contracta represents a measure of the effective regurgitant orifice area (EROA), which is the narrowest area of actual flow. The size of the vena contracta is independent of flow rate and driving pressure for a fixed orifice.<sup>5</sup> However, if the regurgitant orifice is dynamic, the vena contracta may change with hemodynamics or during the cardiac cycle.<sup>6</sup> Comprised of high velocities, the vena con-



**Figure 1** Color flow recording of a mitral regurgitation jet obtained from a zoomed view in the parasternal long axis depicting the 3 components of the regurgitant jet: flow convergence, vena contracta (VC), and jet area in the left atrium. Measurement of the vena contracta is shown between the red arrows.

## Flow Convergence Method



$$\text{Reg Flow} = 2\pi r^2 \times Va$$

$$\text{EROA} = \text{Reg Flow} / PkV_{\text{Reg}}$$

**Figure 2** Schematic depiction of the flow convergence or proximal isovelocity surface area (PISA) method for quantitating valvular regurgitation.  $Va$  is the velocity at which aliasing occurs in the flow convergence towards the regurgitant orifice.  $PkV_{\text{Reg}}$ , Peak velocity of the regurgitant jet, determined by continuous wave Doppler. *Reg flow*, regurgitant flow; *EROA*, effective regurgitant orifice area; *Reg jet*, regurgitation jet.



tracta is considerably less sensitive to technical factors such as PRF compared to the jet in the receiving chamber. To specifically image the vena contracta, it is often necessary to angulate the transducer out of the normal echocardiographic imaging planes such that the area of proximal flow acceleration, the vena contracta, and the downstream expansion of the jet can be distinguished. It is preferable to use a zoom mode to optimize visualization of the vena contracta and facilitate its measurement. The color flow sector should also be as narrow as possible, with the least depth, to maximize lateral and temporal resolution. Because of the small values of the width of the vena contracta (usually < 1 cm), small errors in its measurement may lead to a large percent error and misclassification of the severity of regurgitation, hence the importance of accurate acquisition of the primary data and measurement.

*Proximal isovelocity surface area (PISA) or flow convergence.* The PISA method is derived from the hydrodynamic principle stating that, as blood approaches a regurgitant orifice, its velocity increases forming concentric, roughly hemispheric shells of increasing velocity and decreasing surface area.<sup>7</sup> Color flow mapping offers the ability to image one of these hemispheres that corresponds to the Nyquist limit of the instrument. If a Nyquist limit can be chosen at which the flow convergence has a hemispheric shape, flow rate (ml/s) through the regurgitant orifice is calculated as the product of the surface area of the hemisphere ( $2\pi r^2$ ) and the aliasing velocity ( $V_a$ ) as:  $2\pi r^2 * V_a$  (Figure 2). Assuming that the maximal PISA radius occurs at the time of peak regurgitant flow and peak regurgitant velocity, the maximal EROA is derived as:

$$\text{EROA} = (6.28 r^2 * V_a) / PkV_{\text{reg}}$$

where  $PkV_{\text{reg}}$  is the peak velocity of the regurgitant jet by CW Doppler. The regurgitant volume can be estimated as EROA multiplied by the velocity time integral of the regurgitant jet. Since the PISA calculation provides an instantaneous peak flow rate, EROA by this approach is the maximal EROA and may be slightly larger than EROA calculated by other methods.

Measurement of PISA by color flow mapping requires adjustment of the aliasing velocity such that a well-defined hemisphere is shown. This is generally done by shifting the baseline toward the direction of flow, or by lowering the Nyquist limit, or both (the latter reduces the wall filter, whereas the former does not).<sup>8</sup> If the base of the hemisphere is not a flat surface ( $180^\circ$ ), then correction for wall constraint should be performed, multiplying by the ratio of the angle formed by the walls adjacent to the regurgitant orifice and 180 degrees. This has been

shown to improve the reliability of the measurement.<sup>9</sup>

The limitations of PISA have been reviewed in detail.<sup>10</sup> It is more accurate for central jets than for eccentric jets, and for regurgitation with a circular orifice. If the image resolution allows the flow convergence to be seen well, and a Nyquist limit can be chosen at which the flow convergence has a hemispheric shape, it is easy to identify the aliasing line of the hemisphere. However, it can be difficult to judge the precise location of the orifice and the flow convergence shape. Any error introduced is then squared, which can markedly affect the resulting flow rate and EROA. Recent modifications of the described PISA method use the distance between two aliasing contours to circumvent the errors from imprecise location of the orifice in the standard PISA formula, and automate localizing the most hemispheric shape.<sup>11</sup> Although promising, further experience is needed with these methods.

All the color Doppler parameters discussed above provide instantaneous measures of regurgitation severity. Criteria for these maximum instantaneous measurements corresponding to the severity of each lesion assume a pan-systolic (or pan-diastolic) duration. However, in some circumstances, such as mitral valve prolapse, the duration of regurgitation may be brief<sup>12</sup> and can be suspected from real-time, 2D Color Doppler. A time-based graphic, such as CW Doppler or color M mode, can better ascertain this finding. Although graphing the actual duration of such flow patterns has not been systematically studied, a correction of color flow indices of regurgitation for the duration of regurgitation is advised.

**b. Pulsed Doppler quantitative flow methods.** PW Doppler recordings of flow velocity can be combined with 2D measurements to derive flow rates and stroke volume.<sup>13</sup> The technical details involved in making these measurements and their sources of error are described in the document on Quantitation of Doppler Echocardiography.<sup>3</sup> This method is simple in theory but accurate results require individual training (e.g. practice in normal patients where the stroke volumes at different sites are equal). Briefly, stroke volume (SV) at any valve annulus—the least variable anatomic area of a valve apparatus—is derived as the product of cross sectional area (CSA) and the velocity time integral (VTI) of flow at the annulus. Assumption of a circular geometry has worked well clinically for most valves with the exception of the tricuspid annulus. Thus,

$$\text{SV} = \text{CSA} \times \text{VTI} = \pi d^2 / 4 \times \text{VTI} = 0.785 d^2 \times \text{VTI}$$

where  $d$  is the diameter of the annulus. Calculations of stroke volume can be made at two or more different sites—left ventricular outflow tract (LVOT), mitral annulus, and pulmonic annulus. In the absence of regurgitation, stroke volume determinations at these sites are equal. In the presence of

regurgitation of one valve, without any intracardiac shunt, the flow through the affected valve is larger than through other competent valves. The difference between the two represents the regurgitant volume.<sup>14,15</sup> Regurgitant fraction is then derived as the regurgitant volume divided by the forward stroke volume through the regurgitant valve. Thus,

$$\text{Regurgitant Volume} = SV_{\text{RegValv}} - SV_{\text{CompValv}}$$

$$\text{Regurgitant Fraction} = (SV_{\text{RegValv}} - SV_{\text{CompValv}})/SV_{\text{RegValv}}$$

where  $SV_{\text{RegValv}}$  is stroke volume derived at the annulus of the regurgitant valve and  $SV_{\text{CompValv}}$  is the stroke volume at the competent valve. Effective regurgitant orifice area can be calculated similar to the PISA method as regurgitant volume divided by the velocity time integral of the regurgitant jet velocity ( $VTI_{\text{RegJet}}$ ) recorded by CW Doppler as:

$$\text{EROA} = \text{Regurgitant Volume}/VTI_{\text{RegJet}}$$

The most common errors encountered in determining these parameters are 1) failure to measure the valve annulus properly (error is squared in the formula), 2) failure to trace the modal velocity (brightest signal representing laminar flow) of the pulsed Doppler tracing and 3) failure to position the sample volume correctly, and with minimal angulation, at the level of the annulus. Furthermore, in the case of significant calcifications of the mitral annulus and valve, quantitation of flow at the mitral site is less accurate and more prone to errors.

In left sided regurgitant lesions,  $SV_{\text{RegValv}}$  or total stroke volume of the ventricle can also be measured using left ventricular volume calculations by 2D echocardiography as end-diastolic volume minus end-systolic volume. Methods for calculation of left ventricular volumes have been previously detailed.<sup>2</sup> Measurement of left ventricular volumes by echocardiography has the potential pitfall of underestimating true left ventricular volume and therefore underestimating regurgitation severity. Recently, the use of intravenous contrast agents that cross the pulmonary circulation has shown promise in facilitating the tracing of the ventricular endocardium and improving the accuracy and reproducibility of volume measurements.<sup>16,17</sup> Assessment of ventricular volumes based on M-mode echocardiography has important limitations and is not recommended.

**c. Other pulsed and continuous wave Doppler methods.** There are several Pulsed and CW Doppler methods that give indirect clues to the significance of valvular regurgitation. In general, the density of the spectral display of a regurgitant jet is proportional to the number of red cells exhibiting regurgitation and is a qualitative index of severity. Other parameters result from the hemodynamic consequences of the severity of regurgitation and are more valve specific (atrio-ventricular valve versus

aortic or pulmonic valve). For atrio-ventricular valves, these parameters include the magnitude of the early inflow velocity (E), the pulmonary or hepatic venous inflow pattern, and the contour or shape of the regurgitant jet by CW Doppler. For aortic and pulmonic valve insufficiency, the parameter used is the rate of deceleration of the regurgitant jet velocity (pressure half-time), which reflects the rapidity of equilibration of diastolic arterial and ventricular pressures. Another index of severity of aortic insufficiency is the magnitude of diastolic flow reversal in the aorta. Although helpful in the overall evaluation of regurgitation, these parameters are in general sensitive but less specific for the severity of regurgitation, as they are influenced by other hemodynamic and clinical conditions. These methods will be discussed in detail for each valve (see below).

### 3. Doppler Methods in Acute Versus Chronic Regurgitation

Color Doppler measures are particularly deceptive in acute regurgitation, leading to the clinical paradox of apparently small jet size in a critically ill patient, especially from the transthoracic echocardiogram.<sup>18,19</sup> This is related in part to technical factors, particularly insufficient color Doppler temporal resolution in the tachycardic patient; practically, frame rate should therefore be maximized.<sup>20</sup> TEE has been felt to provide a more sensitive view, and the decreased depth also maximizes frame rate particularly for mitral regurgitation.<sup>18,19</sup> More fundamentally, however, the short duration of regurgitation and small receiving chambers limit the maximal development of jet area, and the rapid equalization of pressures diminishes orifice velocity, jet momentum, and therefore jet area.<sup>21,22</sup> The proximal jet or vena contracta remains reliable in this setting, as does pulsed Doppler quantitation. Doppler hemodynamic signs of elevated receiving chamber pressures, such as short aortic insufficiency pressure half-time, early truncation of mitral regurgitant velocities, and pulmonary venous flow reversal, are particularly informative in this setting, and may provide the only clues to significant regurgitation. In this clinical scenario of suspected acute valvular regurgitation, TEE is encouraged for a more definite diagnosis and improved patient management.<sup>19,23</sup>

### 4. Grading the Severity of Valvular Regurgitation

Characterization of the severity of regurgitant lesions is among the most difficult problems in valvular heart disease. Such a determination is important since mild regurgitation does not lead to remodeling of cardiac chambers and has a benign clinical course, whereas severe regurgitation is associated with significant remodeling,

morbidity and mortality.<sup>1</sup> Contributing to the difficulty of assessment of regurgitation is the lack of a true gold standard, and the dependence of regurgitation severity on the hemodynamic conditions at the time of evaluation. Although angiography has been used historically to define the degree of regurgitation based on opacification of the receiving chamber, it is also dependent on several technical factors and hemodynamics.<sup>24-27</sup> For example, an increase in blood pressure will increase all parameters of aortic or mitral regurgitation, be it assessed as regurgitant fraction or angiographic grade. Furthermore, the angiographic severity grades, which have ranged between 3 and 5 grades, have only modest correlations with quantitative indices of regurgitation.<sup>14,24-28</sup>

Doppler methods for valvular regurgitation have been validated in vitro and in animal models against independent flow parameters, and clinically—mostly in adults, against the angiographic standard. The majority of these validation studies have involved left sided cardiac valves. As already discussed, there are several qualitative and quantitative echocardiographic parameters that can provide assessment of valvular regurgitation. The availability of these different parameters provides an internal verification and corroboration of the severity of the lesion, particularly when technical or physiologic conditions preclude the use of one or the other of these indexes. This multi-faceted approach is essential. If there are signs suggesting that the regurgitation is significant and the quality of the data lends itself to quantitation, it is desirable for echocardiographers with experience in quantitative methods to determine quantitatively the degree of regurgitation, particularly for left sided lesions. Ultimately, the interpreter must integrate the information and disregard “outlying” data (because of poor quality or a physiologic condition that alters accuracy of a certain parameter), making a best estimate of regurgitation severity.

The consensus of the Task Force is to classify grading of severity of regurgitation into mild, moderate, and severe. In cases of overlap or intermediate severity, the terms “mild-to-moderate” or “moderate-to-severe” can be used. “Trace” regurgitation is also used in the event that regurgitation is barely detected. Usually this can be physiologic, particularly in right heart valves and mitral valve, and may not produce an audible murmur.

Finally, the echocardiographic and Doppler examination in a patient with valvular regurgitation is best interpreted within the clinical context at the time of the examination. It has been clearly demonstrated that the severity of regurgitation may be influenced by hemodynamic conditions. Therefore, it is essential to record the patient’s blood pressure at the time of the study and note the patient’s medications whenever possible. When following a patient with

serial examinations, these factors need to be considered in comparing the severity of regurgitation and its hemodynamic consequences.

The following sections detail the use of 2D and Doppler echocardiographic methods for the evaluation of each valvular lesion and provide suggested criteria and approach for the assessment of the severity of regurgitation.

## C. MITRAL REGURGITATION

### 1. Role of Two-dimensional Echocardiography

Evaluation of the anatomy of the mitral valve apparatus by 2D echocardiography is critically important in the assessment of severity of mitral regurgitation (MR). The mitral apparatus includes the leaflets, chordae tendineae, annulus, and the papillary muscles with their supporting left ventricular (LV) walls. Careful evaluation of these structures should be able to define the mechanism of MR and yield clues to its severity. For example, a prominent flail leaflet is usually associated with severe MR. On the other hand, severe MR rarely occurs in the setting of an anatomically normal mitral valve and support apparatus. Defining the mechanism of MR may determine whether valve repair is feasible instead of valve replacement.<sup>29,30</sup> In patients with MR in the setting of LV dilatation and/or systolic dysfunction, it is important to determine whether MR is functional (i.e. due to LV dilatation) or primary (i.e. due to an abnormality of the valve apparatus). In functional MR, the leaflets are usually tethered by outward displacement of the LV walls and papillary muscles, with or without annular dilation.<sup>31</sup> Underlying wall motion abnormalities in patients with coronary artery disease may also lead to functional MR. Finally, evaluation of left atrial (LA) size and LV size and function provides clues to the severity of MR, its acuteness or chronicity, and are important in determining the necessity and timing of surgery.<sup>1,32</sup> Normal 2D-derived values for left ventricular size and function have been previously reported.<sup>2</sup> Briefly, the end-diastolic minor axis dimension of the LV obtained from the parasternal window by 2D is normally  $\leq 2.8$  cm/m<sup>2</sup> while the normal end-diastolic LV volume is  $< 82$  ml/m<sup>2</sup>.<sup>2</sup> For the left atrium, a normal antero-posterior diameter is  $\leq 2$  cm/m<sup>2</sup>.<sup>33</sup> Recent studies however have shown that determination of LA volumes with 2D echocardiography from the apical views is generally more accurate in assessing LA size than the traditional antero-posterior dimension.<sup>34</sup> A normal maximal LA volume is  $\leq 36$  ml/m<sup>2</sup>.<sup>35</sup>

### 2. Doppler Methods

**a. Color flow Doppler.** Color Doppler flow mapping is widely used to screen for the presence of

**Table 1** Qualitative and quantitative parameters useful in grading mitral regurgitation severity

	Mild	Moderate	Severe
<b>Structural parameters</b>			
LA size	Normal*	Normal or dilated	Usually dilated**
LV size	Normal*	Normal or dilated	Usually dilated**
Mitral leaflets or support apparatus	Normal or abnormal	Normal or abnormal	Abnormal/ Flail leaflet/ Ruptured papillary muscle
<b>Doppler parameters</b>			
Color flow jet area <sup>‡</sup>	Small, central jet (usually < 4 cm <sup>2</sup> or < 20% of LA area)	Variable	Large central jet (usually > 10 cm <sup>2</sup> or > 40% of LA area) or variable size wall-impinging jet swirling in LA
Mitral inflow –PW	A wave dominant <sup>§</sup>	Variable	E wave dominant <sup>§</sup> (E usually 1.2 m/s)
Jet density –CW	Incomplete or faint	Dense	Dense
Jet contour –CW	Parabolic	Usually parabolic	Early peaking–triangular
Pulmonary vein flow	Systolic dominance <sup>¶</sup>	Systolic blunting <sup>¶</sup>	Systolic flow reversal†
<b>Quantitative parameters<sup>‡</sup></b>			
VC width (cm)	< 0.3	0.3-0.69	≥ 0.7
R Vol (ml/beat)	< 30	30-44      45-59	≥ 60
RF (%)	< 30	30-39      40-49	≥ 50
EROA (cm <sup>2</sup> )	< 0.20	0.20-0.29      0.30-0.39	≥ 0.40

CW, Continuous wave; LA, left atrium; EROA, effective regurgitant orifice area; LV, left ventricle; PW, pulsed wave; RF, regurgitant fraction; R Vol, regurgitant volume; VC, vena contracta.

\* Unless there are other reasons for LA or LV dilation. Normal 2D measurements: LV minor axis ≤ 2.8 cm/m<sup>2</sup>, LV end-diastolic volume ≤ 82 ml/m<sup>2</sup>, maximal LA antero-posterior diameter ≤ 2 cm/m<sup>2</sup>, maximal LA volume ≤ 36 ml/m<sup>2</sup> (2,33,35).

\*\* Exception: acute mitral regurgitation.

‡ At a Nyquist limit of 50–60 cm/s.

† Pulmonary venous systolic flow reversal is specific but not sensitive for severe MR.

§ Usually above 50 years of age or in conditions of impaired relaxation, in the absence of mitral stenosis or other causes of elevated LA pressure.

¶ Unless other reasons for systolic blunting (eg. atrial fibrillation, elevated left atrial pressure).

<sup>‡</sup> Quantitative parameters can help sub-classify the moderate regurgitation group into mild-to-moderate and moderate-to-severe.

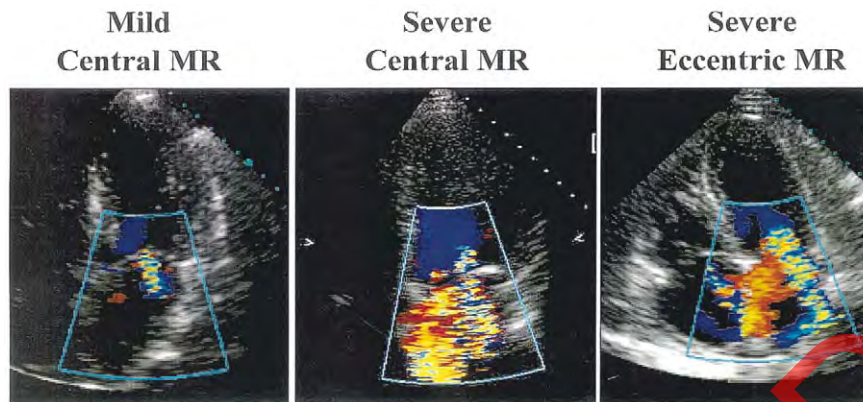
mitral regurgitation. Importantly, small color flow jets are seen in roughly 40% of healthy normal volunteers and therefore are considered a normal variant.<sup>36</sup> The incidence of mild regurgitation tends to increase with age. The terms trace MR or MR closing volume have been applied to these jets. There are three methods of quantifying MR severity by color flow Doppler mapping: regurgitant jet area, vena contracta, and flow convergence (PISA). Although jet area was the first method used for assessing MR severity, its sole use is less accurate than the latter two methods.

**Regurgitant jet area.** As a general rule, large jets that extend deep into the LA represent more MR than small thin jets that appear just beyond the mitral leaflets. However, the correlation between jet area and MR severity is poor due to a variety of technical and hemodynamic limitations as noted earlier.<sup>4</sup> Patients with acute severe MR, in whom blood pressure is low and LA pressure is elevated may have a small eccentric color flow jet area, whereas hypertensive patients with mild MR may have a large jet area. Furthermore, the same regurgitant flow will produce larger or smaller jets depending on the size of the atrium, which has led to indexing for atrial area.<sup>37</sup> Finally, color flow jets that are directed centrally into the LA generally appear

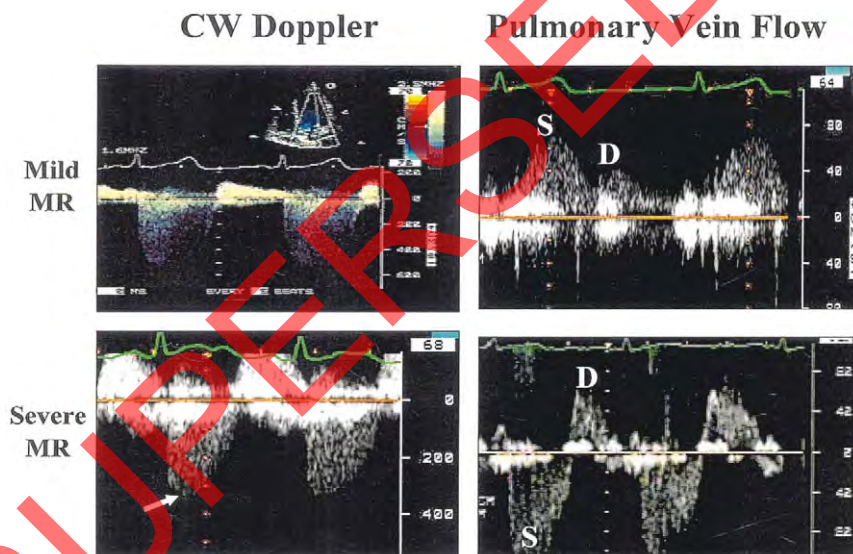
larger because they entrain red blood cells on all sides of the jet. In contrast, eccentric jets that hug the LA wall cannot entrain blood on all sides and tend to appear smaller than central jets of similar or lesser severity (Figure 3).<sup>38-40</sup> Because of these considerations, determination of the severity of MR by “eyeballing” or planimetry of the MR color flow jet area only, is not recommended. Nevertheless, small, non-eccentric jets with an area < 4.0 cm<sup>2</sup> or < 20% of LA area are usually trace or mild MR (Table 1). Conversely, large jets that penetrate into the pulmonary veins are more likely to be hemodynamically significant. However, the detection of eccentric, wall-impinging jets should alert the observer to avoid the use of jet area as an index of severity and use other, more appropriate methods described below.

**Vena contracta.** The vena contracta should be imaged in high-resolution, zoom views for the largest obtainable proximal jet size for measurements. The examiner must search in multiple planes perpendicular to the commissural line (such as the parasternal long-axis view), whenever possible (Figure 1). The width of the neck or narrowest portion of the jet is then measured. The regurgitant orifice in MR may not be circular, and is often elongated along the mitral coaptation line. The two-chamber view, which is oriented parallel to the line of leaflet coaptation,





**Figure 3** Examples of color flow recordings of different mitral regurgitation (*MR*) lesions from the apical window. The case of mild regurgitation has no flow convergence, a small regurgitant jet area, in contrast to that of severe central MR, which shows a prominent flow convergence and a large regurgitant jet area. The example with severe eccentric MR has a small jet area impinging on the wall of the left atrium but a large flow convergence and a wide vena contracta.



**Figure 4** Example of findings of continuous wave (*CW*) Doppler recordings and pulmonary vein flow by pulsed Doppler in a case with mild and another with severe mitral regurgitation (*MR*). In mild *MR*, spectral recording of the jet has a soft density with a parabolic, rounded contour of the regurgitant velocity whereas in severe *MR*, the jet is dense with a triangular, early peaking of the velocity (*arrow*). Pulmonary vein flow is normal in mild *MR* with predominance of systolic flow (*S*). In contrast, the case with severe *MR* displays systolic flow reversal. *D*, Diastolic flow velocity.

generally shows a wide vena contracta even in mild *MR*, and should not be used to measure the vena contracta. Although the size of the vena contracta is independent of flow rate and driving pressure for a fixed orifice,<sup>5</sup> the regurgitant orifice in *MR* is often dynamic and therefore the vena contracta may change with hemodynamics or during systole.<sup>6</sup>

Several studies have shown that the width of the vena contracta is accurate in assessing the severity of *MR*, either by transthoracic or transesophageal echo-

cardiography.<sup>41-45</sup> The width of the vena contracta in long-axis views and its cross-sectional area in short-axis views can be standardized from the parasternal views.<sup>44</sup> A vena contracta < 0.3 cm usually denotes mild *MR* whereas the cut-off for severe *MR* has ranged between 0.6 to 0.8 cm.<sup>43-45</sup> Although intermediate values tend to correlate well with moderate *MR*, there is enough overlap that another method should be used for confirmation. A particular strength of the vena contracta method is



that it works equally well for central and eccentric jets. In fact, in eccentric jets of severe MR, the width of the vena contracta along with flow convergence alerts the echocardiographer to the severity of regurgitation by color Doppler (Figure 3). In patients with multiple MR jets, the respective widths of the vena contracta are not additive, but their cross sectional areas can be.<sup>44</sup> In the future, three-dimensional imaging of the vena contracta should improve the accuracy of measuring EROA by this technique.

**Flow convergence or PISA.** Most of the experience with the PISA method for quantitation of regurgitation is with MR. Qualitatively, the presence of PISA on a routine examination (at Nyquist limit of 50-60 cm/s) should alert to the presence of significant MR. Several clinical studies have validated PISA measurements of regurgitant flow rate and EROA.<sup>12,46,47</sup> As mentioned earlier, there are many technical considerations related to optimal acquisition of flow convergence images and to quantitation of mitral regurgitant orifice area by PISA. This methodology is more accurate for central regurgitant jets than eccentric jets, and for a circular orifice than a non-circular orifice. Flow convergence should be optimized from the apical view, usually the four-chamber view, using a zoom mode. Combining data from two views through the major and minor axes of a non-circular orifice (apical two-chamber and four-chamber views) provides greater accuracy, but adds more complexity.<sup>8,44,48</sup> The size of the PISA has meaning only in terms of the aliasing velocity that defines the color surface. Results vary widely for calculations at different aliasing velocities, and care must be taken to use the velocity at which the hemispheric formula applies best.<sup>49,50</sup> Furthermore, for determination of EROA, it is essential that the CW Doppler signal be well aligned with the regurgitant jet. Poor alignment with an eccentric jet will lead to an underestimation of velocity and an overestimation of the EROA. Generally, an EROA  $\geq 0.4$  cm<sup>2</sup> is consistent with severe MR, 0.20-0.39 cm<sup>2</sup> moderate, and  $< 0.20$  cm<sup>2</sup> mild MR.

**b. Continuous wave Doppler.** In most patients, maximum MR velocity is 4 to 6 m/s due to the high systolic pressure gradient between the LV and LA. The velocity itself does not provide useful information about the severity of MR. However, the contour of the velocity profile and its density are useful. A truncated, triangular jet contour with early peaking of the maximal velocity indicates elevated LA pressure or a prominent regurgitant pressure wave in the LA (Figure 4).

The density of the CW Doppler signal is a qualitative index of MR severity. A dense signal that approaches the density of antegrade flow suggests significant MR, whereas a faint signal, with or without an incomplete envelope represents mild or trace MR, presuming the recording is made through the

vena contracta (Figure 4). In eccentric significant MR, it may be difficult to record the full envelope of the jet because of its eccentricity, while the signal intensity shows dense features. Recently, the returning power of the regurgitant velocity signal, which is proportional to the area of the vena contracta, has been used to obtain instantaneous regurgitant orifice area and flow rate.<sup>51</sup> This method offers considerable promise.

Using CW Doppler, the tricuspid regurgitation jet should be interrogated in order to estimate pulmonary artery systolic pressure. The presence of pulmonary hypertension provides another indirect clue as to MR severity and compensation to the volume overload.

**c. Pulsed Doppler.** Pulsed Doppler tracings at the mitral leaflet tips are commonly used to evaluate LV diastolic function. Patients with severe MR often demonstrate a mitral inflow pattern with a dominant early filling (increased E velocity) due to increased diastolic flow across the mitral valve, with or without an increase in left atrial pressure.<sup>52</sup> In severe mitral regurgitation without stenosis, the mitral E velocity is higher than the velocity during atrial contraction (A velocity), and usually greater than 1.2 m/sec. For these reasons, a mitral inflow pattern with an A-wave dominance virtually excludes severe MR. Because of the effect of relaxation on mitral inflow indices, these observations are more applicable in individuals older than 50 yrs of age or in conditions of impaired myocardial relaxation.

In contrast to ventricular filling dynamics, calculation of flow and stroke volume through the mitral valve with pulsed Doppler is performed at the mitral annulus level. Several studies have shown the validity and clinical utility of quantitative Doppler measurements of MR severity.<sup>14,15,53-55</sup> The values for regurgitant volumes, regurgitant fraction and EROA by quantitative Doppler for various degrees of MR are shown in Table 1. It should be remembered, however, that in individual patients, these values might vary. For example, a patient with severe MR and a small LV may have a low regurgitant volume but a high regurgitant fraction and EROA. There are no data regarding indexing these measurements to body surface area. Quantitative Doppler measurements may be more applicable to patients with a single regurgitant valve. For example, in the presence of combined MR and significant aortic regurgitation, the calculated regurgitant volume will be erroneous if the LV outflow site is used for comparison. In this case, systemic flow could be calculated at the pulmonic annulus. Lastly, the quantitative PW Doppler method offers an advantage in the case of eccentric or multiple regurgitant MR jets, where PISA is not as accurate and vena contracta is not applicable in the latter situation.

**Table 2** Echocardiographic and Doppler parameters used in the evaluation of mitral regurgitation severity: Utility, advantages, and limitations

	Utility/advantages	Limitations
<b>Structural parameters</b>		
LA and LV Size	Enlargement sensitive for chronic significant MR, important for outcomes. Normal size virtually excludes significant chronic MR.	Enlargement seen in other conditions. May be normal in acute significant MR
MV leaflet/support apparatus	Flail valve and ruptured papillary muscle specific for significant MR	Other anomalies do not imply significant MR
<b>Doppler parameters</b>		
Jet area—Color Flow	Simple, quick screen for mild or severe central MR; evaluates spatial orientation of jet	Subject to technical, hemodynamic variation; significantly underestimates severity in wall-impinging jets
Vena contracta width	Simple, quantitative, good at identifying mild or severe MR	Not useful for multiple MR jets; intermediate values require confirmation. Small values; thus small error leads to large % error
PISA method	Quantitative; Presence of flow convergence at Nyquist limit of 50–60 cm/s alerts to significant MR. Provides both, lesion severity (EROA) and volume overload (R Vol)	Less accurate in eccentric jets; not valid in multiple jets, provides peak flow and maximal EROA.
Flow quantitation—PW	Quantitative, valid in multiple jets and eccentric jets. Provides both lesion severity (EROA, RF) and volume overload (R Vol)	Measurement of flow at MV annulus less reliable in calcific MV and/or annulus. Not valid with concomitant significant AR unless pulmonic site is used.
Jet profile—CW	Simple, readily available	Qualitative; complementary data.
Peak mitral E velocity	Simple, readily available, A-wave dominance excludes severe MR	Influenced by LA pressure, LV relaxation, MV area, and atrial fibrillation. Complementary data only, does not quantify MR severity
Pulmonary vein flow	Simple, Systolic flow reversal is specific for severe MR	Influenced by LA pressure, atrial fibrillation. Not accurate if MR jet directed into the sampled vein

CW, Continuous wave Doppler; EROA, effective regurgitant orifice area; LA, left atrium; PISA, proximal isovelocity surface area; LV, left ventricle; PW, pulsed wave Doppler; MV, mitral valve; MR, mitral regurgitation; R Vol, regurgitant volume.

**d. Pulmonary vein flow.** Pulsed Doppler evaluation of pulmonary venous flow is a useful adjunct to evaluating the hemodynamic consequences of MR. Normal pulmonary venous flow is characterized by a velocity during ventricular systole that is higher than during ventricular diastole. With increasing severity of MR, there is a diminution of the systolic velocity. In many patients with severe MR, the flow in the pulmonary veins becomes reversed in systole (Figure 4). Since the mitral regurgitant jet may selectively enter one or the other of the pulmonary veins, sampling through all pulmonary veins is recommended, especially during transesophageal echocardiography. One limitation of pulmonary venous pattern in the assessment of severity of MR is that elevation in LA pressure of any etiology, and atrial fibrillation also result in a blunted systolic forward flow.<sup>56</sup> As a result, the use of pulmonary venous flow pattern should be used adjunctively with other parameters. Nevertheless, the finding of systolic flow reversal in more than one pulmonary vein is

specific but not sensitive for severe mitral regurgitation.

### 3. Role of TEE in Assessing Mitral Regurgitation Severity

TEE is indicated to evaluate MR severity in patients in whom transthoracic echocardiography is inconclusive or technically difficult. In addition, TEE is particularly well suited to identify the underlying mechanism of MR and for planning mitral valve surgery. All of the above methods of quantifying MR can also be used during TEE. In particular, the higher resolution of TEE, multi-plane capabilities, and proximity to the mitral valve makes vena contracta imaging and PISA easier and probably more accurate. On the other hand, since jet size is affected by transducer frequency, pulse repetition frequency, and signal strength, the same jet may appear larger on TEE compared to transthoracic images. Quantitative

**Table 3** Application of specific and supportive signs, and quantitative parameters in the grading of mitral regurgitation severity

	Mild	Moderate	Severe
<b>Specific signs of severity</b>	<ul style="list-style-type: none"> <li>● Small central jet &lt; 4 cm<sup>2</sup> or &lt; 20% of LA area<sup>ψ</sup></li> <li>● Vena contracta width &lt; 0.3 cm</li> <li>● No or minimal flow convergence<sup>ξ</sup></li> </ul>	Signs of MR > mild present, but no criteria for severe MR	<ul style="list-style-type: none"> <li>● Vena contracta width ≥ 0.7 cm <i>with</i> large central MR jet (area &gt; 40% of LA) or <i>with</i> a wall-impinging jet of any size, swirling in LA<sup>ψ</sup></li> <li>● Large flow convergence<sup>ξ</sup></li> <li>● Systolic reversal in pulmonary veins</li> <li>● Prominent flail MV leaflet or ruptured papillary muscle</li> </ul>
<b>Supportive signs</b>	<ul style="list-style-type: none"> <li>● Systolic dominant flow in pulmonary veins</li> <li>● A-wave dominant mitral inflow<sup>φ</sup></li> <li>● Soft density, parabolic CW Doppler MR signal</li> <li>● Normal LV size*</li> </ul>	Intermediate signs/findings	<ul style="list-style-type: none"> <li>● Dense, triangular CW Doppler MR jet</li> <li>● E-wave dominant mitral inflow (E &gt; 1.2 m/s)<sup>φ</sup></li> <li>● Enlarged LV and LA size**, (particularly when normal LV function is present).</li> </ul>
<b>Quantitative parameters<sup>ρ</sup></b>			
R Vol (ml/beat)	< 30	30-44      45-59	≥ 60
RF (%)	< 30	30-39      40-49	≥ 50
EROA (cm <sup>2</sup> )	< 0.20	0.20-0.29      0.30-0.39	≥ 0.40

CW, Continuous wave; EROA, effective regurgitant orifice area; LA, left atrium; LV, left ventricle; MV, mitral valve; MR, mitral regurgitation; R Vol, regurgitant volume; RF, regurgitant fraction.

\* LV size applied only to chronic lesions. Normal 2D measurements: LV minor axis ≈ 2.8 cm/m<sup>2</sup>, LV end-diastolic volume ≤ 82 ml/m<sup>2</sup>, maximal LA antero-posterior diameter ≤ 2.8 cm/m<sup>2</sup>, maximal LA volume ≤ 36 ml/m<sup>2</sup> (2;33;35).

\*\* In the absence of other etiologies of LV and LA dilatation and acute MR.

<sup>ψ</sup> At a Nyquist limit of 50-60 cm/s.

<sup>φ</sup> Usually above 50 years of age or in conditions of impaired relaxation, in the absence of mitral stenosis or other causes of elevated LA pressure.

<sup>ξ</sup> Minimal and large flow convergence defined as a flow convergence radius < 0.4 cm and ≤ 0.9 cm for central jets, respectively, with a baseline shift at a Nyquist of 40 cm/s; Cut-offs for eccentric jets are higher, and should be angle corrected (see text).

<sup>ρ</sup> Quantitative parameters can help sub-classify the moderate regurgitation group into mild-to-moderate and moderate-to-severe as shown.

pulsed Doppler by TEE works well provided that a deep transgastric view is obtained to properly align the PW Doppler beam to the LV outflow tract. The latter however, is more difficult than with the transthoracic approach. Interrogation of all pulmonary veins is generally feasible with TEE.

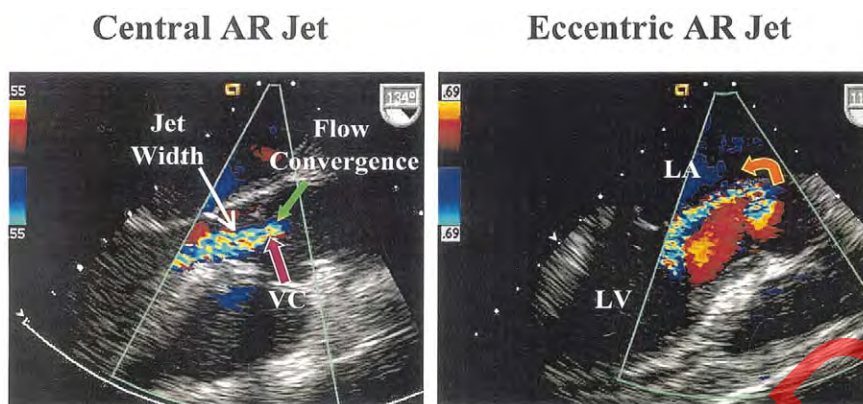
#### 4. Integrative Approach to Assessment of Mitral Regurgitation Severity

The approach to evaluation of MR severity ideally integrates multiple parameters rather than depends on a single measurement. This helps minimize the effects of technical or measurement errors that are inherent to each method previously discussed. It is also important to distinguish between the amount of MR and its hemodynamic consequences. For example, a modest regurgitant volume that develops acutely into a small, non-compliant LA may cause severe pulmonary congestion and systemic hypotension. Conversely, some patients with chronic severe MR remain

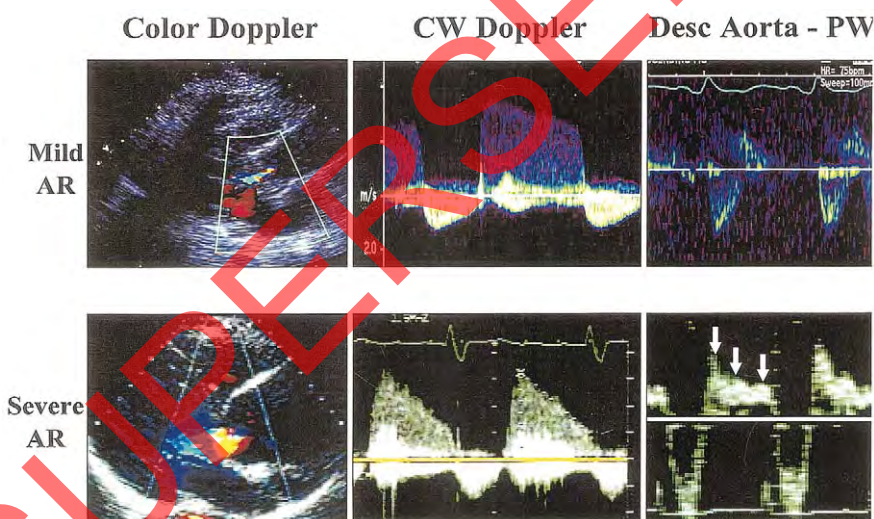
asymptomatic due to compensatory mechanisms and a dilated, compliant LA.

Parameters that describe the amount of MR include vena contracta width, regurgitant volume and fraction, and EROA calculated either by PISA or quantitative pulsed Doppler. Because regurgitant flows may be holosystolic or brief, as in valve prolapse,<sup>12</sup> color Doppler techniques should be adjusted for duration of MR: for example, a wide vena contracta occurring briefly conveys only mild MR. On the other hand, the hemodynamic consequences of MR are reflected in several parameters including LA and LV volumes, the contour of the CW Doppler profile, and pulmonary venous flow pattern. Advantages and limitations of the various echo/Doppler parameters used in assessing severity of MR are detailed in Table 2. An MR index has been devised that assigns different weights to six different indicators of MR,<sup>57</sup> using a score of 0-3 for jet penetration into the LA, PISA radius, CW jet intensity, pulmonary artery pressure, pulmonary venous





**Figure 5** Examples of central and eccentric aortic regurgitation (AR) jets recorded by transesophageal echocardiography. The components of AR by color Doppler are highlighted by *arrows* in the example of central AR: flow convergence, vena contracta (VC) and jet width in the left ventricular outflow tract. Note the smaller size and location of the vena contracta compared to the jet width in the LV outflow tract. The eccentric AR jet is directed towards the mitral valve (*arrow*) with a prominent flow convergence. Jet width in the left ventricular outflow in this eccentric jet cannot be used for evaluation of AR severity. LA, Left atrium; LV, left ventricle.



**Figure 6** Color Doppler and continuous wave (CW) Doppler recordings of the regurgitant jet as well as pulsed wave (PW) Doppler recording of flow in the descending thoracic aorta in examples of mild and severe aortic regurgitation (AR). Compared to the mild AR, the case of severe AR has a large jet width in the left ventricular outflow, a steep deceleration rate of the AR velocity by CW Doppler, and a holo-diastolic flow reversal in the descending (*desc*) aorta (*arrows*).

flow pattern, and LA size. A score of 1.7 or less reliably separated mild MR from severe MR; a considerable overlap however was observed between moderate and severe MR. Although it may be impractical for routine clinical use, this scoring system emphasizes the need to evaluate multiple echocardiographic parameters.

Based on data in the literature and a consensus of the committee members, the Task Force proposes a scheme of specific signs ( $\geq 90\%$  specificity), along

with supportive signs and quantitative parameters to help grade the severity of MR (Table 3). In applying this scheme, the Task Force also wishes to recognize the following. The specific signs have inherently a high positive predictive value for the severity of regurgitation. On the other hand, the supportive signs or clues may be helpful in consolidating the impression of the degree of MR, although their predictive value is more modest, since they are influenced by several factors (Table 2). It is the consensus of the committee mem-

**Table 4** Qualitative and quantitative parameters useful in grading aortic regurgitation severity

	Mild	Moderate	Severe
<b>Structural parameters</b>			
LA size	Normal*	Normal or dilated	Usually dilated**
Aortic leaflets	Normal or abnormal	Normal or abnormal	Abnormal/flail, or wide coaptation defect
<b>Doppler parameters</b>			
Jet width in LVOT –Color Flow <sup>‡</sup>	Small in central jets	Intermediate	Large in central jets; variable in eccentric jets
Jet density–CW	Incomplete or faint	Dense	Dense
Jet deceleration rate –CW (PHT, ms) <sup>§</sup>	Slow > 500	Medium 500-200	Steep < 200
Diastolic flow reversal in descending aorta –PW	Brief, early diastolic reversal	Intermediate	Prominent holodiastolic reversal
<b>Quantitative parameters<sup>¶</sup></b>			
VC width, cm <sup>‡</sup>	< 0.3	0.3-0.60	> 0.6
Jet width/LVOT width, % <sup>‡</sup>	< 25	25-45 46-64	≥ 65
Jet CSA/LVOT CSA, % <sup>‡</sup>	< 5	5-20 21-59	≥ 60
R Vol, ml/beat	< 30	30-44 45-59	≥ 60
RF, %	< 30	30-39 40-49	≥ 50
EROA, cm <sup>2</sup>	< 0.10	0.10-0.19 0.20-0.29	≥ 0.30

AR, Aortic regurgitation; CSA, cross sectional area; CW, continuous wave Doppler; EROA, effective regurgitant orifice area; LV, left ventricle; LVOT, left ventricular outflow tract; PHT, pressure half-time; PW, pulsed wave Doppler; R Vol, regurgitant volume; RF, regurgitant fraction; VC, vena contracta.

\* Unless there are other reasons for LV dilation. Normal 2D measurements: LV minor axis  $\leq 2.8$  cm/m<sup>2</sup>, LV end-diastolic volume  $\leq 82$  ml/m<sup>2</sup> (2).

\*\* Exception: would be acute AR, in which chambers have not had time to dilate.

<sup>‡</sup> At a Nyquist limit of 50–60 cm/s.

<sup>§</sup> PHT is shortened with increasing LV diastolic pressure and vasodilator therapy, and may be lengthened in chronic adaptation to severe AR.

<sup>¶</sup> Quantitative parameters can sub-classify the moderate regurgitation group into mild-to-moderate and moderate-to-severe regurgitation as shown.

bers that the process of grading MR should be comprehensive, using a combination of clues, signs and measurements obtained by Doppler echocardiography. If the MR is definitely determined as mild or less using these signs, no further measurement is required. If there are signs suggesting that the MR is more than mild and the quality of the data lends itself to quantitation, it is desirable for echocardiographers with experience in quantitative methods to determine quantitatively the degree of MR, including the regurgitant volume and fraction as descriptors of volume overload and the effective regurgitant orifice as a descriptor of the lesion severity. It is also the consensus of the Task Force that the wording chosen for expressing the degree of MR, which is a continuum best defined by quantitative measurements, can include qualifiers such as mild-to-moderate to describe the lowest end of the moderate range, moderate-to-severe to describe the upper end of the moderate range. Finally, it is important to stress that when the evidence from the different parameters is congruent, it is easy to grade MR severity with confidence. When different parameters are contradictory, one must look carefully for technical and physiologic reasons to explain any discrepancies and rely on the components that have the best inherent quality of the primary data and are the most accurate considering the underlying physiologic condition.

## D. AORTIC REGURGITATION

The assessment of aortic regurgitation (AR) is based on a comprehensive utilization of 2D echocardiography, color-flow imaging, pulsed and CW Doppler techniques and is essential in the clinical evaluation of aortic valvular disease.<sup>1</sup> The echocardiographic and Doppler evaluation of AR uses qualitative and quantitative measures that can be derived in a single examination. While qualitative or semiquantitative measures are used uniformly, quantitative measures are often more time-consuming and are used more selectively.

### 1. Role of Two-dimensional Echocardiography

Two-dimensional echocardiography provides important information regarding valve anatomy and structural deformities, presence and severity of aortic root dilatation and adaptation of the LV to the volume overload state. While mild degrees of AR are associated in general with mild pathology of the valve and aortic root and do not result in LV remodeling, severe chronic AR is usually observed in the setting of significant structural abnormalities of the valve or aortic root, and results in LV enlargement in the chronic state. Importantly, evaluation of

LV size and function in significant AR provides clues as to the acuteness or chronicity of the regurgitation and helps determine management strategies and timing of surgical intervention.

## 2. Doppler Methods

**a. Color flow Doppler.** Color-Flow imaging directly shows the regurgitant flow through the aortic valve during diastole. The regurgitant flow has 3 components that can be visualized: the flow convergence region in the aorta, the vena contracta through the regurgitant orifice, and the jet direction and size in the left ventricle (Figure 5).

*Regurgitant jet size.* Imaging of the regurgitant jet is used in all patients with AR because of its simplicity and real time availability.<sup>58</sup> The length of jet penetration into the left ventricle is an unsatisfactory indicator of AR severity.<sup>59</sup> The preferred assessment is based on the proximal jet width or cross-sectional area immediately below the aortic valve, within 1 cm of the valve.<sup>59,60</sup> The parasternal views are preferred over apical views because of better axial resolution. The recommended measurements are those of maximal proximal jet width obtained from the long-axis views and its ratio to the LV outflow tract diameter.<sup>59</sup> Similarly, the cross-sectional area of the jet from the parasternal short-axis view and its ratio to the LV outflow tract area can also be used.<sup>59</sup> The criteria to define severe AR are ratios of  $\geq 65\%$  for jet width and  $\geq 60\%$  for jet area (Table 4) (Figure 6). Although small jets reliably reflect small degrees of AR, there are important limitations to color-flow imaging of regurgitant jet, similar to mitral regurgitation.<sup>38,40</sup> Jet shape may affect the measurements. If the proximal jet does not have a shape with parallel borders in the LV outflow, it is difficult to know where to measure it. Jet direction is also a confounding variable. Eccentric jets that are directed predominantly to the anterior leaflet of the mitral valve (Figure 5) or the septum tend to occupy a small portion of the proximal outflow tract and may thus appear narrow and underestimate the severity of regurgitation.<sup>38</sup> Conversely, central jets tend to expand fully in the outflow tract and may be overestimated. Furthermore, the severity of AR in diffuse jets arising from the entire coaptation line is also poorly evaluated by color-flow imaging. This can be suspected from short axis imaging at the aortic valve. In practice, the assessment of AR based on jet size in the LV outflow is most often based on visual estimation rather than direct quantitative measurement and is used as a gross indicator of the degree of AR.

*Vena contracta.* The vena contracta is defined as the smallest neck of the flow region at the level of the aortic valve, immediately below the flow convergence region. It is different from the jet width discussed above, which is measured in the LVOT,

below the aortic valve (Figure 5). The measurement of vena contracta width is significantly smaller than that of jet width in the LVOT because the jet expands immediately after the vena contracta. Imaging of the vena contracta is obtained similarly from parasternal long-axis views.<sup>61</sup> The vena contracta provides an estimate of the size of the EROA. To appropriately visualize the vena contracta, it is essential to see all 3 components of the regurgitant flow, i.e., the flow convergence, the vena contracta and the jet.<sup>61</sup> Measurement of vena contracta is simple and has a high feasibility both by transthoracic and transesophageal echocardiography. Furthermore, it appears to be more robust than jet width and area in the LVOT for the assessment of AR severity.<sup>61</sup> Limitations of this parameter occur in the presence of multiple jets or jets with irregular shapes, where one diameter may not be reflective of the severity of the AR; a short-axis view however will provide a better appreciation of the regurgitation.<sup>62</sup> The thresholds of vena contracta width associated with severe AR are 0.5 cm as a highly sensitive threshold, 0.7 cm as a highly specific threshold and 0.6 cm as the threshold with the best combination of specificity and sensitivity.<sup>61</sup>

*Flow convergence or PISA.* Considerably less experience exists with PISA for the assessment of AR compared to MR. Imaging of the proximal flow convergence region by transthoracic echo is performed from the apical, para-apical views, or the upper right-sternal border, with images zoomed on the valvular and supra-valvular region. The Nyquist limit is adjusted to obtain a rounded and measurable flow convergence zone and the aliasing radius is measured from the stop frame with the largest observable PISA. CW Doppler recording of the regurgitant peak velocity and velocity time integral allows calculation of the EROA and regurgitant volume. This method has been shown to provide accurate quantitation of AR.<sup>63</sup> However, it is feasible in a lower percentage of patients compared to MR due to interposition of valve tissue (apical views) and difficulty in obtaining high quality images of the flow convergence region. Another pitfall is related to the timing of measurement of the flow convergence radius, which should be in early diastole, closest to the peak regurgitant velocity. Furthermore, ascending aortic aneurysms, which deform the valvular plane, may lead to underestimation of AR by this method.<sup>63</sup> The thresholds for severe AR are an EROA  $\geq 0.30$  cm<sup>2</sup> and a regurgitant volume  $\geq 60$  ml.

**b. Pulsed wave Doppler.** *Aortic diastolic flow reversal.* It is normal to observe a brief diastolic flow reversal in the aorta. The flow reversal is best recorded in the upper descending aorta at the aortic isthmus level using a suprasternal view, or in the lower descending aorta using a longitudinal subcos-



**Table 5** Echocardiographic and Doppler parameters used in the evaluation of aortic regurgitation severity: Utility, advantages, and limitations

	Utility/Advantages	Limitations
<b>Structural parameters</b>		
LV size	Enlargement sensitive for chronic significant AR, important for outcomes. Normal size virtually excludes significant chronic AR.	Enlargement seen in other conditions. May be normal in acute significant AR
Aortic cusps alterations	Simple, usually abnormal in severe AR; Flail valve denotes severe AR	Poor accuracy, may grossly underestimate or overestimate the defect
<b>Doppler parameters</b>		
Jet width or jet cross-sectional area in LVOT –Color Flow	Simple, very sensitive, quick screen for AR	Expands unpredictably below the orifice. Inaccurate for eccentric jets
Vena contracta Width	Simple, quantitative, good at identifying mild or severe AR	Not useful for multiple AR jets. Small values; thus small error leads to large % error
PISA method	Quantitative. Provides both lesion severity (EROA) and volume overload (R vol)	Feasibility is limited by aortic valve calcifications. Not valid for multiple jets, less accurate in eccentric jets. Provides peak flow and maximal EROA. Underestimation is possible with aortic aneurysms. Limited experience.
Flow quantitation–PW	Quantitative, valid with multiple jets and eccentric jets. Provides both lesion severity (EROA, RF) and volume overload (R Vol)	Not valid for combined MR and AR, unless pulmonic site is used.
Jet density–CW	Simple. Faint or incomplete jet compatible with mild AR	Qualitative. Overlap between moderate and severe AR. Complementary data only
Jet deceleration rate (PHT) –CW	Simple	Qualitative; affected by changes in LV and aortic diastolic pressures.
Diastolic flow reversal in descending aorta –PW	Simple	Depends on rigidity of aorta. Brief velocity reversal is normal

AR, Aortic regurgitation; CW, continuous wave Doppler; EROA, effective regurgitant orifice area; LV, left ventricle; LVOT, left ventricular outflow tract; MR, mitral regurgitation; PHT, pressure half-time; PW, pulsed wave Doppler; R Vol, regurgitant volume; RF, regurgitant fraction; VC, vena contracta width.

tal view. With increasing aortic regurgitation both, the duration and the velocity of the reversal increase.<sup>64</sup> Therefore, a holodiastolic reversal is usually a sign of at least moderate aortic regurgitation (Figure 6) and appears to be more specific if recorded from the thoraco-abdominal aorta. The velocity of flow reversal at end-diastole, the velocity time integral of the reversal, and the ratio of reversal to forward velocity time integrals in the descending aorta have all been proposed as semiquantitative indices of AR severity.<sup>64,65</sup> A prominent holodiastolic reversal with a diastolic time integral similar to the systolic time integral is a reliable qualitative sign of severe AR. However, reduced compliance of the aorta seen with advancing age may also prolong the normal diastolic reversal in the absence of significant AR.

**Flow calculations.** Quantitation of flow with pulsed Doppler for the assessment of AR is based on comparison of measurement of aortic stroke volume at the LVOT with mitral or pulmonic stroke vol-

ume.<sup>14,15</sup> Total stroke volume (aortic stroke volume) can also be derived from quantitative 2D measurements of LV end-diastolic and end-systolic volumes. EROA can be calculated from the regurgitant stroke volume and the regurgitant jet velocity time integral by CW Doppler.<sup>15,53</sup> As with the PISA method, a regurgitant volume  $\geq 60$  ml and EROA  $\geq 0.30$  cm<sup>2</sup> are consistent with severe AR. The quantitative Doppler method cannot be used if there is more than mild mitral regurgitation, unless the pulmonic site is used for systemic flow calculation.

**c. Continuous wave Doppler.** *Signal density.* The density of the CW Doppler spectral display of the AR jet reflects the volume of regurgitation, especially in comparison to the antegrade spectral density. However the AR jet density is also determined by the respective directions of initial and distal jet within the beam of ultrasound and also possibly by the ability of the jet to expand and mobilize adjoining red-blood cells. While a faint spectral display is compatible with trace or mild AR, significant overlap between moder-

**Table 6** Application of specific and supportive signs, and quantitative parameters in the grading of aortic regurgitation severity

	Mild	Moderate	Severe	
<b>Specific signs for AR severity</b>	<ul style="list-style-type: none"> <li>• Central Jet, width &lt; 25% of LVOT<sup>‡</sup></li> <li>• Vena contracta &lt; 0.3 cm<sup>‡</sup></li> <li>• No or brief early diastolic flow reversal in descending aorta</li> </ul>	Signs of AR>mild present but no criteria for severe AR	<ul style="list-style-type: none"> <li>• Central Jet, width ≥ 65% of LVOT<sup>‡</sup></li> <li>• Vena contracta &gt; 0.6cm<sup>‡</sup></li> </ul>	
<b>Supportive signs</b>	<ul style="list-style-type: none"> <li>• Pressure half-time &gt; 500 ms</li> <li>• Normal LV size*</li> </ul>	Intermediate values	<ul style="list-style-type: none"> <li>• Pressure half-time &lt; 200 ms</li> <li>• Holodiastolic aortic flow reversal in descending aorta</li> <li>• Moderate or greater LV enlargement**</li> </ul>	
<b>Quantitative parameters<sup>‡</sup></b>				
R Vol, ml/beat	< 30	30-44	45-59	≥ 60
RF, %	< 30	30-39	40-49	≥ 50
EROA, cm <sup>2</sup>	< 0.10	0.10-0.19	0.20-0.29	≥ 0.30

AR, Aortic regurgitation; EROA, effective regurgitant orifice area; LV, left ventricle; LVOT, left ventricular outflow tract; R Vol, regurgitant volume; RF, regurgitant fraction.

\* LV size applied only to chronic lesions. Normal 2D measurements: LV minor-axis ≤ 2.8 cm/m<sup>2</sup>, LV end-diastolic volume ≤ 82 ml/m<sup>2</sup> (2).

<sup>‡</sup> At a Nyquist limit of 50–60 cm/s.

\*\* In the absence of other etiologies of LV dilatation.

<sup>‡</sup> Quantitative parameters can help sub-classify the moderate regurgitation group into mild-to-moderate and moderate-to-severe regurgitation as shown.

ate and severe regurgitation exists in more dense jet recordings. Therefore, CW Doppler jet density is an imperfect indicator of severity of AR.

**Diastolic jet deceleration.** The rate of deceleration of the diastolic regurgitant jet and the derived pressure half-time reflect the rate of equalization of aortic and LV diastolic pressures. With increasing severity of AR, aortic diastolic pressure decreases more rapidly. The late diastolic jet velocity is lower and hence pressure half-time is shorter.<sup>66</sup> Pressure half-time is easily measured if the peak diastolic velocity is appropriately recorded. A pressure half-time > 500 ms is usually compatible with mild AR whereas a value <200 ms is considered consistent with severe AR (Figure 6). However, the diastolic AR velocity is also determined by LV diastolic compliance and pressure. For a given severity of AR, pressure half-time can be further shortened by an elevated LV diastolic pressure or by vasodilator therapy that reduces AR.<sup>66,67</sup> On the other hand, pressure half-time can be lengthened or normalized with chronic LV adaptation to severe AR.<sup>68</sup>

### 3. Role of TEE

Transesophageal echocardiography is seldom needed to evaluate severity of AR due to the proximity of the aortic valve to the chest from the parasternal window. However, TEE may be needed in patients with poor acoustic windows in whom transthoracic echocardiography cannot provide adequate delineation of anatomy or accurate Doppler

recordings. Color Doppler criteria on jet width and the size of the vena contracta apply equally to TEE and may show improved image quality in some patients. However, due to more difficulty with TEE in obtaining views where the jet direction is parallel to the ultrasound beam, measurements of regurgitant fraction by PW Doppler and recording of the AR velocity with CW Doppler are more difficult to obtain reliably. With proper angulation, the magnitude of the proximal flow convergence can be measured. In addition, one can record the diastolic flow reversal in the ascending aorta with PW Doppler from the upper esophageal views, which also show the aortic arch.

### 4. Integrative Approach to Assessment of AR

The assessment of AR by Doppler echocardiography is an integrative and comprehensive process based on all information collected during the examination. The advantages and limitations of the 2D and Doppler parameters in evaluating AR severity are shown in Table 5. In all cases one should routinely perform an evaluation of the aortic valve, LV size and function, an assessment by color flow imaging of the proximal jet width and, if possible, the vena-contracta. The LV outflow velocity and the velocity in the proximal descending aorta and/or abdominal aorta should be recorded by Pulsed Doppler. CW Doppler of the AR jet should also be routinely recorded but only utilized if a complete signal is obtained.

**Table 7** Echocardiographic and Doppler parameters used in the evaluation of tricuspid regurgitation severity: Utility, advantages, and imitations

Parameter	Utility/Advantages	Limitations
RV/RA/IVC size	Enlargement sensitive for chronic significant TR. Normal size virtually excludes significant chronic TR.	Enlargement seen in other conditions. May be normal in acute significant TR
TV leaflet alterations	Flail valve specific for significant TR	Other abnormalities do not imply significant TR
Paradoxical septal motion (volume overload pattern)	Simple sign of severe TR	Not specific for TR
Jet area–Color flow	Simple, quick screen for TR	Subject to technical and hemodynamic factors. Underestimates severity in eccentric jets
Vena contracta width	Simple, quantitative, separates mild from severe TR	Intermediate values require further confirmation
PISA method	Quantitative	Validated in only a few studies
Flow quantitation –PW	Quantitative	Not validated for determining TR regurgitant fraction
Jet profile –CW	Simple, readily available	Qualitative, complementary data
Peak tricuspid E velocity	Simple, usually increased in severe TR	Depends on RA pressure and RV relaxation, TV area, and atrial fibrillation; Complementary data only
Hepatic vein flow	Simple; Systolic flow reversal is sensitive for severe TR	Influenced by RA pressure, atrial fibrillation.

CW, Continuous wave Doppler; EROA, effective orifice regurgitant area; IVC, inferior vena cava; PISA, proximal isovelocity surface area; PW, pulsed wave Doppler; RA, right atrium; RV, right ventricle; TV, tricuspid valve; TR, tricuspid regurgitation.

Based on data in the literature and a consensus of the committee members, the Task Force proposes a scheme of specific signs ( $\geq 90\%$  specificity), along with supportive signs whose predictive accuracy is more modest, and quantitative parameters for AR severity (Table 6). In applying this scheme, it is the consensus of the committee members that the process of grading AR should be comprehensive using a combination of these signs, clues and measurements obtained by Doppler-echocardiography. If the AR is definitely determined as mild or less using these signs, no further measurement is required. If there are parameters suggestive of more than mild AR and the quality of the primary data lends itself to quantitation, it is desirable for echocardiographers with experience in quantitative methods to measure quantitatively the degree of AR, including the regurgitant volume and fraction as descriptors of volume overload and the effective regurgitant orifice as a descriptor of the lesion severity. The wording chosen for expressing the degree of AR, which is a continuum best defined by quantitative measurements, can include qualifiers such as mild-to-moderate to describe the lowest end of the moderate range, moderate-to-severe to describe the upper end of the moderate range. Similar to MR, when the evidence from the different parameters is congruent, it is easy to grade AR severity. When different

parameters are contradictory, one must look carefully for technical and physiologic reasons to explain these discrepancies and rely on the components that have the best quality of the primary data and that are the most accurate considering the underlying clinical condition.

## E. TRICUSPID REGURGITATION

A small degree of tricuspid regurgitation (TR) is present in about 70% of normal individuals.<sup>69-71</sup> Pathologic regurgitation is often due to right ventricular (RV) and tricuspid annular dilation secondary to pulmonary hypertension or RV dysfunction. Primary causes of TR include endocarditis, carcinoid heart disease, Ebstein's anomaly, and rheumatic disease.<sup>72-74</sup>

Evaluation of TR severity has been hampered by the lack of a quantitative standard for severity. Furthermore, in contrast to left sided lesions, surgical intervention for severe TR alone is uncommon. More often, tricuspid annuloplasty is performed as an adjunct to other cardiac surgery when TR is significant. The echocardiographic examination therefore seeks to determine the etiology of regurgitation and provides a semi-quantitative estimate of



severity. The various parameters used in this evaluation are detailed in Table 7. More quantitative measures of TR severity are rarely needed. During the examination, it is important to measure the TR velocity with CW Doppler, which provides an estimation of RV systolic pressure.

### 1. Role of Two-dimensional Echocardiography

Evaluation of the tricuspid valve apparatus with 2D echocardiography is important in determining the etiology of TR. Secondary findings like right atrial and RV enlargement often accompany significant chronic TR. Such an evaluation is usually qualitative. Although enlargement of right-sided chambers is not specific for significant regurgitation, its absence suggests milder degree of TR. Paradoxical ventricular septal motion may occur with the RV volume overload due to severe TR. However, this sign is not specific for TR, as it is affected by many factors.<sup>75-77</sup> Lastly, imaging of the inferior vena cava in the subcostal view for size and respiratory variation provides an evaluation of right atrial pressure.<sup>78-80</sup>

### 2. Doppler Methods

**a. Color flow Doppler.** The simplest approach to evaluate TR severity is color flow imaging in several views to establish the characteristics, direction and the size of the regurgitant jet. Since the RV is situated in the anterior chest, transthoracic images usually are adequate and should include the parasternal RV inflow view, the parasternal short axis view, the apical four-chamber view and the subcostal four-chamber view. As a general rule, jets that extend deep into the right atrium represent more TR than small central jets that appear just superior to the tricuspid leaflets (Figure 7). Overall, color Doppler flow mapping of TR severity using jet area correlates well with angiographic evaluation<sup>81</sup> and clinical measures of regurgitant severity.<sup>82,83</sup> However, there can be considerable overlap of jet areas in patients with mild versus moderate TR.<sup>83</sup> Furthermore, and similar to MR, flow jets that are directed centrally into the right atrium generally appear larger by color Doppler than eccentric, wall-impinging jets with similar or worse severity.

Color flow imaging also may be used to determine TR severity by the PISA method. Visualization of a measurable contour of the flow convergence zone is more challenging than with MR. Quantitation of TR using the PISA method has been validated in small studies but is rarely needed clinically.<sup>81,84</sup> On the other hand, visualization of the vena contracta width is technically less demanding and can be utilized either quantitatively or qualitatively.<sup>82,85,86</sup> A jet width  $> 0.7$  cm identifies severe TR with a sensitivity of 89% and a specificity of 93% and correlates well with EROA.<sup>85,86</sup> Both the PISA and vena con-

tracta methods are more accurate for determining TR severity in central jets compared to eccentric jets, and appear to be more accurate than jet area. However, there can be overlap in values of jet width between mild and moderate TR. Underestimation of severe TR can also occur in 20-30% of patients using jet area or PISA.<sup>81</sup>

**b. Continuous wave Doppler.** Recording of TR jet velocity provides a useful method for noninvasive measurement of RV or pulmonary artery systolic pressure. It is important to note that TR jet velocity, similar to velocity of other regurgitant lesions, is not related to the volume of regurgitant flow. In fact, massive TR is often associated with a low jet velocity ( $< 2$  m/s), as there is near equalization of RV and right atrial pressures (Figure 7). Conversely, mild regurgitation may have a very high jet velocity, when pulmonary hypertension is present.

Similar to MR, the features of the TR jet by CW Doppler that help in evaluating severity of regurgitation, are the signal intensity and the contour of the velocity curve (Figure 7). With severe TR, a dense spectral recording is seen along with a triangular, early peaking of the velocity because of a prominent regurgitant pressure wave. With severe tricuspid regurgitation and normal RV pressures, the antegrade and retrograde CW flow signals across the valve are almost mirror images of each other, corresponding to the "to-and-fro" flow across the severely incompetence valve orifice.<sup>87</sup>

**c. Pulsed Doppler.** The severity of TR will affect the early diastolic tricuspid E velocity, similar to MR. Values above 1.0 m/s are often recorded in patients with severe regurgitation even without valve stenosis. In theory, tricuspid regurgitant volume can be calculated by subtracting the flow across a non-regurgitant valve from the antegrade flow across the tricuspid valve annulus. In contrast to MR and AR, this approach is rarely utilized for TR, partly because of errors in measuring the tricuspid valve annulus.

Similar to the use of pulmonary vein flow pattern in MR, PW Doppler examination of the hepatic veins helps corroborate the assessment of TR severity. With increasing severity of TR, the normally dominant systolic wave is blunted. With severe tricuspid regurgitation, systolic flow reversal occurs (Figure 7). However, hepatic vein flow patterns are also affected by abnormalities in right atrial and RV relaxation and compliance, the phase of the respiratory cycle, preload, and atrial fibrillation.<sup>88</sup> The sensitivity of flow reversal for severe TR is 80%.<sup>83</sup> While the specificity of systolic flow reversal is not well defined, experience has shown that it is also a specific sign of severe TR, provided that the modulating conditions mentioned above are accounted for during interpretation.

**Table 8** Echocardiographic and Doppler parameters used in grading tricuspid regurgitation severity

Parameter	Mild	Moderate	Severe
Tricuspid valve	Usually normal	Normal or abnormal	Abnormal/Flail leaflet/Poor coaptation
RV/RA/IVC size	Normal*	Normal or dilated	Usually dilated**
Jet area-central jets (cm <sup>2</sup> ) <sup>§</sup>	< 5	5-10	> 10
VC width (cm) <sup>¶</sup>	Not defined	Not defined, but < 0.7	> 0.7
PISA radius (cm) <sup>¶</sup>	≤ 0.5	0.6-0.9	> 0.9
Jet density and contour-CW	Soft and parabolic	Dense, variable contour	Dense, triangular with early peaking
Hepatic vein flow†	Systolic dominance	Systolic blunting	Systolic reversal

CW, Continuous wave Doppler; IVC, inferior vena cava; RA, right atrium; RV, right ventricle; VC, vena contracta width.

\* Unless there are other reasons for RA or RV dilation. Normal 2D measurements from the apical 4-chamber view: RV medio-lateral end-diastolic dimension ≤ 4.3 cm, RV end-diastolic area ≤ 35.5 cm<sup>2</sup>, maximal RA medio-lateral and supero-inferior dimensions ≤ 4.6 cm and 4.9 cm respectively, maximal RA volume ≤ 33 ml/m<sup>2</sup>(35;89).

\*\* Exception: acute TR.

§ At a Nyquist limit of 50-60 cm/s. Not valid in eccentric jets. Jet area is not recommended as the sole parameter of TR severity due to its dependence on hemodynamic and technical factors.

¶ At a Nyquist limit of 50-60 cm/s.

¶ Baseline shift with Nyquist limit of 28 cm/s.

† Other conditions may cause systolic blunting (eg. atrial fibrillation, elevated RA pressure).

**Table 9** Echocardiographic and Doppler parameters used in the evaluation of pulmonary regurgitation severity: Utility, advantages, and limitations

Parameter	Utility/Advantages	Disadvantages
RV size	RV enlargement sensitive for chronic significant PR. Normal size virtually excludes significant PR	Enlargement seen in other conditions.
Paradoxical septal motion (volume overload pattern)	Simple sign of severe PR	Not specific for PR
Jet length-Color flow	Simple	Poor correlation with severity of PR
Vena contracta width	Simple quantitative method that works well for other valves	More difficult to perform; requires good images of pulmonary valve; lacks published validation
Jet deceleration rate-CW	Simple	Steep deceleration not specific for severe PR
Flow quantitation-PW	Quantitates regurgitant flow and fraction	Subject to significant errors due to difficulties of measurement of pulmonic annulus and a dynamic RVOT; not well validated

CW, Continuous wave; RV, right ventricle; PR, pulmonic regurgitation; RVOT, right ventricular outflow tract.

### 3. Role of TEE

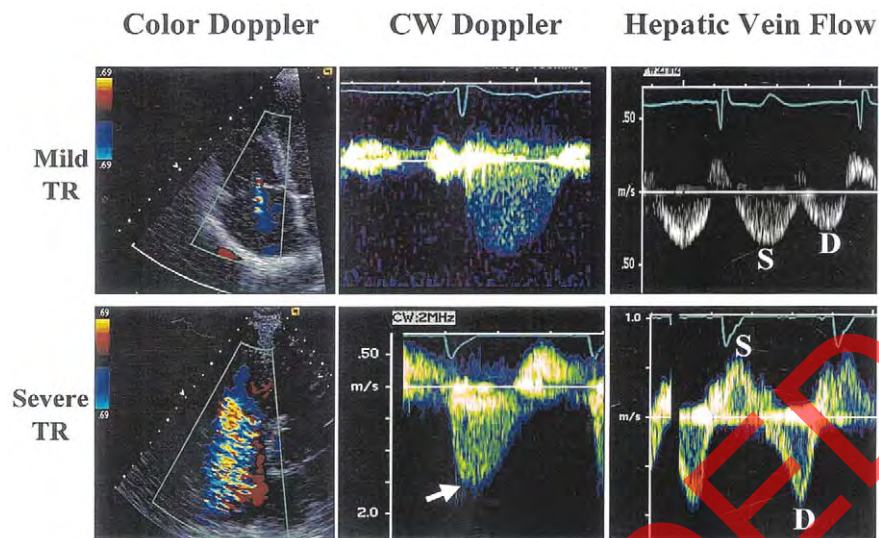
Most often, TR can be adequately evaluated on transthoracic imaging. Even when parasternal and apical views are suboptimal, subcostal views allow color flow mapping, and recording of hepatic vein flow pattern. When transthoracic images are poor, TEE may be helpful. Color flow mapping can be performed using the high esophageal 4-chamber and short axis views as well as the transgastric 4-chamber and RV inflow views. Similar to MR, jet area may appear larger with TEE than with transthoracic imaging.

CW Doppler signals can be recorded from high esophageal or transgastric views. However, obtaining a parallel intercept angle can be problematic. Hepatic vein flow can be recorded by starting in a parasternal long axis view of the right atrium and

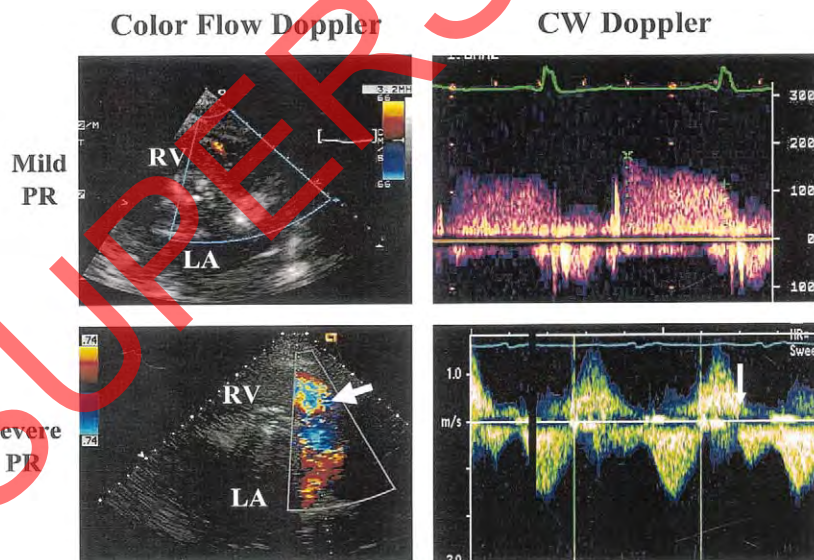
then following the inferior vena cava caudally until the hepatic veins are visualized. The goals of the TEE examination are identical to those of the surface examination so that standard image planes and multiple approaches to evaluation of regurgitant severity should be performed when pathologic tricuspid valve disease is suspected.

### 4. Integrative Approach to Assessment of Tricuspid Regurgitation Severity

Similar to the assessment of other regurgitant lesions, an integrative approach is recommended for evaluation of TR (Table 8). This includes evaluation of the size of right-sided chambers, septal motion and various Doppler parameters. Color Doppler flow mapping in at least 2 orthogonal planes should be performed, with particular attention to the vena



**Figure 7** Examples of jet recordings by color Doppler, continuous wave (CW) Doppler, and hepatic vein flow by pulsed Doppler in a case of mild tricuspid regurgitation (TR) and another with severe TR. The case of mild TR shows a small central color jet with minimal flow convergence in contrast to the severe TR with a very large flow convergence and jet area in the right atrium. CW Doppler recording shows a parabolic spectral display in mild TR whereas in severe TR, early peaking and triangular shape of the velocity is seen (*arrow*). Hepatic vein flow pattern in mild TR is normal whereas in severe TR, hepatic venous flow reversal in systole (*S*) is seen. *D*, Diastolic hepatic venous flow.



**Figure 8** Example of color flow and continuous wave (CW) Doppler recording in a case with mild pulmonary regurgitation (PR) and another with severe PR. In the mild PR, color Doppler shows a small spindle-shaped PR jet in the right ventricular outflow tract. CW recording of the jet shows a slow deceleration of the PR velocity. In the case with severe PR, a large and wide PR jet is seen by color Doppler (*arrow*). Continuous wave Doppler recording shows a steep deceleration of the diastolic PR velocity, with early termination of PR flow (*arrow*). *LA*, Left atrium; *RV*, right ventricle.

contracta, flow convergence and the direction and size of the jet. CW Doppler recording of the TR jet should be recorded to evaluate the signal intensity and contour of the jet, and estimate pulmonary

artery systolic pressure. Moreover, the size of the inferior vena cava and response to respiration as well as hepatic vein flow pattern help evaluate right atrial pressure and adaptation to the volume over-



load. With the lack of extensive data on quantitation of TR, the Task Force recommends integration of information from all available parameters discussed (Table 8). The more congruent the findings are regarding severity, the more confident the diagnosis. Inherent to this process is the particular attention to the quality of the data obtained, and to the physiologic conditions that can alter the accuracy of these parameters as indices of regurgitation severity.

## F. PULMONARY REGURGITATION

Minor degrees of pulmonary regurgitation (PR) have been reported in 40-78% of patients with morphologically normal pulmonary valves and no other evidence of structural heart disease.<sup>90-92</sup> Pathologic regurgitation is infrequent, and should be diagnosed mainly in the presence of significant structural abnormalities of the right heart. In the adult, acquired PR is most often seen in patients with pulmonary hypertension, which is often associated with dilatation of the pulmonary artery, right ventricle, right atrium and hepatic veins. PR in this condition however, is rarely severe. Severe PR is usually observed in patients with anatomic abnormalities of the valve or after valvotomy. Because of the difficulties imaging the pulmonary valve and the low prevalence of severe, life-threatening PR, few validation studies have been conducted. Furthermore, validation of echo/Doppler methods measuring PR is limited by the uncommon use of angiography or other methods to diagnose this condition. Echocardiographic and Doppler parameters that are useful in the evaluation of PR are listed on Table 9.

### 1. Role of Two-dimensional Echocardiography

Evaluation of the RV outflow tract and pulmonary valve by 2D echocardiography is possible from the parasternal and sub-costal views. Identification of anatomic abnormalities associated with PR, such as abnormalities of cusp number (quadricuspid or bicuspid valves), motion (doming or prolapse) or structure (hypoplasia, dysplasia or absence of the pulmonary valve) may help define the mechanism of regurgitation and yield clues to its severity. Visualization of the entire pulmonary valve is more difficult than the mitral, aortic and tricuspid valves. However, dilatation of the pulmonary artery, frequently observed in pulmonary hypertension, allows easier visualization of the valve. Inability to fully visualize the pulmonary valve may limit the quantitation of pulmonary regurgitation. Lastly, evaluation of the size and function of the RV in the absence of pulmonary hypertension provides an indirect indicator to the significance of PR and adaptation of the RV to the volume overload state.

## 2. Doppler Methods

**a. Color flow Doppler.** Color Doppler flow mapping is the most widely used method to identify PR. A diastolic jet in the RV outflow tract, beginning at the line of leaflet coaptation and directed toward the right ventricle is diagnostic of PR (Figure 8). Although color Doppler is ideally suited to determine the jet size and spatial orientation, many of the factors used to evaluate the severity of regurgitation (jet size, extent and duration) will be determined by a combination of the regurgitant volume and the driving pressure (gradient between the pulmonary artery and the RV). Regurgitant jets seen in normal pulmonary valves, considered a variation of normal, are usually very small, 'spindle-shaped' and originate centrally from the pulmonary leaflet coaptation site (Figure 8).<sup>91</sup> Initial studies attempted to quantify pulmonary regurgitation by measuring jet length.<sup>91</sup> Jets < 10 mm in length were trivial while larger jets were associated with heart disease. However, jet length is highly dependent on the driving pressure gradient between the pulmonary artery and the RV, and is therefore not a reliable index of severity. Assessing the entire jet area by planimetry should, theoretically, fare better than the jet length alone. Planimetered jet areas, indexed for body surface area, correlated well with PR severity compared to angiography. However, a high degree of variability and overlap among different grades of regurgitation was observed.<sup>92</sup> In cases of severe pulmonary regurgitation, the full extent of the regurgitant jet may not be appreciated from the parasternal position; sub-costal imaging may be necessary to fully appreciate its full extent.

Although not systematically validated for the pulmonary valve, the vena contracta width is probably a more accurate method to evaluate the severity of PR by color Doppler, similar to other regurgitant lesions. Some investigators have used the PR jet width in the serial assessment of pulmonary homografts, but standards for pulmonary vena contracta width have not been established.<sup>93</sup> It is important to note that in cases of severe PR, where equalization of diastolic pulmonary artery and RV pressures occurs early in diastole, the color jet area can be brief and misleading at first glance. In this case, the large width of the vena contracta and findings by PW and CW Doppler (see below) alert the observer to the severity of regurgitation (Figure 8).

**b. Continuous wave Doppler.** CW Doppler is frequently used to measure the end-diastolic velocity of PR and thus estimate pulmonary artery end-diastolic pressure. However, there is no clinically accepted method of quantifying pulmonary regurgitation using CW Doppler. Similar to AR, the density of the CW signal provides a qualitative measure of regurgitation.<sup>51</sup> A rapid deceleration rate, while consistent

**Table 10** Echocardiographic and Doppler parameters used in grading pulmonary regurgitation severity

Parameter	Mild	Moderate	Severe
Pulmonic valve	Normal	Normal or abnormal	Abnormal
RV size	Normal*	Normal or dilated	Dilated
Jet size by color Doppler <sup>§</sup>	Thin (usually < 10 mm in length) with a narrow origin	Intermediate	Usually large, with a wide origin; May be brief in duration
Jet density and deceleration rate –CW†	Soft; Slow deceleration	Dense; variable deceleration	Dense; steep deceleration, early termination of diastolic flow
Pulmonic systolic flow compared to systemic flow –PW <sup>¶</sup>	Slightly increased	Intermediate	Greatly increased

CW, Continuous wave Doppler; PR, pulmonic regurgitation; PW, pulsed wave Doppler; RA, right atrium; RF, regurgitant fraction; RV, right ventricle.

\* Unless there are other reasons for RV enlargement. Normal 2D measurements from the apical 4-chamber view; RV medio-lateral end-diastolic dimension  $\leq$  4.3 cm, RV end-diastolic area  $\leq$  35.5 cm<sup>2</sup>(89).

\*\* Exception: acute PR

<sup>§</sup> At a Nyquist limit of 50-60 cm/s.

<sup>¶</sup> Cut-off values for regurgitant volume and fraction are not well validated.

† Steep deceleration is not specific for severe PR.

with more severe regurgitation, is influenced by several factors including RV diastolic properties and filling pressures. In severe PR, a rapid equalization of RV and pulmonary artery pressures can occur before the end of diastole. Thus, an intense signal of “to and fro” flow in the shape of a “sine wave”, with termination of flow in mid to late diastole can be seen (Figure 8). This finding however, is not specific for severe PR, as early and rapid equilibration of diastolic pressures is also seen in patients with low pulmonary artery end-diastolic pressure and/or elevated RV diastolic pressure (eg. RV infarction). However the intensity of the PR signal, color Doppler characteristics of the jet and pulmonic flow quantitation in the RV outflow tract by PW Doppler help differentiate these entities.

**c. Pulsed Doppler.** In the evaluation of PR, pulsed Doppler interrogation of velocity can be useful at the level of the pulmonic annulus and in the pulmonary artery.<sup>94,96</sup> If the velocity of the PR jet is not aliased by PW Doppler, its contour and timing can be evaluated similar to CW Doppler (above), with identical implications.<sup>97</sup>

Pulsed Doppler assessment of the forward and reverse flows in the pulmonary artery has been used to calculate regurgitant volume and regurgitant fraction.<sup>95,96</sup> If the diameter of the pulmonary artery is assumed to be constant, then the ratio of the reverse to forward velocity time integral can be used to estimate the percent of regurgitant flow.<sup>95</sup> Although differences in regurgitation fraction were observed among groups with various severity of PR, a considerable overlap was seen and standards for pulmonary artery regurgitant fraction have not been established.<sup>96</sup> Furthermore, this method is not valid in patients with pulmonic stenosis because of post-stenotic turbulent flow.

As previously discussed, pulsed Doppler can be used to calculate stroke volume at different annular sites. The pulmonic annulus however, is probably the most difficult site to measure because of its poor visualization and the changing size of the RV outflow tract during the cardiac cycle. It is recommended to measure the pulmonic annulus during early ejection (2-3 frames after the R wave on the ECG), just below the pulmonic valve.<sup>98,99</sup> Although not validated for quantitation of PR, flows at the pulmonic annulus can be compared to other sites to derive quantitative parameters of regurgitation (regurgitant volume and fraction). Clinically, this is feasible provided that particular attention is taken to image well the area of the pulmonic annulus and thus minimize errors of its measurement.

### 3. Role of TEE

The main pulmonary artery is an anterior structure and is often imaged as well or even better with transthoracic echocardiography compared to the transesophageal approach. The role of TEE is therefore limited in assessing severity of PR.

### 4. Integrative Approach to Assessment of Pulmonary Regurgitation Severity

A comprehensive approach to the evaluation of PR severity is recommended, similar to other valvular regurgitation. Since there is insufficient data on quantitation of PR to recommend a clinically validated quantitative approach, the evaluation is generally qualitative and should include the various parameters discussed above (Table 10). Color Doppler is the best screening modality and accurately identifies trivial and mild pulmonary regurgitation as thin, small jets with a ‘pin-point’ origin. These lesions are readily differenti-

ated from more severe degrees of PR. In addition to color Doppler, an evaluation of the pulmonic valve, RV size and function help elucidate the etiology of the regurgitation and the adaptation to the volume overload. CW Doppler of the PR jet and TR jet, if available, should be routinely recorded to provide supportive evidence for the degree of regurgitation and estimation of pulmonary pressure. Quantitation of the vena contracta by color Doppler and regurgitant fraction with pulsed Doppler, although helpful, need further validation. Despite these limitations, clinically useful qualitative estimates of PR regurgitation are feasible in the majority of cases.

## G. CONCLUSIONS

Echocardiography with Doppler has become the first line approach to the evaluation and management of valvular heart disease. While 2D echocardiography provides an assessment of valvular structure, mechanism of regurgitation and adaptation to the volume overload state, Doppler allows in the same setting, a comprehensive evaluation of the severity of regurgitation using qualitative and quantitative methods from Color flow and spectral Doppler. In general, regurgitation may present a challenge for most diagnostic techniques because of the dynamic nature of lesion and its dependence on various hemodynamic and physiologic conditions. For all valvular regurgitation, an integrative approach of 2D and Doppler parameters is recommended to achieve an accurate evaluation of the severity of the lesion and its clinical significance. This takes into account physiologic conditions that could alter the accuracy of certain parameters, emphasizes the quality of the primary data and allows internal verification of the interpretation.

Echocardiographic evaluation of cardiac adaptation to the volume overload offers, along with careful assessment of symptoms, an ideal tool for management of valvular regurgitation and timing of surgery. With the recent advances in digital echocardiography, comparison of serial images can now be performed readily side-by-side for a more precise assessment of interval change in these adaptive processes and for better timing of surgery. In the near future, with advances in real-time 3D imaging, the spatial distribution of the valve regurgitation will be more readily available, enhancing measurements of flow convergence, vena contracta and the regurgitant jet for improved quantitation of valvular regurgitation.

## REFERENCES

1. Bonow RO, Carabello B, de LA Jr, Edmunds LH Jr, Fedderly BJ, Freed MD, et al. Guidelines for the management of patients with valvular heart disease: executive summary; a report of the American College of Cardiology/American Heart Association Task Force on Practice Guidelines (Committee on Management of Patients with Valvular Heart Disease). *Circulation* 1998;98:1949-84.
2. Schiller NB, Shah PM, Crawford M, DeMaria A, Devereux R, Feigenbaum H, et al. Recommendations for quantitation of the left ventricle by two-dimensional echocardiography: American Society of Echocardiography Committee on Standards, Subcommittee on Quantitation of Two-Dimensional Echocardiograms. *J Am Soc Echocardiogr* 1989;2:358-67.
3. Quinones MA, Otto CM, Stoddard M, Waggoner A, Zoghbi WA. Recommendations for quantification of Doppler echocardiography: a report from the Doppler Quantification Task Force of the Nomenclature and Standards Committee of the American Society of Echocardiography. *J Am Soc Echocardiogr* 2002;15:167-84.
4. Sahn DJ. Instrumentation and physical factors related to visualization of stenotic and regurgitant jets by Doppler color flow mapping. *J Am Coll Cardiol* 1988;12:1354-65.
5. Baumgartner H, Schima H, Kuhn P. Value and limitations of proximal jet dimensions for the quantitation of valvular regurgitation: an in vitro study using Doppler flow imaging. *J Am Soc Echocardiogr* 1991;4:57-66.
6. Kizilbash AM, Willett DL, Brickner ME, Heinle SK, Grayburn PA. Effects of afterload reduction on vena contracta width in mitral regurgitation. *J Am Coll Cardiol* 1998;32:427-31.
7. Bargiggia GS, Tronconi L, Sahn DJ, Recusani F, Raisaro A, De Servi S, et al. A new method for quantitation of mitral regurgitation based on color flow Doppler imaging of flow convergence proximal to regurgitant orifice. *Circulation* 1991;84:1481-9.
8. Utsunomiya T, Doshi R, Patel D, Mehta K, Nguyen D, Henry WL, et al. Calculation of volume flow rate by the proximal isovelocity surface area method: simplified approach using color Doppler zero baseline shift. *J Am Coll Cardiol* 1993;22:277-82.
9. Pu M, Vandervoort PM, Griffin BP, Leung DY, Stewart WJ, Cosgrove DM 3rd, et al. Quantification of mitral regurgitation by the proximal convergence method using transesophageal echocardiography: clinical validation of a geometric correction for proximal flow constraint. *Circulation* 1995;92:2169-77.
10. Simpson IA, Shiota T, Gharib M, Sahn DJ. Current status of flow convergence for clinical applications: is it a leaning tower of "PISA"? *J Am Coll Cardiol* 1996;27:504-9.
11. Sitges M, Jones M, Shiota T, Prior DL, Qin JX, Tsujino H, et al. Interaliasing distance of the flow convergence surface for determining mitral regurgitant volume: a validation study in a chronic animal model. *J Am Coll Cardiol* 2001;38:1195-202.
12. Schwammenthal E, Chen C, Benning F, Block M, Breithardt G, Levine RA. Dynamics of mitral regurgitant flow and orifice area: physiologic application of the proximal flow convergence method; clinical data and experimental testing. *Circulation* 1994;90:307-22.
13. Lewis JF, Kuo LC, Nelson JG, Limacher MC, Quiñones MA. Pulsed Doppler echocardiographic determination of stroke volume and cardiac output: clinical validation of two new methods using the apical window. *Circulation* 1984;70:425-31.
14. Rokey R, Sterling LL, Zoghbi WA, Sartori MP, Limacher MC, Kuo LC, et al. Determination of regurgitant fraction in isolated mitral or aortic regurgitation by pulsed Doppler two-

- dimensional echocardiography. *J Am Coll Cardiol* 1986;7:1273-8.
15. Enriquez-Sarano M, Bailey KR, Seward JB, Tajik AJ, Krohn MJ, Mays JM. Quantitative Doppler assessment of valvular regurgitation. *Circulation* 1993;87:841-8.
  16. Hundley WG, Kizilbash AM, Afridi I, Franco F, Peshock RM, Grayburn PA. Administration of an intravenous perfluorocarbon contrast agent improves echocardiographic determination of left ventricular volumes and ejection fraction: comparison with cine magnetic resonance imaging. *J Am Coll Cardiol* 1998;32:1426-32.
  17. Thomson HL, Basmadjian AJ, Rainbird AJ, Razavi M, Avierinos JF, Pellikka PA, et al. Contrast echocardiography improves the accuracy and reproducibility of left ventricular remodeling measurements: a prospective, randomly assigned, blinded study. *J Am Coll Cardiol* 2001;38:867-75.
  18. Smith MD, Cassidy JM, Gurley JC, Smith AC, Booth DC. Echo Doppler evaluation of patients with acute mitral regurgitation: superiority of transesophageal echocardiography with color flow imaging. *Am Heart J* 1995;129:967-74.
  19. Khoury AF, Afridi I, Quiñones MA, Zoghbi WA. Transesophageal echocardiography in critically ill patients: feasibility, safety, and impact on management. *Am Heart J* 1994;127:1363-71.
  20. Cape EG, Yoganathan AP, Levine RA. Increased heart rate can cause underestimation of regurgitant jet size by Doppler color flow mapping. *J Am Coll Cardiol* 1993;21:1029-37.
  21. Thomas JD, Liu CM, Flachskampf FA, O'Shea JP, Davidoff R, Weyman AE. Quantification of jet flow by momentum analysis: an in vitro color Doppler flow study. *Circulation* 1990;81:247-59.
  22. Cape EG, Skoufis EG, Weyman AE, Yoganathan AP, Levine RA. A new method for noninvasive quantification of valvular regurgitation based on conservation of momentum: in vitro validation. *Circulation* 1989;79:1343-53.
  23. Oh JK, Seward JB, Khandheria BK, Gersh BJ, McGregor CGA, Freeman WK, et al. Transesophageal echocardiography in critically ill patients. *Am J Cardiol* 1990;66:1492-5.
  24. Honey M, Gough SH, Katsaros S, Miller GAH, Thuringham V. Left ventricular cine-angiography in the assessment of mitral regurgitation. *Br Heart J* 1969;31:596-602.
  25. Baron MG. Angiocardiographic evaluation of valvular insufficiency. *Circulation* 1971;43:599-605.
  26. Sandler H, Dodge HT, Hay RE, Rackley CE. Quantification of valvular insufficiency in man by angiocardiography. *Am Heart J* 1963;65:501-13.
  27. Lopez JF, Hanson S, Orchard RC, Tan L. Quantification of mitral valvular incompetence. *Cathet Cardiovasc Diagn* 1985; 11:139-52.
  28. Hunt D, Baxley WA, Kennedy JW, Judge TP, Williams JE, Dodge HT. Quantitative evaluation of cineangiography in the assessment of aortic regurgitation. *Am J Cardiol* 1973;31: 696-700.
  29. Stewart WJ, Currie PJ, Salcedo EE, Lytle BW, Gill CC, Schiavone WA, et al. Intraoperative Doppler color flow mapping for decision-making in valve repair for mitral regurgitation: technique and results in 100 patients. *Circulation* 1990; 81:556-66.
  30. Stewart WJ, Salcedo EE, Cosgrove DM. The value of echocardiography in mitral valve repair. *Cleve Clin J Med* 1991; 58:177-83.
  31. Otsuji Y, Handschumacher MD, Schwammenthal E, Jiang L, Song J, Guerrero JL, et al. Insights from three-dimensional echocardiography into the mechanism of functional mitral regurgitation: direct in vivo demonstration of altered leaflet tethering geometry. *Circulation* 1997;96:1999-2008.
  32. Carabello BA, Crawford FA Jr. Valvular heart disease. *N Engl J Med* 1997;337:32-41.
  33. Echocardiographic measurements and normal values. In: Feigenbaum H, editor. *Echocardiography*. Philadelphia: Lea & Febiger; 1994. p. 658-83.
  34. Lester SJ, Ryan EW, Schiller NB, Foster E. Best method in clinical practice and in research studies to determine left atrial size. *Am J Cardiol* 1999;84:829-32.
  35. Wang Y, Gutman JM, Heilbron D, Wahr D, Schiller NB. Atrial volume in a normal adult population by two-dimensional echocardiography. *Chest* 1984;86:595-601.
  36. Yoshida K, Yoshikawa J, Shakudo M, Akasaka T, Jyo Y, Takao S, et al. Color Doppler evaluation of valvular regurgitation in normal subjects. *Circulation* 1988;78:840-7.
  37. Helmcke F, Nanda NC, Hsiung MC, Soto B, Adey CK, Goyal RG, et al. Color Doppler assessment of mitral regurgitation with orthogonal planes. *Circulation* 1987;75:175-83.
  38. Cape EG, Yoganathan AP, Weyman AE, Levine RA. Adjacent solid boundaries alter the size of regurgitant jets on Doppler color flow maps. *J Am Coll Cardiol* 1991;17:1094-102.
  39. Chen C, Thomas JD, Anconina J, Harrigan P, Mueller L, Picard MH, et al. Impact of impinging wall jet on color Doppler quantification of mitral regurgitation. *Circulation* 1991;84:712-20.
  40. Enriquez-Sarano M, Tajik AJ, Bailey KR, Seward JB. Color flow imaging compared with quantitative Doppler assessment of severity of mitral regurgitation: influence of eccentricity of jet and mechanism of regurgitation. *J Am Coll Cardiol* 1993; 21:1211-29.
  41. Fehske W, Omran H, Manz M, Kohler J, Hagendorff A, Luderitz B. Color-coded Doppler imaging of the vena contracta as a basis for quantification of pure mitral regurgitation. *Am J Cardiol* 1994;73:268-74.
  42. Hall SA, Brickner ME, Willett DL, Irani WN, Afridi I, Grayburn PA. Assessment of mitral regurgitation severity by Doppler color flow mapping of the vena contracta. *Circulation* 1997;95:636-42.
  43. Heine SK, Hall SA, Brickner ME, Willett DL, Grayburn PA. Comparison of vena contracta width by multiplane transesophageal echocardiography with quantitative Doppler assessment of mitral regurgitation. *Am J Cardiol* 1998;81: 175-9.
  44. Tribouilloy C, Shen WF, Quere JP, Rey JL, Choquet D, Dufosse H, et al. Assessment of severity of mitral regurgitation by measuring regurgitant jet width at its origin with transesophageal Doppler color flow imaging. *Circulation* 1992;85: 1248-53.
  45. Mele D, Vandervoort P, Palacios I, Rivera JM, Dinsmore RE, Schwammenthal E, et al. Proximal jet size by Doppler color flow mapping predicts severity of mitral regurgitation: clinical studies. *Circulation* 1995;91:746-54.
  46. Enriquez-Sarano M, Miller FA Jr, Hayes SN, Bailey KR, Tajik AJ, Seward JB. Effective mitral regurgitant orifice area: clinical use and pitfalls of the proximal isovelocity surface area method. *J Am Coll Cardiol* 1995;25:703-9.
  47. Pu M, Prior DL, Fan X, Asher CR, Vasquez C, Griffin BP, et al. Calculation of mitral regurgitant orifice area with use of a simplified proximal convergence method: initial clinical application. *J Am Soc Echocardiogr* 2001;14:180-5.
  48. Hopmeyer J, He S, Thorvig KM, McNeil E, Wilkerson PW, Levine RA, et al. Estimation of mitral regurgitation with a



- hemielliptic curve-fitting algorithm: in vitro experiments with native mitral valves. *J Am Soc Echocardiogr* 1998;11:322-31.
49. Schwammenthal E, Chen C, Giesler M, Sagie A, Guerrero JL, Vazquez de Prada JA, et al. New method for accurate calculation of regurgitant flow rate based on analysis of Doppler color flow maps of the proximal flow field: validation in a canine model of mitral regurgitation with initial application in patients. *J Am Coll Cardiol* 1996;27:161-72.
  50. Mele D, Schwammenthal E, Torp H, Nesta F, Pedini I, Vandervoort P, et al. A semiautomated objective technique for applying the proximal isovelocity surface area method to quantitate mitral regurgitation: clinical studies with the digital flow map. *Am Heart J* 2001;141:653-60.
  51. Buck T, Mucci RA, Guerrero JL, Holmvang G, Handschumacher MD, Levine RA. The power-velocity integral at the vena contracta: a new method for direct quantification of regurgitant volume flow. *Circulation* 2000;102:1053-61.
  52. Thomas L, Foster E, Schiller NB. Peak mitral inflow velocity predicts mitral regurgitation severity. *J Am Coll Cardiol* 1998;31:174-9.
  53. Enriquez-Sarano M, Seward JB, Bailey KR, Tajik AJ. Effective regurgitant orifice area: a noninvasive Doppler development of an old hemodynamic concept. *J Am Coll Cardiol* 1994;23:443-51.
  54. Dujardin KS, Enriquez-Sarano M, Bailey KR, Nishimura RA, Seward JB, Tajik AJ. Grading of mitral regurgitation by quantitative Doppler echocardiography: calibration by left ventricular angiography in routine clinical practice. *Circulation* 1997;96:3409-15.
  55. Kizilbash AM, Hundley WG, Willett DL, Franco F, Peshock RM, Grayburn PA. Comparison of quantitative Doppler with magnetic resonance imaging for assessment of the severity of mitral regurgitation. *Am J Cardiol* 1998;81:792-5.
  56. Pu M, Griffin BP, Vandervoort PM, Stewart WJ, Fan X, Cosgrove DM, et al. The value of assessing pulmonary venous flow velocity for predicting severity of mitral regurgitation: a quantitative assessment integrating left ventricular function. *J Am Soc Echocardiogr* 1999;12:736-43.
  57. Thomas L, Foster E, Hoffman JJ, Schiller NB. The mitral regurgitation index: an echocardiographic guide to severity. *J Am Coll Cardiol* 1999;33:2016-22.
  58. Grayburn PA, Smith MD, Handshoe R, Friedman BJ, DeMaria AN. Detection of aortic insufficiency by standard echocardiography, pulsed Doppler echocardiography, and auscultation: a comparison of accuracies. *Ann Intern Med* 1986;104:599-605.
  59. Perry GJ, Helmcke F, Nanda NC, Byard C, Soto B. Evaluation of aortic insufficiency by Doppler color flow mapping. *J Am Coll Cardiol* 1987;9:952-9.
  60. Reynolds T, Abate J, Tenney A, Warner MG. The JH/LVOH method in the quantification of aortic regurgitation: how the cardiac sonographer may avoid an important potential pitfall. *J Am Soc Echocardiogr* 1991;4:105-8.
  61. Tribouilloy CM, Enriquez-Sarano M, Bailey KR, Seward JB, Tajik AJ. Assessment of severity of aortic regurgitation using the width of the vena contracta: a clinical color Doppler imaging study. *Circulation* 2000;102:558-64.
  62. Taylor AL, Eichhorn EJ, Brickner ME, Eberhart RC, Grayburn PA. Aortic valve morphology: an important in vitro determinant of proximal regurgitant jet width by Doppler color flow mapping. *J Am Coll Cardiol* 1990;16:405-12.
  63. Tribouilloy CM, Enriquez-Sarano M, Fett SL, Bailey KR, Seward JB, Tajik AJ. Application of the proximal flow convergence method to calculate the effective regurgitant orifice area in aortic regurgitation. *J Am Coll Cardiol* 1998;32:1032-9.
  64. Touche T, Prasquier R, Nitenberg A, de Zuttere D, Gourgon R. Assessment and follow-up of patients with aortic regurgitation by an updated Doppler echocardiographic measurement of the regurgitant fraction in the aortic arch. *Circulation* 1985;72:819-24.
  65. Tribouilloy C, Avinec P, Shen WF, Rey JL, Slama M, Lesbre JP. End diastolic flow velocity just beneath the aortic isthmus assessed by pulsed Doppler echocardiography: a new predictor of the aortic regurgitant fraction. *Br Heart J* 1991;65:37-40.
  66. Teague SM, Heinsimer JA, Anderson JL, Sublett K, Olson EG, Voyles WF, et al. Quantification of aortic regurgitation utilizing continuous wave Doppler ultrasound. *J Am Coll Cardiol* 1986;8:592-9.
  67. Padiyal LR, Oliver A, Vivaldi M, Sagie A, Freitas N, Weyman AE, et al. Doppler echocardiographic assessment of progression of aortic regurgitation. *Am J Cardiol* 1997;80:306-14.
  68. Griffin BP, Flachskampf FA, Siu S, Weyman AE, Thomas JD. The effects of regurgitant orifice size, chamber compliance, and systemic vascular resistance on aortic regurgitant velocity slope and pressure half-time. *Am Heart J* 1991;122:1049-56.
  69. Singh JP, Evans JC, Levy D, Larson MG, Freed LA, Fuller DL, et al. Prevalence and clinical determinants of mitral, tricuspid, and aortic regurgitation (the Framingham Heart Study). *Am J Cardiol* 1999;83:897-902.
  70. Lavie CJ, Hebert K, Cassidy M. Prevalence and severity of Doppler-detected valvular regurgitation and estimation of right-sided cardiac pressures in patients with normal two-dimensional echocardiograms. *Chest* 1993;103:226-31.
  71. Klein AL, Burstow DJ, Tajik AJ, Zachariah PK, Taliencio CP, Taylor CL, et al. Age-related prevalence of valvular regurgitation in normal subjects: a comprehensive color flow examination of 118 volunteers. *J Am Soc Echocardiogr* 1990;3:54-63.
  72. Hansing CE, Rowe GG. Tricuspid insufficiency: a study of hemodynamics and pathogenesis. *Circulation* 1972;45:793-9.
  73. Cohen SR, Sell JE, McIntosh CL, Clark RE. Tricuspid regurgitation in patients with acquired, chronic, pure mitral regurgitation: II, nonoperative management, tricuspid valve annuloplasty, and tricuspid valve replacement. *J Thorac Cardiovasc Surg* 1987;94:488-97.
  74. Waller BF, Howard J, Fess S. Pathology of tricuspid valve stenosis and pure tricuspid regurgitation—part III. *Clin Cardiol* 1995;18:225-30.
  75. Veyrat C, Kalmanson D, Farjon M, Manin JP, Abitbol G. Non-invasive diagnosis and assessment of tricuspid regurgitation and stenosis using one and two dimensional echo-pulsed Doppler. *Br Heart J* 1982;47:596-605.
  76. Miyatake K, Okamoto M, Kinoshita N, Ohta M, Kozuka T, Sakakibara H, et al. Evaluation of tricuspid regurgitation by pulsed Doppler and two dimensional echocardiography. *Circulation* 1982;66:777-84.
  77. DePace NL, Ross J, Iskandrian AS, Nestico PF, Kotler MN, Mintz GS, et al. Tricuspid regurgitation: noninvasive techniques for determining causes and severity. *J Am Coll Cardiol* 1984;3:1540-50.
  78. Sakai K, Nakamura K, Satomi G, Kondo M, Hirosawa K. Hepatic vein blood flow pattern measured by Doppler echocardiography as an evaluation of tricuspid valve insufficiency. *J Cardiol* 1983;13:33-43.
  79. Simonson JS, Schiller NB. Sonospirometry: a non-invasive method for estimation of mean right atrial pressure based on two dimensional echocardiographic measurements of the in-

- ferior vena cava during measured inspiration. *J Am Coll Cardiol* 1988;11:557-64.
80. Abu-Yousef MM. Duplex Doppler sonography of the hepatic vein in tricuspid regurgitation. *AJR Am J Roentgenol* 1991; 156:79-83.
  81. Grossmann G, Stein M, Kochs M, Hoher M, Koenig W, Hombach V, et al. Comparison of the proximal flow convergence method and the jet area method for the assessment of the severity of tricuspid regurgitation. *Eur Heart J* 1998;19: 652-9.
  82. Shapira Y, Porter A, Wurzel M, Vaturi M, Sagie A. Evaluation of tricuspid regurgitation severity: echocardiographic and clinical correlation. *J Am Soc Echocardiogr* 1998;11:652-9.
  83. Gonzalez-Vilchez F, Zarauza J, Vazquez de Prada JA, Martin DR, Ruano J, Delgado C, et al. Assessment of tricuspid regurgitation by Doppler color flow imaging: angiographic correlation. *Int J Cardiol* 1994;44:275-83.
  84. Yamachika S, Reid CL, Savani D, Meckel C, Paynter J, Knoll M, et al. Usefulness of color Doppler proximal isovelocity surface area method in quantitating valvular regurgitation. *J Am Soc Echocardiogr* 1997;10:159-68.
  85. Rivera JM, Vandervoort P, Mele D, Weyman A, Thomas JD. Value of proximal regurgitant jet size in tricuspid regurgitation. *Am Heart J* 1996;131:742-7.
  86. Tribouilloy CM, Enriquez-Sarano M, Bailey KR, Tajik AJ, Seward JB. Quantification of tricuspid regurgitation by measuring the width of the vena contracta with Doppler color flow imaging: a clinical study. *J Am Coll Cardiol* 2000;36:472-8.
  87. Minagoe S, Rahimtoola SH, Chandraratna PA. Significance of laminar systolic regurgitant flow in patients with tricuspid regurgitation: a combined pulsed-wave, continuous-wave Doppler and two-dimensional echocardiographic study. *Am Heart J* 1990;119:627-35.
  88. Nagueh SF, Kopelen HA, Zoghbi WA. Relation of mean right atrial pressure to echocardiographic and Doppler parameters of right atrial and right ventricular function. *Circulation* 1996; 93:1160-9.
  89. Normal cross-sectional echocardiographic measurements. In: Weyman A, editor. *Principles and practice of echocardiography*. Philadelphia: Lea & Febiger; 1994. p. 1289-98.
  90. Choong CY, Abascal VM, Weyman J, Levine RA, Gentile F, Thomas JD, et al. Prevalence of valvular regurgitation by Doppler echocardiography in patients with structurally normal hearts by two-dimensional echocardiography. *Am Heart J* 1989;117:636-42.
  91. Takao S, Miyatake K, Izumi S, Okamoto M, Kinoshita N, Nakagawa H, et al. Clinical implications of pulmonary regurgitation in healthy individuals: detection by cross sectional pulsed Doppler echocardiography. *Br Heart J* 1988;59:542-50.
  92. Kobayashi J, Nakano S, Matsuda H, Arisawa J, Kawashima Y. Quantitative evaluation of pulmonary regurgitation after repair of tetralogy of Fallot using real-time flow imaging system. *Jpn Circ J* 1989;53:721-7.
  93. Tweddell JS, Pelech AN, Frommelt PC, Mussatto KA, Wyman JD, Fedderly RT, et al. Factors affecting longevity of homograft valves used in right ventricular outflow tract reconstruction for congenital heart disease. *Circulation* 2000;102: III130-5.
  94. Waggoner AD, Quinones MA, Young JB, Brandon TA, Shah AA, Verani MS, et al. Pulsed Doppler echocardiographic detection of right-sided valve regurgitation: experimental results and clinical significance. *Am J Cardiol* 1981;47:279-86.
  95. Goldberg SJ, Allen HD. Quantitative assessment by Doppler echocardiography of pulmonary or aortic regurgitation. *Am J Cardiol* 1985;56:131-5.
  96. Marx GR, Hicks RW, Allen HD, Goldberg SJ. Noninvasive assessment of hemodynamic responses to exercise in pulmonary regurgitation after operations to correct pulmonary outflow obstruction. *Am J Cardiol* 1988;61:595-601.
  97. Lei MH, Chen JJ, Ko YL, Cheng JJ, Kuan P, Lien WP. Reappraisal of quantitative evaluation of pulmonary regurgitation and estimation of pulmonary artery pressure by continuous wave Doppler echocardiography. *Cardiology* 1995;86: 249-56.
  98. Zoghbi WA, Farmer KL, Soto JG, Nelson JG, Quiñones MA. Accurate noninvasive quantification of stenotic aortic valve area by Doppler echocardiography. *Circulation* 1986;73:452-9.
  99. Nakatani S, Masuyama T, Kodama K, Kitabatake A, Fujii K, Kamada T. Value and limitations of Doppler echocardiography in the quantification of stenotic mitral valve area: comparison of the pressure half-time and the continuity equation methods. *Circulation* 1988;77:78-85.