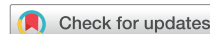

American Society of Echocardiography COVID-19 Statement Update: Lessons Learned and Preparation for Future Pandemics



James N. Kirkpatrick, MD, FASE (Chair), Madhav Swaminathan, MD, FASE (Co-Chair), Adeyinka Adedipe, MD, Enrique Garcia-Sayan, MD, FASE, Judy Hung, MD, FASE, Noreen Kelly, MD, FASE, Smadar Kort, MD, FASE, Sherif Nagueh, MD, FASE, Kian Keong Poh, MD, FASE, Aarti Sarwal, MD, G. Monet Strachan, ACS, RDCS, FASE, Yan Topilsky, MD, Cathy West, MSc, AMS, FASE, and David H. Wiener, MD, FASE, *Seattle, Washington; Durham, Charlotte, and Winston-Salem, North Carolina; Houston, Texas; Boston, Massachusetts; Stony Brook, New York; Singapore; San Francisco, California; Tel-Aviv, Israel; London, United Kingdom; and Philadelphia, Pennsylvania*

The COVID-19 pandemic has evolved since the publication of the initial American Society of Echocardiography (ASE) statements providing guidance to echocardiography laboratories. In light of new developments, the ASE convened a diverse, expert writing group to address the current state of the COVID-19 pandemic and to apply lessons learned to echocardiography laboratory operations in future pandemics. This statement addresses important areas specifically impacted by the current and future pandemics: (1) indications for echocardiography, (2) application of echocardiographic services in a pandemic, (3) infection/transmission mitigation strategies, (4) role of cardiac point-of-care ultrasound/critical care echocardiography, and (5) training in echocardiography. (J Am Soc Echocardiogr 2023;36:1127-39.)

Keywords: Echocardiography, COVID-19, Triage, POCUS, Imaging, Training

INTRODUCTION

SARS CoV-2, the infectious agent responsible for COVID-19, has altered the medical landscape and spurred dramatic changes in the practice of echocardiography. In 2020, the American Society of Echocardiography (ASE) released a statement¹ with the primary goal of providing guidance to echocardiography laboratories responding to what would become a worldwide pandemic. The ASE subsequently

produced 4 supplemental/companion statements addressing pediatric, fetal, and congenital heart disease echocardiography,² perioperative/periprocedural transesophageal echocardiography (TEE),³ sonographer safety,⁴ and cardiac point-of-care ultrasound (POCUS).⁵ Later in 2020, the ASE published a statement on the reintroduction of echocardiography services during the COVID-19 pandemic.⁶

Since the publication of these statements, the pandemic has evolved. Vaccine mandates are standard in medical centers, and

From the University of Washington, Seattle, Washington (J.N.K., A.A.); Duke University School of Medicine, Durham, North Carolina (M.S.); Baylor College of Medicine, Houston, Texas (E.G.S.); Massachusetts General Hospital, Boston, Massachusetts (J.H.); Sanger Heart Institute, Charlotte, North Carolina (N.K.); Stony Brook University Medical Center, Stony Brook, New York (S.K.); Houston Methodist Hospital, Houston, Texas (S.N.); Department of Cardiology, National University of Singapore, Singapore (K.K.P.); Wake Forest Baptist Health Center, Winston-Salem, North Carolina (A.S.); Division of Cardiology, University of California, San Francisco, California (G.M.S.); Tel-Aviv Sourasky Medical Center, Tel-Aviv, Israel (Y.T.); Royal Brompton Hospital, London, United Kingdom (C.W.); and Jefferson Heart Institute, Thomas Jefferson University Hospital, Philadelphia, Pennsylvania (D.H.W.).

The following authors reported no actual or potential conflicts of interest in relation to this document: James N. Kirkpatrick, MD, FASE, Enrique Garcia-Sayan, MD, FASE, Judy Hung, MD, FASE, Smadar Kort, MD, FASE, Sherif Nagueh, MD, FASE, Kian Keong Poh, MD, FASE, Aarti Sarwal, MD, David H. Wiener, MD, FASE.

The following authors reported relationships with one or more commercial interests: Dr. Madhav Swaminathan participated on the Alexion, Inc. advisory board regarding clinical trial design for acute kidney injury; Dr. Adeyinka Adedipe participates as PI for a study of a New Point-of-Care-US System in ED patients, partly funded by Philips Healthcare, Inc.; Dr. Noreen Kelly has participated in the

Speakers Bureau for Abbott Laboratories; Yan Topilsky has participated as consultant to Edwards Lifesciences, Abbott Laboratories, and Venus Medtech; Ms. Cathy West participated in Adult Congenital Heart Disease, MedMastery courses.

Reprint requests: American Society of Echocardiography, Meridian Corporate Center, 2530 Meridian Parkway, Suite 450, Durham, NC 27713 (E-mail: ase@asecho.org).






Attention ASE Members:

Login at www.ASELearningHub.org to earn continuing medical education credit through an online activity related to this article. Certificates are available for immediate access upon successful completion of the activity and post-work. This activity is free for ASE Members, and \$40 for nonmembers.

0894-7317/\$36.00

Copyright 2023 Published by Elsevier Inc. on behalf of the American Society of Echocardiography.

<https://doi.org/10.1016/j.echo.2023.08.020>

	Conventional	Contingency	Crisis
 Indications	<ul style="list-style-type: none"> • AUC 	<ul style="list-style-type: none"> • Defer non-urgent 	<ul style="list-style-type: none"> • Only emergent, likely to survive
 Transmission control	<ul style="list-style-type: none"> • Standard 	<ul style="list-style-type: none"> • Limited protocol • No ECG 	<ul style="list-style-type: none"> • Very limited protocol, or • POCUS* only
 POCUS/CCE	<ul style="list-style-type: none"> • Standard 	<ul style="list-style-type: none"> • Use to triage full exam • Remote guidance 	<ul style="list-style-type: none"> • POCUS* only • Decision without imaging
 Alternative imaging	<ul style="list-style-type: none"> • Standard 	<ul style="list-style-type: none"> • CT/CMR/nuclear in place of TEE 	<ul style="list-style-type: none"> • Decision without imaging
 Training	<ul style="list-style-type: none"> • Standard/hybrid 	<ul style="list-style-type: none"> • Remote as default • Simulators 	<ul style="list-style-type: none"> • Remote only

*POCUS /CCE performed by treating team with simple machines to reduce number of individuals exposed and exposure duration and safeguard limited sonographer resources.

Central Illustration Practice applications in pandemic standards of care. *AUC*, Appropriate Use Criteria; *ECG*, Electrocardiogram; *POCUS*, Point of Care Ultrasound; *CCE*, Critical Care Echocardiography; *CT*, Computed Tomography; *CMR*, Cardiac Magnetic Resonance Imaging; *TEE*, Transesophageal Echocardiogram.

mask mandates have been relaxed in many settings. The availability of viral testing became widespread and then waned in the community, along with disease prevalence, and requirements for preprocedure testing were relaxed. Antiviral therapies are currently widely available. The emergence of delta, omicron, and other COVID-19 variants introduced a cyclical nature to the pandemic, compounded by the “triple-demic” of influenza, respiratory syncytial virus, and COVID-19 in the winter of 2022/2023. Concurrently, echocardiography laboratories faced sonographer and nursing shortages. Work absences due to illness exacerbated staffing problems. Furthermore, extensive research has emerged with new data on transmission risk, reinfection, acquired immunity, clinical operations, and the impact of COVID-19 on cardiovascular disease.

Considering these developments, the ASE convened a diverse, expert writing group to provide additional guidance to echocardiography laboratories. This guidance is intended to address the current state of the COVID-19 pandemic and to apply lessons learned to echocardiography laboratory operations in future pandemics.⁷

The writing group extensively discussed the issue of local/regional variability in policy and practice. This statement acknowledges these differences but also recognizes the role of professional societies in guiding the development of local policies in conversations between echocardiography laboratory directors and administrators, infection control experts, and staff.

This statement is divided into sections corresponding to important areas specifically impacted by the current and future pandemics: (1) indications for echocardiography, (2) application of echocardiographic services in a pandemic, (3) transmission and mitigation strategies, (4) role of cardiac POCUS/critical care echocardiography (CCE), and (5) training in echocardiography.

In making recommendations for preparedness in future pandemics, the writing group opted to follow a well-established disaster-response planning model: conventional, contingency, and

crisis standards of care and preparedness⁸ (Central Illustration). Conventional care standards are the “business as usual” high standards that form the basis of echocardiographic performance when resources are not limited or are not more limited than usual by external threats. Contingency care standards anticipate shortages and find ways to conserve resources or to substitute with alternative techniques, without relaxing usual standards. For example, during the height of the pandemic, echocardiography laboratories did not place electrocardiogram (ECG) electrodes when scanning patients with COVID-19, using timed acquisitions instead to attempt to reduce risk of transmission by limiting physical contact and extra equipment brought into isolation rooms. Crisis standards accept that resources are insufficient to maintain usual standards of care and, in many instances, necessitate difficult choices, including denying scarce resources to patients unlikely to survive. During the pandemic, although crisis standards were not declared by governmental agencies, many echocardiography laboratories deferred or even canceled nonurgent studies due to transmission risk and staff shortages. Most of the guidance in this statement applies to contingency standards of care.

It is important to keep in mind that while this document refers to the COVID-19 pandemic with respect to disease-specific management, recommendations for echocardiography services may be applicable broadly in any future situation where there is a threat of morbidity and mortality from a highly contagious pathogen.

INDICATIONS FOR ECHOCARDIOGRAPHY

Indications for echocardiography during a pandemic center on the clinical utility, which, in turn, is based on echocardiographic findings and how they impact clinical management. Future pandemics caused by respiratory viruses with systemic effects are likely to manifest many

Abbreviations

ASE = American Society of Echocardiography
CCE = Critical care echocardiography
CDC = Centers for Disease Control and Prevention
CT = Computed tomography
CXR = Chest x-ray
ECG = Electrocardiogram
GLS = Global longitudinal strain
LV = Left ventricular
LVEF = Left ventricular ejection fraction
PACS = Picture archiving and communication system
POCUS = Point-of-care ultrasound
PPE = Personal protective equipment
RV = Right ventricular
TEE = Transesophageal echocardiography
TTE = Transthoracic echocardiogram
UEA = Ultrasound-enhancing agent

of the right-sided echocardiographic findings seen in COVID-19 infection. They may also affect cardiovascular function through direct toxicity and/or worsen preexisting cardiovascular conditions.

Echocardiographic Findings in Acute COVID-19 Infection

Over the course of the pandemic, the cardiovascular consequences of acute COVID-19 infection became apparent. Patients with preexisting cardiovascular conditions are not only at higher risk for complications from COVID-19 infection, but they are also susceptible to developing de novo cardiovascular disease as a consequence.⁹ Echocardiography is one of the first-line imaging modalities used in the evaluation of patients with COVID-19 who have suspected cardiovascular complications. In one study, approximately half of patients evaluated with a transthoracic echocardiogram (TTE) had an abnormality, and in almost a third of cases the identification of these abnormalities led to a change in management.¹⁰ The

identification of echocardiographic abnormalities, such as left ventricular (LV) or right ventricular (RV) systolic dysfunction, also has important prognostic value.¹¹ In one study approximately 30% of patients who had an echocardiographic abnormality and abnormal biomarkers died during their hospitalization.¹²

Left Ventricular Dysfunction. One of the most common indications for echocardiography in patients with COVID-19 infection is suspected left-sided heart failure or LV systolic dysfunction. The incidence of LV systolic dysfunction in patients with COVID-19 infection varies between studies and may be confounded by the fact that some patients may have had preexisting LV systolic dysfunction that placed them at increased risk for symptomatic COVID-19 infection.^{10,13,14} A reduced LV ejection fraction (LVEF) has been shown to be associated with increased inpatient mortality in patients with COVID-19.¹⁵ Echocardiography is critical to determining the severity and potential causes of LV systolic dysfunction. For example, the presence of a coronary distribution regional wall motion abnormality in a patient presenting with chest pain, abnormal cardiac biomarkers, and/or ischemic ECG changes should raise suspicion for an acute coronary syndrome causing the LV systolic dysfunction. Stress (takotsubo) cardiomyopathy is a known cause of LV systolic dysfunction in patients with COVID-19 infection and may be suspected in patients who have the classic echocardiographic finding of preserved basal systolic func-

tion but hypokinesis, akinesis, or dyskinesis of the midapical myocardium.¹⁶ Other important causes of LV systolic dysfunction in patients with acute COVID-19 infection are myocarditis and multisystem inflammatory syndrome.¹⁷ Multisystem inflammatory syndrome can occur in adults or children and often presents as LV systolic dysfunction in association with systemic signs and symptoms such as elevated inflammatory markers, fever, shock, and gastrointestinal symptoms.¹⁸

Studies reported LV diastolic dysfunction in patients with acute COVID-19 infection.¹³ Since many of the risk factors for severe COVID-19 infection overlap with risk factors for diastolic dysfunction (namely, advanced age, hypertension, diabetes, obesity, and coronary artery disease), the exact incidence of diastolic dysfunction attributable solely to COVID-19 is difficult to determine. Additionally, the mechanism by which COVID-19 causes diastolic dysfunction in the absence of systolic dysfunction is unclear but may be related to generalized myocardial injury, microvascular dysfunction, small vessel vasculitis, or endotheliitis, which have been observed with COVID-19 infection.¹⁹

Right Ventricular Systolic Dysfunction. The incidence of RV dilation and systolic dysfunction in acute COVID-19 infection appears to equal or exceed the incidence of LV systolic dysfunction.^{10,13} There are numerous potential mechanisms by which COVID-19 infection can cause RV dilation and systolic dysfunction. While many of the processes that cause LV systolic dysfunction can also cause RV systolic dysfunction, including myocardial ischemia, myocarditis, and stress cardiomyopathy, RV systolic dysfunction may also result from acute pulmonary hypertension or acute cor pulmonale.²⁰ The most common causes of acute cor pulmonale in COVID-19 infection are acute respiratory distress syndrome, pneumonia, and pulmonary thromboembolism.²¹⁻²³ Echocardiography is the noninvasive test of choice to determine the severity of pulmonary hypertension and provides clues to the etiology of elevated pulmonary pressures.²⁴

Pericardial Effusion. Pericardial effusions leading to tamponade have been reported in patients with acute COVID-19 infection; however, this appears to be uncommon.¹⁰

Lung Imaging. Lung ultrasound has emerged as a rapid, reliable point-of-care imaging modality for the diagnosis of pulmonary pathology in patients with COVID-19 infection, particularly in the setting of significant limitations in current radiographic imaging technologies. Ground-glass opacification, linear opacities, and consolidation are the major chest x-ray (CXR) findings in patients with COVID-19; however, these findings are not specific.²⁵ Furthermore, a large proportion of patients with polymerase chain reaction–confirmed disease will have a normal CXR, particularly in the early stages of the disease.²⁵ Chest computed tomography (CT) has also played a central role in the early diagnosis and management of patients with COVID-19. Initial findings include bilateral multilobe ground-glass opacification with a peripheral or posterior distribution.²⁶ Chest CT can also aid in the identification of associated pathologies such as vasculopathy or pulmonary thromboembolism. As with CXR, because the CT findings in COVID-19 infection can overlap with other diagnoses including influenza, organizing pneumonia, and pulmonary edema, it is not recommended as a sole diagnostic technique.²⁷

Normal ultrasonic evaluation of the lung demonstrates smooth, regular, contiguous pleural lines, the presence of lung sliding, and A-line artifacts that occur at multiples of the distance between the transducer and the pleural line.²⁸ The identification of an abnormal

number and distribution of B lines—hyperechoic vertical artifacts arising from the pleural line extending the full depth of the image—is suggestive of a thickened pulmonary interstitium and is sensitive for pulmonary edema (either cardiogenic or noncardiogenic).²⁹ Lung ultrasound findings that suggest COVID-19 pneumonia include thickened, irregular, fragmented pleural lines, heterogeneous B-line clusters, subpleural consolidations, and reduced lung sliding.³⁰ A bilateral A pattern, on the other hand, has a high negative predictive value for pneumonia and may be useful in excluding COVID-19 pneumonia.³¹ A recent systematic review supports the role of lung ultrasound in the care of COVID-19 patients, showing that lung ultrasound changed the diagnosis in approximately 30% of patients and altered management in approximately 45% of patients.³²

Echocardiographic Findings in Postvaccine Myocarditis

Myocarditis and pericarditis are rare adverse events following the administration of COVID-19 mRNA vaccines. According to the US Centers for Disease Control and Prevention (CDC), the incidence is estimated at approximately 12.6 cases per million doses of the second dose of the mRNA vaccine given to individuals ages 12 to 39 years.³³ Vaccine-associated myocarditis appears most likely to occur in males 16 to 18 years old within 3 days of the second dose of the mRNA vaccine.³³ Cardiac imaging, alongside clinical examination, electrocardiography, and laboratory testing, forms part of the standard evaluation of patients with suspected myocarditis.

Echocardiographic findings in myocarditis may include reduced or normal ejection fraction, increased wall thickness secondary to interstitial edema, mild regional variation in wall motion, diastolic dysfunction, RV systolic dysfunction, pericardial effusion, and abnormal global LV global longitudinal strain (GLS).^{34,35}

There have been reports of patients presenting in the early post-vaccination period with the clinical spectrum of myocarditis, including chest pain, elevated biomarkers, and abnormal ECG, who had normal echocardiograms but abnormal cardiac magnetic resonance imaging with late gadolinium enhancement indicating myocardial edema.³⁶ As such, echocardiography can assess for the findings described above and evaluate for other causes of chest pain, but it cannot be used to exclude myocarditis. Fortunately, most cases of vaccine-associated myocarditis have a mild clinical course with rapid resolution of symptoms, and most studies suggest that the benefits of vaccination outweigh the risks.³⁷

Echocardiographic Findings in Long COVID Syndromes

Many patients around the world have recovered from COVID-19, and many of them have reported persistence of symptoms suggesting potential cardiac involvement such as dyspnea, chest pain, and palpitations.³⁸ As the number of symptomatic patients after acute infection increased, the terms “long COVID” (symptoms persisting ≥ 4 weeks after acute infection), and “post-COVID syndrome” (≥ 12 weeks) were introduced. In a cohort including $\geq 45,000$ consecutive hospitalized patients with COVID-19 infection from the National Health Service in England, the risk of major adverse cardiovascular events was approximately threefold higher than in a matched cohort,³⁹ even after mild disease.⁴⁰ Early magnetic resonance imaging–based studies describe the persistence of subtle cardiac injury after recovery.⁴⁰⁻⁴² However, these studies lacked baseline imaging and comparison to controls. Several longitudinal echocardiographic analyses assessed the prevalence of post-COVID myocardial injury.

In the World Alliance Societies of Echocardiography COVID study, patients enrolled with acute COVID-19 infection were asked to return for a follow-up TTE. On average, LVEF was not significantly different from baseline. However, patients with hyperdynamic LV systolic function at baseline had a significant reduction of LVEF at follow-up, while patients with reduced LVEF at baseline ($< 50\%$) and those with normal LVEF had no change. Patients with normal or increased LV GLS at baseline had a significant reduction of LV GLS at follow-up, while patients with impaired LV GLS at baseline had a significant improvement at follow-up. Patients with abnormal RV GLS or significant basal RV dilatation at baseline had significant improvement at follow-up. These results suggested that overall, there were no significant changes over time in the LV systolic function, while improvement in RV systolic function was seen in patients recovering from COVID-19 infection. However, differences were observed according to baseline LV and RV systolic function, reflecting recovery from the acute myocardial injury in those with impaired baseline function and normalization of function in those with hyperdynamic LV systolic function.⁴³

Another study evaluating patients with post-COVID syndrome using cardiopulmonary exercise testing combined with stress echocardiography showed that abnormally low peak oxygen consumption was common 3 months after recovery. This finding was rarely due to LV or RV systolic dysfunction but rather from a combination of attenuated stroke volume reserve and chronotropic incompetence.⁴⁴ Finally, in a more recent large prospective study in India, findings after 3-month follow-up showed a significant decrease in LV systolic and diastolic function, when parameters were presented as continuous values or as categorical cutoffs. Surprisingly, and in marked difference to the previously mentioned studies, there was a significant decrease in RV functional parameters when presented as continuous values, albeit RV deterioration was less remarkable when addressing conventional cutoff values. Patients with moderate to severe disease were more prone to long-term LV and RV deterioration.⁴⁵

In summary, although all studies show that clinically meaningful decreases in LV or RV systolic function to the abnormal range are rare, longitudinal echocardiographic studies show discrepant results, possibly due to differences between the cohorts (hospitalized vs ambulatory patients, mild vs severe acute disease), in short-term follow-up. Future work should elucidate whether these changes are permanent or reversible with longer follow-up.

Key Points

- Echocardiography in acute COVID-19 infection should assess LV and RV systolic function, pericardial effusion, and lung imaging (particularly in the setting of an unremarkable CXR when no CT scan has been performed).
- Echocardiography to evaluate suspected myocarditis from COVID-19 or postvaccination should assess LV and RV systolic function, wall thickness, diastolic function, GLS, and pericardial thickness and effusion with imaging for constriction as clinically indicated.
- Echocardiography in patients with long COVID syndromes requires further study.

APPLICATION OF ECHOCARDIOGRAPHY SERVICES IN A PANDEMIC

At the height of the COVID-19 pandemic, many diagnostic tests were canceled or delayed, in attempts to protect the echocardiography

laboratory staff and other patients from the spread of COVID-19. As the rate of transmission has decreased and preventive as well as therapeutic measures are now available, we have entered a different phase of the pandemic and returned to conventional standards of care. Keeping in mind that some level of COVID-19 is likely to remain a risk, new variants may emerge, and future pandemics are likely, a new paradigm shift should take place in our approach to ensuring that echocardiography services are able to adapt to changing conditions.

Decisions about performance of echocardiographic studies should incorporate benefit and risk assessment for the patient, as well as risk for the staff, within the overall context of conventional, contingency, or crisis standards of care. The writing committee encourages echocardiography laboratories to consider all the mitigating and protecting measures that are outlined in this document to lower the risk of transmission to patients and staff and thereby preserve access to patients that would benefit from testing, in terms of both defining the impact of COVID-19 on cardiac function and providing imaging services to patients with other forms of cardiovascular disease.

Staff members familiar with appropriate use criteria⁴⁶⁻⁴⁹ as well as the potential for benefit and risk for patients and staff⁵⁰ should make decisions concerning the performance of echocardiograms. Although there are no appropriate use criteria that specifically address indications for imaging in COVID-19, criteria can be extrapolated from existing documents and what is known about cardiopulmonary involvement (Table 1). Even appropriate requests should be deferred under certain circumstances (e.g., until a patient is no longer in quarantine).

In addition, the complexity and potential risk associated with the test (aerosolizing TEE and exercise stress echocardiography vs non-aerosolizing dobutamine stress echocardiogram and TTE) as well as the local prevalence of COVID-19 or future pandemic diseases with airborne transmission should impact decisions. In crisis standards of care, in which resources do not exist even to provide appropriate echocardiographic services to patients who would benefit, it may be necessary also to consider the trajectory of the patient and the role that imaging may play in clarifying prognosis. Each facility should develop screening and triaging protocols based on the nature of the test, the risk of disease transmission, available resources, standards of care, and availability of clinician-performed cardiac ultrasound and/or alternative imaging modalities (see the sections entitled “Point-of-Care Ultrasound and Critical Care Echocardiography” and “Unique/Alternative Imaging Modalities” below). These protocols should be reassessed and modified as the prevalence of COVID-19 in the community changes. In the Supplemental Appendices, this document includes examples of triage protocols from medical centers in 3 geographically distinct regions (Thomas Jefferson University in Philadelphia, PA; the University of Texas in Houston, TX; and the University of Washington in Seattle, WA). The first 2 were developed early in the pandemic (March and April of 2020), and the third constitutes a revision implemented later in the pandemic (January 2021).

Echocardiography laboratories should avoid denying an appropriate echocardiogram solely based on a patient’s COVID status. If the test is appropriate, it should be performed in a manner that would minimize the risk of exposure without compromising management or delaying therapeutic interventions (unless in crisis standards of care). To accommodate all requests for TTEs on patients with COVID-19 in a timely fashion, echocardiography laboratories may choose to perform them at the bedside to minimize exposure of additional staff and patients (e.g., performing TEEs at the bedside or in the operating

room instead of the echocardiography laboratory) or set aside a specific room for patients who have tested positive.

Inpatient echocardiography laboratories are required to have benchmarks for timeliness of performance and interpretation of studies based on the acuity of the patient and the indication (tamponade, mechanical complications post–myocardial infarction, etc.) as part of the accreditation process. *The patient’s COVID status should not affect these benchmarks.* Ready availability of equipment and supplies ensures rapid performance in accordance with infection/transmission mitigation strategies.

Key Points

- Each facility should develop screening and triaging protocols based on the appropriateness of the indication, the nature of the test, the risk of COVID-19 transmission, and available alternative imaging modalities.
- Decisions about performance of echocardiograms should incorporate benefit and risk assessment for the patient, as well as risk for the staff.
- All efforts should be made to avoid denying an appropriate echocardiogram solely based on the COVID status of the patient.
- The COVID status of the patient should not affect benchmarks for timeliness of performance and interpretation of studies.
- This approach may be adopted in any situation that involves a new infectious pathogen, especially those that are associated with airborne transmission.

INFECTION/TRANSMISSION MITIGATION STRATEGIES

Personal Protective Equipment

Local and institutional standards for the prevention of virus spread should guide performance of echocardiograms. Hand washing and/or alcohol disinfection play crucial roles. The level of personal protective equipment (PPE) required may depend on the COVID-19 risk level of individual patients. The types of PPE can be divided into levels or categories: Standard care involves hand washing or hand sanitization and use of gloves, with possible use of a surgical face mask. Droplet precautions include gown, gloves, head cover, face mask, and eye shield. Airborne precautions add special masks (e.g., N-95 or N-99 respirator masks, powered air-purifying respirator systems) and, in some situations, shoe covers. The local application of each component of PPE can vary according to the level or type of risk for TTE and stress echocardiography; however, airborne precautions are required during TEE for suspected and confirmed cases because of the increased risk for aerosolization with an unprotected airway.

Although mask mandates in conventional standard of care are in flux, it is advisable for symptomatic patients and the sonographers scanning them during TTE to wear masks. Some institutions encourage masking for all patients and staff, including those who are asymptomatic, especially in centers that care for patients who are immunocompromised. Again, local institutional policy and resources will dictate the type of PPE. The CDC in the United States and equivalent regulators in other countries will provide updated guidelines for PPE use for health care workers.

Vaccines

Vaccination is one of the most effective medical countermeasures for mitigating a pandemic and its devastating effects. The rapid transmission and severe health impact of the SARS-CoV-2 virus on a large portion of the exposed populations required developing a safe and effective vaccine in the shortest time possible for easy distribution to the community.⁵¹⁻⁵³

Table 1 Appropriate use criteria applied to imaging in the setting of highly transmissible infectious agents

Related indication(s)	Appropriate	May be appropriate
Acute presentation		
Respiratory failure or hypoxemia of uncertain etiology	TTE	TEE,* CT
Respiratory failure or hypoxemia and noncardiac etiology has been established		TTE
Exertional dyspnea or hypoxemia when noncardiac etiology established	TTE	
Suspected pulmonary HTN (RV and PA pressures)	TTE	CMR, CT
Hemodynamic instability	TTE	TEE,* CT, ANG
Volume status in critically ill patient	TTE	
Suspected acute mitral or aortic regurgitation	TTE	TEE*
Known or suspected HF for etiology (initial)	TTE, SE, [†] MPI, CMR	TEE, strain, CT, ANG, RVG
Suspected acquired cardiomyopathy	TTE, CMR	Strain, F-18 FDG, PYP, CT, RVG
Suspected pericardial disease	TTE	TEE,* strain
Initial evaluation of cardiac source of embolus	TTE, TEE* [‡]	CMR, CT
New LBBB or NSVT	TTE	SE, [†] strain, MPI, CMR
Cardiac syncope/presyncope	TTE	
Syncope/presyncope without other signs/symptoms of cardiac disease	TTE [§]	SE, [†] MPI (syncope)
New RBBB		TTE
Frequent PVC only	TTE	CMR
VT	TTE, ANG	SE, [†] strain, MPI, CMR, CT, RVG
SVT only		TTE, consider POCUS/CCE first
Atrial fibrillation/atrial flutter	TTE	SE, [†] MPI
Sequential or follow-up		
Reevaluation of known pulmonary HTN with change in clinical status or exam, to guide therapy	TTE	TEE,* CMR, CT
Reevaluation (<1 year) of known moderate or greater pulmonary HTN without change in clinical status or exam		TTE
Reevaluation (≥1 year) of known moderate or greater pulmonary HTN without change in clinical status or exam	TTE	
Reevaluation of known HF with change in clinical status or exam without clear precipitating factor	TTE	SE, [†] strain, MPI, CMR, CT, ANG, RVG
Reevaluation of known HF with change in clinical status or exam with clear precipitating factor		TTE
Reevaluation of known cardiomyopathy with change in clinical status or exam to guide therapy	TTE	Strain, CMR, CT, RVG
Reevaluation of pericardial effusion progression (new or worsening symptoms or to guide therapy)	TTE	TEE,* CMR, CT
Reevaluation for progression of pericardial constriction (new or worsening symptoms or to guide therapy)	TTE, CMR, CT	TEE*
Reevaluation of chronic asymptomatic pericardial effusion when findings would alter therapy	TTE	CMR

ANG, Angiography; CMR, cardiovascular magnetic resonance imaging; FDG, fluorodeoxyglucose; HF, heart failure; HTN, hypertension; LBBB, left bundle branch block; MPI, myocardial perfusion imaging (including single-photon emission CT and positron emission tomography); NSVT, nonsustained ventricular tachycardia; PA, pulmonary artery; PVC, premature ventricular complex; PYP, pyrophosphate; RBBB, right bundle branch block; RVG, radionuclide ventriculography; SE, stress echocardiography, comprising exercise stress echocardiography and dobutamine stress echocardiography; SVT, supraventricular tachycardia; VT, ventricular tachycardia.

All nonechocardiographic modalities involve transportation through hospital (not at bedside). Consider POCUS/CCE before TTE.

*Aerosolation concern.

[†]Aerosolation concern with exercise stress echo but not dobutamine stress echo.

[‡]When a cardiac source is strongly suspected and other modalities are not diagnostic.

[§]Transthoracic echocardiography was considered a IIa indication in "2017 ACC/AHA/HRS Guideline for the Evaluation and Management of Patients With Syncope"⁸⁷ only when cardiac etiology was suspected.

Vaccinating against COVID-19 infection altered the trajectory of the pandemic, allowing for many activities to resume. As new variants became prevalent around the world, the CDC recommended boosters due to a rise in breakthrough cases. Further mutations of SARS-CoV-2 virus led to the development of a bivalent booster.⁵⁴ Complex interactions between COVID-19 and endemic respiratory viruses, along with waxing and waning herd immunity that may be related to behavioral changes, will influence the impact of future pandemics on vulnerable populations and constitute another argument in favor of acquired immunity through vaccination.⁵⁵

Decisions about mandating vaccines and reassigning staff with religious or medical exemptions to vaccination depend on local institutional policies.

Limited, Focused Studies

Echocardiographers are at high risk of transmission due to the manual nature of the technique, which requires sustained proximity to the patient (Table 2). To reduce exposure time and therefore transmission, it is advisable to perform a limited study with images specifically targeted at answering the clinical question. For de novo cases, imaging should address the most common expected findings. Importing the ECG from the patient's telemetry system where possible or using time-based acquisitions may reduce contact. In settings where a comprehensive study is required, off-line analysis is recommended, with no measurements performed at the time of the acquisition.⁴

Ultrasound-enhancing agents (UEAs) have been shown to improve the diagnostic ability of portable studies performed in an intensive care unit and should therefore be considered for use in COVID-19 patients who receive portable scanning. Ready availability of UEA as soon as the need arises optimizes scanning time. Additionally, focused scanning protocols are appropriate to evaluate very specific indications such as respiratory decompensation or elevated biomarkers. Training sonographers in such protocols can minimize scanning time while still ensuring all the required information is obtained.^{4,56}

Unique/Alternative Imaging Modalities

During the early days of the COVID-19 pandemic, there was a significant reduction in TEE studies performed due to the risk of aerosol generation during the procedures. Similarly, the potential risk of viral transmission from deep breathing or coughing during exercise limited the use of exercise stress echocardiography.⁵⁷ This led to an increase in alternative imaging modalities that could provide diagnostic information similar to that provided by TEE and stress echocardiography without the risk of aerosol generation. Although multimodality imaging was already an integral part of patient care in many situations, institutions developed novel imaging protocols and strategies. While these imaging modalities may be considered acceptable alternatives to echocardiography in the long term, there are still many situations in which TEE or stress echocardiography is the modality of choice. In these cases, the benefits may outweigh the risks of tests performed with the appropriate use of PPE. Scanning a patient with a highly transmissible infection may lead to decommissioning of a scanning room for a period (depending on disinfection protocols), and transporting such a patient through the hospital, rather than performing a bedside echocardiogram, may risk broader exposure. Dobutamine stress echocardiogram may provide the least exposure risk of any stress

test modality, as it is not considered aerosol generating and can be performed at the bedside (Table 3).

Key Points

- The type of PPE applied in specific cases will depend on local institutional policy and resources.
- Vaccination is one of the most effective medical countermeasures for mitigating a pandemic and its devastating effects. COVID-19 and seasonal flu vaccines help reduce the severity of illness with infection and lower the likelihood of spreading viruses to vulnerable populations.
- Exemptions and decisions regarding assignment of unvaccinated staff will depend on local institutional policies.
- Nonpharmacological and behavioral changes that slowed the spread of COVID-19 also impacted the spread of endemic respiratory viruses.
- A limited study should be performed, with images specifically targeted at answering the clinical question and, for de novo cases, addressing the most common expected findings.
- The ECG should be imported from the patient's telemetry system where possible or by using time-based acquisitions.
- Measurements should not be performed at the time of the acquisition.
- UEAs should be readily available, as needed.
- Multimodality imaging may be considered an acceptable alternative to TEE and exercise stress echocardiography in certain circumstances.
- Transporting patients through the hospital, rather than performing a bedside echocardiogram test, may risk broader exposure.
- Dobutamine stress echocardiogram may provide the least exposure risk of any stress test modality.

POINT-OF-CARE ULTRASOUND AND CRITICAL CARE ECHOCARDIOGRAPHY

Although there are many terms and definitions in use, for the purpose of this statement, the following will broadly describe POCUS and CCE. Cardiac POCUS involves the use of ultrasound at a patient's bedside with acquisition, interpretation, and immediate clinical integration of images typically performed by the treating clinician.^{58,59} Cardiac POCUS is performed by intensivists, emergency physicians, hospitalists, and others, usually to answer specific questions based on the patient's presentation. Critical care echocardiography involves the application of bedside ultrasound to address clinical questions in the critical care environment and may include the use of Doppler echocardiography and other quantitative and semiquantitative measures not typically performed in POCUS. Both cardiac POCUS and CCE may employ lung ultrasound and other ultrasound components not standard in many echocardiography labs.

An important use of cardiac POCUS is to triage the need for ancillary testing. During the early phases of the COVID-19 pandemic, multiple institutions incorporated cardiac POCUS into echocardiography laboratory protocols in a multidisciplinary approach to hemodynamic and diagnostic assessment of patients.⁶⁰ Specific protocols employed screening cardiac and chest POCUS exams as first-line imaging to guide the need for further imaging and limit exposure to as few individuals as possible.⁵ Cardiac POCUS in the emergency department could at a minimum allow CCE and full-feature echocardiograms to be more focused. For example, POCUS/CCE was used to identify early lung changes associated with COVID-19 infection, progression of disease, and important cardiac complications such as LV or RV failure and thus efficiently guide evaluation and management. That said, the point is not to shift the burden of exposure to infectious agents from echocardiography laboratory personnel to POCUS/CCE users. For example, if

Table 2 Recommendations for avoiding pathogen transmission during echocardiography

1. For inpatients, examination should be performed at the bedside, and for outpatients, a dedicated room should be used to avoid crossover with more vulnerable patients.
2. PPE as dictated by local protocols is required.
3. Physical barriers between sonographer and patient may be advised.
4. Handheld devices may further mitigate infection risk due to their smaller size, making them easier to clean.
5. Echocardiographers should take steps to minimize patient contact time, which may include importing the ECG from the patient's telemetry system when possible or using time-based acquisitions.
6. It is advisable to perform a limited study with images specifically targeted at answering the clinical question and for de novo cases, addressing the most common expected findings.
7. Offline measurement analysis is encouraged in this setting to further reduce patient contact time.
8. To save time, UEAs should be prepared and brought into the room if there is an anticipated need.
9. Appropriate postprocedural disinfection of equipment is required.

full-feature TTE is clearly indicated for a patient with COVID-19, requiring POCUS by a bedside clinician may unnecessarily add exposure time to that individual. However, in crisis standard or severe contingency standard situations, cardiac POCUS/CCE may be the only modality available for some patients due to resource (e.g., echocardiography lab staff) limitations. Among patients with an indication for comprehensive echocardiography, triaging may involve difficult decisions about who receives no imaging, cardiac POCUS/CCE imaging only, or full-feature imaging ([Central Illustration](#)).

In future pandemics, cardiac POCUS/CCE will again play a role, perhaps one more important than during the height of the COVID-19 pandemic. A few institutions with preexisting, robust collaboration between cardiac POCUS/CCE users and echocardiography labs were able to rapidly leverage the advantages of POCUS/CCE, while others faced significant barriers. Requirements included an adequate number of POCUS/CCE machines, picture archiving and communication systems (PACSs) that allow uploading of images and the ability of echocardiography laboratory personnel to view the images, adequately trained clinicians, and overall integration into a system of cardiac imaging. These elements should be put in place, if possible, ahead of future pandemics, especially as they may enhance efficiency and coordination of clinical care for patients with and without COVID-19. Decisions about machine purchases and PACSs integration are dependent on local factors. Prior ASE COVID-19 statements discuss some of the pertinent features of integration.¹

Training/Competency Standards

A major limitation in the adoption of cardiac POCUS/CCE is the variability in training and proficiency of operators. Several medical societies have released evidence-based guidelines for ultrasound education, credentialing, and competence, including a minimum number of required examinations.⁶¹⁻⁶³ Notably, recent advances enable handheld POCUS/CCE devices to include automation, facilitating more advanced measurements to augment basic views.⁶⁴ Machine learning has the potential to bend the learning curve and increase both accuracy and efficiency, while reducing variability,⁶⁵ and may reduce the amount of exposure time needed to obtain images from an infected patient. In addition to developing and promulgating clear standards for training and credentialing, a multidisciplinary body that includes representatives from a diverse group of POCUS/CCE experts should be involved in hospital-level decisions to optimize POCUS/CCE integration into clinical care.

Integration

With widespread POCUS/CCE adoption, it is important that improvements in workflow processes take priority across the health system. Ideally, cardiac POCUS/CCE exams should be formally interpreted, documented, and archived in the medical record. The cardiac POCUS/CCE workflow should ensure that exams are available for all health care providers in the health enterprise to view should the need arise, as dictated by changes in the patient's clinical status. Appropriately archived and documented exams are important for compliance with regulatory bodies and are crucial for optimal patient care.^{66,67}

Key Points

- Cardiac and chest POCUS may guide the need for further imaging and limit exposure to as few individuals as possible.
- If cardiac POCUS or CCE answers the clinical question, it is usually not necessary to perform a confirmatory formal echocardiogram.
- Routine cardiac POCUS/CCE application is *not* meant to shift the burden of exposure to infectious agents from echocardiography laboratory personnel to POCUS/CCE users but rather to facilitate best use of resources. Cardiac POCUS should not be performed when CCE or comprehensive echocardiography is clearly indicated.
- An adequate number of POCUS/CCE machines, PACSs that allow uploading of images and the ability of echocardiography laboratory personnel to view the images, adequately trained clinicians, and overall integration into a system of cardiac imaging should be implemented ahead of future pandemics.
- In addition to having clear standards for training and credentialing, a multidisciplinary body that includes representatives from a diverse group of POCUS/CCE experts should be involved in hospital-level decisions to optimize POCUS/CCE integration into clinical care.
- Cardiac POCUS/CCE exams should be formally interpreted, documented, and archived in the medical record.

TRAINING IN ECHOCARDIOGRAPHY

Scanning

Face-to-face, hands-on learner-instructor and learner-patient interactions are the core means of echocardiography training. Competence-based requirements for sonographers describe a minimum and optimal number of cases combining hands-on scans, including measurements, with preliminary interpretation and additional case review. Number of months of training and number of scans performed are indicators of sufficient clinical exposure.⁶⁸ Similarly, the principle of competence-based medical education is the foundation for physician training statements.^{69,70} However, competence cannot be ensured by case or time requirements.

Modern conceptions of competence-based medical education involve outcomes-based evaluation systems using multiple tools, with program directors having the ultimate responsibility for evaluation of a trainee's competence.

Complementary pathways to acquire and evaluate initial competency, as well as demonstrate continuing competency, can be crucial during times of elevated risk and can supplement and inform training during times of average risk. Sonography training programs have had to adapt to the changing clinical environment during the COVID-19 pandemic. When limiting exposure became an overriding priority, sonography students were excluded from many learner-patient interactions. With in-person clinical rotations and hands-on training reduced or restricted during the pandemic and cyclical surges, programs have had to find alternative methods for learning and gaining practical experience.

Alternative pathways for training include

- Remote case review with online educational resources such as the ASE Learning Hub
- Hands-on scanning with remote supervision and feedback
- Increased use of clinical simulators

Simulators have become a particularly attractive solution, since they have become more sophisticated and enhance learning with

feedback, repetitive practice, curriculum integration, and clinical variation.⁷¹

Considering the risk of future pandemics, sonography schools and clinician training programs should continue to explore hybrid learning models, which involve a mix of in-person, simulator-based, and online instruction that can rapidly adapt to variations in pandemic severity, vaccine availability, and social distancing requirements. Asynchronous online instruction and simulators would play particularly crucial roles in crisis standards of care, with trainers in short supply because of the need for all qualified individuals to perform clinical duties.

A second approach has been to extend the amount of time allowed to acquire the requisite number of cases when crisis years provide fewer opportunities. Typical metrics such as time and volume may be impossible to meet for many learners. Some certifying boards have responded accordingly. The American Board of Internal Medicine, for example, allows candidates for board certification to continue to amass cases after the end of fellowship until October 31 of the year in which they test.⁷² The National Board of Echocardiography put in place COVID-19 temporary requirements for candidates whose ability to meet the requisite number of cases in 2020 and 2021 was affected by the pandemic. Candidates are permitted to meet the annual case average in 2 of the 4 years

Table 3 Alternative imaging modalities for specific indications

Indication	Modality	Advantages and disadvantages
LAA	CT	Expertise in CT image acquisition and interpretation, especially delayed phase imaging, is essential to optimizing the positive predictive value of CT for detecting LAA thrombus. ⁷⁶
Valvular heart disease: <ul style="list-style-type: none"> • Planning transcatheter valve implantation procedures • Evaluation of prosthetic valve dysfunction • Evaluation of endocarditis 	CT	Due to the lower temporal resolution of CT compared to TEE, small, highly mobile vegetations may be missed. ⁷⁷ Evaluation of right-sided valves is more technically challenging.
<ul style="list-style-type: none"> • Quantification of valvular regurgitation • Quantification of chamber size and systolic function 	CMR	Role in excluding valvular lesions or vegetations is more limited. ⁷⁸
Detection of infections involving prosthetic valves and cardiovascular implantable electronic devices ⁸⁰	18-FDG PET ⁷⁹	
Congenital and structural heart disease Procedural planning Evaluation of chamber size and flows. ^{80,81}	CMR	Role in detecting small patent foramen ovale is more limited. ⁸²
Ischemic heart disease	<ul style="list-style-type: none"> • Pharmacologic stress echocardiography⁸³ • CCTA • Pharmacologic nuclear myocardial perfusion • CMR perfusion 	Lower risk of aerosol generation than with exercise
Cardiomyopathy and myocarditis	CMR ^{84,85}	Can detect COVID and COVID vaccine myocardial inflammation

CCTA, Cardiac CT angiography; CMR, cardiac magnetic resonance; FDG PET, fluorodeoxyglucose positron emission tomography; LAA, left atrial appendage.

There are currently no noninvasive alternatives to stress echocardiography for assessing exertional valve hemodynamics, diastolic dysfunction, or changes in pulmonary artery pressures.⁸⁶

*It is unclear how potential systemic inflammation from COVID-19 infection may impact FDG PET sensitivity or specificity for detection of endocarditis.

preceding recertification. It is unclear how boards will adjust requirements in future pandemics or whether better surrogates for competence than time and case number can be developed.

Interpretation

COVID-19 has had a significant impact on training in image interpretation in echocardiography as well. With the institution of social distancing measures, there has been an increasing reliance on remote learning platforms. There are obvious advantages of remote learning, including wider accessibility for trainees and flexibility in terms of convenience and timing of access. Furthermore, over the last few years, technology has rapidly evolved to allow interactivity and the reliable use of videos and other multimedia instructional tools to engage learners. Recording of sessions allows for the creation of content repositories.

As remote interpretation and training in echocardiography have evolved, so have concerns regarding the potential negative impact on learning and quality of interpretation. Regarding comparability, remote learning has been shown to be similar in efficacy to in-person instruction, provided a comprehensive and structured approach is followed.⁷³ One study unrelated to echocardiography found that there was increased self-efficacy in research and connection to local space in a field course using online instruction.⁷⁴ However, this did come with a loss of sense of community.

Remote interpretation of echocardiographic images began before the COVID-19 pandemic but has been accelerated based on the need for social distancing and quarantine during the pandemic. Teleinterpretation initially held a promise of enhanced value to remote communities that lack access to expertise and technology. The ASE-REWARD study published in 2013 demonstrated the feasibility and value of this approach.⁷⁵ When social distancing protocols disrupted in-person image interpretation, remote technologies proved valuable in all settings.

There are some limitations of using technology for remote instruction and interpretation. Despite improvements in technology, there are frequent concerns with internet bandwidth, reliability, and variability of video conferencing platforms, in addition to the lack of hands-on instruction. There is also a broad range of learning styles, and online instructional methods may not be equitable for all trainees.

While remote interpretation of images and online instructional techniques are likely to remain in place as we move forward, a blended method is likely the optimal approach. Having the technology and protocols in place to allow image interpretation and instruction remotely will provide laboratories with the necessary flexibility to adapt to changes in COVID protocols, surges in cases, and fluctuating staffing resources.

Key Points

- Training programs should continue to explore hybrid learning models, which involve a mix of in-person, simulator-based, and online instruction that can rapidly adapt to variations in pandemic severity, vaccine availability, and social distancing requirements.
- Technology and protocols should be in place to allow remote image interpretation and instruction.

CONCLUSION

Lessons learned from COVID-19 should inform preparation for future pandemics. This statement addresses echocardiography practice in the current and future pandemics in light of recent and anticipated developments. While knowledge of future developments

remains as elusive as ever, specific indications and decisions about performance of echocardiography services, infection/transmission mitigation strategies, role of cardiac POCUS/CCE, and training in echocardiography remain key areas for planning and preparation.

NOTICE AND DISCLAIMER

This report is made available by the ASE as a courtesy reference source for members. This report contains recommendations only and should not be used as the sole basis to make medical practice decisions or for disciplinary action against any employee. The statements and recommendations contained in this report are primarily based on the opinions of experts, rather than on scientifically verified data. The ASE makes no express or implied warranties regarding the completeness or accuracy of the information in this report, including the warranty of merchantability or fitness for a particular purpose. In no event shall the ASE be liable to you, your patients, or any other third parties for any decision made or action taken by you or such other parties in reliance on this information. Nor does your use of this information constitute the offering of medical advice by the ASE or create any physician-patient relationship between the ASE and your patients or anyone else.

ACKNOWLEDGMENTS

Dr. Adeyinka Adedipe and Dr. Aarti Sarwal contributed as authors representing the Society for Academic Emergency Medicine (SAEM) and the Society of Critical Care Medicine (SCCM), respectively. This document was reviewed by members of the 2023 to 2024 ASE Guidelines and Standards Committee, the ASE Board of Directors, the ASE Executive Committee, and designated reviewers (Himani V. Bhatt, DO, David Dudzinski, MD, Alan Pearlman, MD, Andrew Pellet, PhD, and David A. Orsinelli, MD).

SUPPLEMENTARY DATA

Supplementary data to this article can be found online at <https://doi.org/10.1016/j.echo.2023.08.020>.

REFERENCES

1. Kirkpatrick JN, Mitchell C, Taub C, et al. ASE Statement on protection of patients and echocardiography service providers during the 2019 novel coronavirus outbreak: endorsed by the American College of Cardiology. *J Am Soc Echocardiogr* 2020;33:648-53.
2. Altman CA, Donofrio MT, Arya B, et al. ASE Statement on adapting pediatric, fetal, and congenital heart disease echocardiographic services to the evolving COVID-19 pandemic. *J Am Soc Echocardiogr* 2021;34:553-61.
3. Nicoara A, Maldonado Y, Kort S, et al. Specific considerations for the protection of patients and echocardiography service providers when performing perioperative or periprocedural transesophageal echocardiography during the 2019 novel coronavirus outbreak: Council on Perioperative Echocardiography supplement to the Statement of the American Society of Echocardiography. Endorsed by the Society of Cardiovascular Anesthesiologists. *J Am Soc Echocardiogr* 2020;33:666-9.
4. Mitchell C, Collins K, Hua L, et al. Specific considerations for sonographers when performing echocardiography during the 2019 novel coronavirus outbreak: supplement to the American Society of Echocardiography Statement. *J Am Soc Echocardiogr* 2020;33:654-7.

5. Johri AM, Galen B, Kirkpatrick JN, et al. ASE Statement on point-of-care ultrasound during the 2019 novel coronavirus pandemic. *J Am Soc Echocardiogr* 2020;33:670-3.
6. Hung J, Abraham TP, Cohen MS, et al. ASE Statement on the reintroduction of echocardiographic services during the COVID-19 pandemic. *J Am Soc Echocardiogr* 2020;33:1034-9.
7. Medhane F, Kirkpatrick JN. Echocardiography in the era of COVID-19: lessons for the future. *Curr Cardiol Rep* 2021;23:178.
8. Committee on Guidance for Establishing Crisis Standards of Care for Use in Disaster Situations; Institute of Medicine. *Crisis standards of care: a systems framework for catastrophic disaster response*. Washington (DC): National Academies Press (US); 2012.
9. Figliozzi S, Masci PG, Ahmadi N, et al. Predictors of adverse prognosis in COVID-19: a systematic review and meta-analysis. *Eur J Clin Invest* 2020;50:e13362.
10. Dweck MR, Bularga A, Hahn RT, et al. Global evaluation of echocardiography in patients with COVID-19. *Eur Heart J Cardiovasc Imaging* 2020;21:949-58.
11. Karagodin I, Carvalho Singulane C, Woodward GM, et al. Echocardiographic correlates of in-hospital death in patients with acute COVID-19 infection: the world Alliance societies of echocardiography (WASE-COVID) study. *J Am Soc Echocardiogr* 2021;34:819-30.
12. Giustino G, Croft LB, Stefanini GG, et al. Characterization of myocardial injury in patients with COVID-19. *J Am Coll Cardiol* 2020;76:2043-55.
13. Szekely Y, Lichter Y, Taieb P, et al. Spectrum of cardiac manifestations in COVID-19: a systematic echocardiographic study. *Circulation* 2020;142:342-53.
14. Bader F, Manla Y, Atallah B, et al. Heart failure and COVID-19. *Heart Fail Rev* 2021;26:1-10.
15. Faridi KF, Hennessey KC, Shah N, et al. Left ventricular systolic function and inpatient mortality in patients hospitalized with coronavirus disease 2019 (COVID-19). *J Am Soc Echocardiogr* 2020;33:1414-5.
16. Singh S, Desai R, Gandhi Z, et al. Takotsubo syndrome in patients with COVID-19: a systematic review of published cases. *SN Compr Clin Med* 2020;2:2102-8.
17. Kawakami R, Sakamoto A, Kawai K, et al. Pathological evidence for SARS-CoV-2 as a cause of myocarditis: JACC review Topic of the Week. *J Am Coll Cardiol* 2021;77:314-25.
18. Gaitonde M, Ziebell D, Kelleman MS, et al. COVID-19-related multi-system inflammatory syndrome in children affects left ventricular function and global strain compared with Kawasaki disease. *J Am Soc Echocardiogr* 2020;33:1285-7.
19. Chung MK, Zidar DA, Bristow MR, et al. COVID-19 and cardiovascular disease: from bench to bedside. *Circ Res* 2021;128:1214-36.
20. Creel-Bulos C, Hockstein M, Amin N, et al. Acute cor pulmonale in critically ill patients with COVID-19. *N Engl J Med* 2020;382:e70.
21. Cavaleiro P, Masi P, Bagate F, et al. Acute cor pulmonale in COVID-19 related acute respiratory distress syndrome. *Crit Care* 2021;25:346.
22. Poissy J, Goutay J, Caplan M, et al. ICU Haemostasis COVID-19 Group. Pulmonary embolism in patients with COVID-19: awareness of an increased prevalence. *Circulation* 2020;142:184-6.
23. Huette P, Beyls C, Guilbart M, et al. Acute cor pulmonale in COVID-19-related ARDS: improvement with almitrine infusion. *JACC Case Rep* 2020;2:1311-4.
24. Frost A, Badesch D, Gibbs JSR, et al. Diagnosis of pulmonary hypertension. *Eur Respir J* 2019;53:1801904.
25. Cleverley J, Piper J, Jones MM. The role of chest radiography in confirming covid-19 pneumonia. *BMJ* 2020;370:m2426.
26. Salehi S, Abedi A, Balakrishnan S, et al. Coronavirus disease 2019 (COVID-19): a systematic review of imaging findings in 919 patients. *AJR Am J Roentgenol* 2020;215:87-93.
27. Garrana SH, Som A, Ndakwah GS, et al. Comparison of chest CT findings of COVID-19, influenza, and organizing pneumonia: a multireader study. *AJR Am J Roentgenol* 2021;217:1093-102.
28. Buda N, Segura-Grau E, Cylwik J, et al. Lung ultrasound in the diagnosis of COVID-19 infection - a case series and review of the literature. *Adv Med Sci* 2020;65:378-85.
29. Marini TJ, Rubens DJ, Zhao YT, et al. Lung ultrasound: the essentials. *Radiol Cardiothorac Imaging* 2021;3:e200564.
30. Volpicelli G, Lamorte A, Villén T. What's new in lung ultrasound during the COVID-19 pandemic. *Intensive Care Med* 2020;46:1445-8.
31. Hussain A, Via G, Melniker L, et al. Multi-organ point-of-care ultrasound for COVID-19 (PoCUS4COVID): international expert consensus. *Crit Care* 2020;24:702.
32. Heldeweg MLA, Vermue L, Kant M, et al. The impact of lung ultrasound on clinical-decision making across departments: a systematic review. *Ultrasound J* 2022;14:5.
33. Bozkurt B, Kamat I, Hotez PJ. Myocarditis with COVID-19 mRNA vaccines. *Circulation* 2021;144:471-84.
34. Ammirati E, Frigerio M, Adler ED, et al. Management of acute myocarditis and chronic inflammatory cardiomyopathy: an expert consensus document. *Circ Heart Fail* 2020;13:e007405.
35. Løgstrup BB, Nielsen JM, Kim WY, et al. Myocardial oedema in acute myocarditis detected by echocardiographic 2D myocardial deformation analysis. *Eur Heart J Cardiovasc Imaging* 2016;17:1018-26.
36. Pillay J, Gaudet L, Wingert A, et al. Incidence, risk factors, natural history, and hypothesised mechanisms of myocarditis and pericarditis following covid-19 vaccination: living evidence syntheses and review. *BMJ* 2022;378:e069445.
37. Gargano JW, Wallace M, Hadler SC, et al. Use of mRNA COVID-19 vaccine after reports of myocarditis among vaccine recipients: update from the Advisory Committee on Immunization Practices - United States, June 2021. *MMWR Morb Mortal Wkly Rep* 2021;70:977-82.
38. Carfi A, Bernabei R, Landi F. Gemelli against COVID-19 post-acute care study group. Persistent symptoms in patients after acute COVID-19. *JAMA* 2020;324:603-5.
39. Ayoubkhani D, Khunti K, Nafilyan V, et al. Post-COVID syndrome in individuals admitted to hospital with covid-19: retrospective cohort study. *BMJ* 2021;372:n693.
40. Dennis A, Wamil M, Alberts J, et al. COVERSCAN study investigators. Multiorgan impairment in low-risk individuals with post-COVID-19 syndrome: a prospective, community-based study. *BMJ Open* 2021;11:e048391.
41. Puntmann VO, Carerj ML, Wieters I, et al. Outcomes of cardiovascular magnetic resonance imaging in patients recently recovered from coronavirus disease 2019 (COVID-19). *JAMA Cardiol* 2020;5:1265-73. Erratum in: *JAMA Cardiol*. 2020 Nov 1;5(11):1308.
42. Rajpal S, Tong MS, Borchers J, et al. Cardiovascular magnetic resonance findings in competitive athletes recovering from COVID-19 infection. *JAMA Cardiol* 2021;6:116-8. Erratum in: *JAMA Cardiol*. 2021;6(1):123.
43. Karagodin I, Singulane CC, Descamps T, et al. WASE-COVID Investigators. Ventricular changes in patients with acute covid-19 infection: follow-up of the World Alliance Societies of Echocardiography (WASE-COVID) Study. *J Am Soc Echocardiogr* 2022;35:295-304.
44. Szekely Y, Lichter Y, Sadon S, et al. Cardiorespiratory abnormalities in patients recovering from coronavirus disease 2019. *J Am Soc Echocardiogr* 2021;34:1273-84.e9.
45. Chaturvedi H, Issac R, Sharma SK, et al. Progressive left and right heart dysfunction in coronavirus disease-19: prospective echocardiographic evaluation. *Eur Heart J Cardiovasc Imaging* 2022;23:319-25.
46. Doherty JU, Kort S, Mehran R, et al. ACC/AATS/AHA/ASE/ASNC/HRS/SCAI/SCCT/SCMR/STS 2017 appropriate use criteria for multimodality imaging in valvular heart disease: a report of the American College of cardiology appropriate Use criteria Task Force, American association for Thoracic surgery, American heart association, American society of echocardiography, American society of Nuclear cardiology, heart Rhythm society, society for cardiovascular angiography and interventions, society of cardiovascular computed tomography, society for cardiovascular magnetic resonance, and society of Thoracic Surgeons. *J Am Soc Echocardiogr* 2018 Apr;31:381-404.
47. Doherty JU, Kort S, Mehran R, et al. ACC/AATS/AHA/ASE/ASNC/HRS/SCAI/SCCT/SCMR/STS 2019 appropriate use criteria for multimodality imaging in the assessment of cardiac structure and function in nonvalvular heart disease: a report of the American College of cardiology appropriate Use criteria Task Force, American association for Thoracic surgery, American

- heart association, American society of echocardiography, American society of Nuclear cardiology, heart Rhythm society, society for cardiovascular angiography and interventions, society of cardiovascular computed tomography, society for cardiovascular magnetic resonance, and the society of Thoracic Surgeons. *J Am Soc Echocardiogr* 2019;32:553-79.
48. Campbell RM, Douglas PS, Eidem BW, et al. American College of Cardiology appropriate Use criteria Task Force; American Academy of pediatrics; American heart association; American society of echocardiography; heart Rhythm society; society for cardiovascular angiography and interventions; society of cardiovascular computed tomography; society for cardiovascular magnetic resonance; society of pediatric echocardiography. ACC/AAP/AHA/ASE/HRS/SCAI/SCCT/SCMR/SOPE 2014 appropriate use criteria for initial transthoracic echocardiography in outpatient pediatric cardiology: a report of the American College of Cardiology appropriate Use criteria Task Force, American Academy of pediatrics, American heart association, American society of echocardiography, heart Rhythm society, society for cardiovascular angiography and interventions, society of cardiovascular computed tomography, society for cardiovascular magnetic resonance, and society of pediatric echocardiography. *J Am Soc Echocardiogr* 2014;27:1247-66.
 49. Douglas PS, Garcia MJ, Haines DE, et al. ACCF/ASE/AHA/ASNC/HFSA/HRS/SCAI/SCCM/SCCT/SCMR 2011 appropriate use criteria for echocardiography. A report of the American College of cardiology foundation appropriate Use criteria Task Force, American society of echocardiography, American heart association, American society of Nuclear cardiology, heart failure society of America, heart Rhythm society, society for cardiovascular angiography and interventions, society of critical care medicine, society of cardiovascular computed tomography, society for cardiovascular magnetic resonance American College of chest physicians. *J Am Soc Echocardiogr* 2011;24:229-67.
 50. Ward RP, Lee L, Ward TJ, et al. Utilization and appropriateness of transthoracic echocardiography in response to the COVID-19 pandemic. *J Am Soc Echocardiogr* 2020;33:690-1.
 51. Jain S, Venkataraman A, Wechsler ME, et al. Messenger RNA-based vaccines: past, present, and future directions in the context of the COVID-19 pandemic. *Adv Drug Deliv Rev* 2021;179:114000. Erratum in: *Adv Drug Deliv Rev*. 2022 Oct;189:114501.
 52. Polack FP, Thomas SJ, Kitchin N, et al. C4591001 clinical trial group. Safety and efficacy of the BNT162b2 mRNA covid-19 vaccine. *N Engl J Med* 2020;383:2603-15.
 53. Baden LR, El Sahly HM, Essink B, et al., COVE Study Group. Efficacy and safety of the mRNA-1273 SARS-CoV-2 vaccine. *N Engl J Med* 2021;384:403-16.
 54. Tenforde MW, Weber ZA, Natarajan K, et al. Early estimates of bivalent mRNA vaccine effectiveness in preventing COVID-19-associated emergency department or urgent care encounters and hospitalizations among immunocompetent adults - VISION Network, Nine States, September-November 2022. *MMWR Morb Mortal Wkly Rep* 2023;71:1637-46.
 55. Baker RE, Park SW, Yang W, et al. The impact of COVID-19 nonpharmaceutical interventions on the future dynamics of endemic infections. *Proc Natl Acad Sci U S A* 2020;117:30547-53.
 56. Skulstad H, Cosyns B, Popescu BA, et al. COVID-19 pandemic and cardiac imaging: EACVI recommendations on precautions, indications, prioritization, and protection for patients and healthcare personnel. *Eur Heart J Cardiovasc Imaging* 2020;21:592-8.
 57. Zoghbi WA, DiCarli MF, Blankstein R, et al. ACC Imaging Council. Multimodality cardiovascular imaging in the midst of the COVID-19 pandemic: ramping up safely to a new normal. *JACC Cardiovasc Imaging* 2020;13:1615-26.
 58. Moore CL, Copel JA. Point-of-care ultrasonography. *N Engl J Med* 2011;364:749-57.
 59. Diaz-Gómez JL, Mayo PH, Koenig SJ. Point-of-Care ultrasonography. *N Engl J Med* 2021;385:1593-602.
 60. Huang G, Vengerovsky A, Morris A, et al. Development of a COVID-19 point-of-care ultrasound protocol. *J Am Soc Echocardiogr* 2020;33:903-5.
 61. American College of Emergency Physicians. Emergency ultrasound guidelines. *Ann Emerg Med* 2009;53:550-70.
 62. Frankel HL, Kirkpatrick AW, Elbarbary M, et al. Guidelines for the appropriate use of bedside general and cardiac ultrasonography in the evaluation of critically ill patients-part i: general ultrasonography. *Crit Care Med* 2015;43:2479-502.
 63. Panebianco NL, Mayo PH, Arntfield RT, et al. Assessing competence in critical care echocardiography: development and initial results of an examination and certification processes. *Crit Care Med* 2021;49:1285-92.
 64. Morales G, Adedipe A, Morse S, et al. Feasibility of very early identification of cardiogenic shock by semi-automated ultrasound exam in the emergency department. *Cureus* 2022;14:e30927.
 65. Nti B, Lehmann AS, Haddad A, et al. Artificial intelligence-augmented pediatric lung POCUS: a pilot study of novice learners. *J Ultrasound Med* 2022;41:2965-72.
 66. Thompson B, Schoenfeld E, Westafer L, et al. Implementation of an automated, user-centered point-of-care ultrasound workflow improves documentation and billing. *Acad Emerg Med* 2023;30:180-6.
 67. Rong K, Chimileski B, Kaloudis P, et al. Impact of an epic-integrated point-of-care ultrasound workflow on ultrasound performance, compliance, and potential revenue. *Am J Emerg Med* 2021;49:233-9.
 68. Ehler D, Carney DK, Dempsey AL, et al. American society of echocardiography sonographer training and education committee. Guidelines for cardiac sonographer education: recommendations of the American society of echocardiography sonographer training and education committee. *J Am Soc Echocardiogr* 2001;14:77-84.
 69. Ryan T, Berlacher K, Lindner JR, et al. COCATS 4 Task Force 5: training in echocardiography. *J Am Coll Cardiol* 2015;65:1786-99.
 70. Wieggers SE, Ryan T, Arrighi JA, et al. 2019 ACC/AHA/ASE advanced training statement on echocardiography (revision of the 2003 ACC/AHA clinical competence statement on echocardiography): a report of the ACC Competency Management Committee. *J Am Soc Echocardiogr* 2019;32:919-43.
 71. Durham CF, Alden KR. Enhancing patient safety in nursing education through patient simulation. In: Hughes RG, editor. Patient safety and quality: an evidence-based handbook for nurses. Rockville (MD): Agency for Healthcare Research and Quality (US); 2008 Apr. Chapter 51.
 72. Kuehn BM. COVID-19 leads to major changes for cardiologists in training. *Circulation* 2020;142:175-7.
 73. Jackson R, Brotherston D, Jain A, et al. Teaching ultrasound at the point of care in times of social distancing. *ATS Sch* 2021;2:341-52.
 74. Race AJ, De Jesus M, Beltran RS, et al. A comparative study between outcomes of an in-person versus online introductory field course. *Ecol Evol* 2021;11:3625-35.
 75. Singh S, Bansal M, Maheshwari P, et al. ASE-REWARD Study Investigators. American Society of Echocardiography: remote echocardiography with web-based assessments for referrals at a distance (ASE-REWARD) Study. *J Am Soc Echocardiogr* 2013;26:221-33.
 76. Korsholm K, Berti S, Iriart X, et al. Expert recommendations on cardiac computed tomography for planning transcatheter left atrial appendage occlusion. *JACC Cardiovasc Interv* 2020;13:277-92.
 77. Khalique OK, Veillet-Chowdhury M, Choi AD, et al. Cardiac computed tomography in the contemporary evaluation of infective endocarditis. *J Cardiovasc Comput Tomogr* 2021;15:304-12.
 78. Dursun M, Yilmaz S, Yilmaz E, et al. The utility of cardiac MRI in diagnosis of infective endocarditis: preliminary results. *Diagn Interv Radiol* 2015;21:28-33.
 79. Yan J, Zhang C, Niu Y, et al. The role of 18F-FDG PET/CT in infectious endocarditis: a systematic review and meta-analysis. *Int J Clin Pharmacol Ther* 2016;54:337-42.
 80. Fratz S, Chung T, Greil GF, et al. Guidelines and protocols for cardiovascular magnetic resonance in children and adults with congenital heart disease: SCMR expert consensus group on congenital heart disease. *J Cardiovasc Magn Reson* 2013;15:51.
 81. Sachdeva R, Valente AM, Armstrong AK, et al. Appropriate Use criteria Task Force; ACC/AHA/ASE/HRS/ISACHD/SCAI/SCCT/SCMR/SOPE 2020 appropriate use criteria for multimodality imaging during the follow-up care of patients with congenital heart disease: a report of the American College of cardiology solution set

- Oversight committee and appropriate Use criteria Task Force, American heart association, American society of echocardiography, heart Rhythm society, international society for adult congenital heart disease, society for cardiovascular angiography and interventions, society of cardiovascular computed tomography, society for cardiovascular magnetic resonance, and society of pediatric echocardiography. *J Am Soc Echocardiogr* 2020;33:e1-48.
82. Silvestry FE, Cohen MS, Armsby LB, et al. American society of echocardiography; society for cardiac angiography and interventions. Guidelines for the echocardiographic assessment of atrial septal defect and patent foramen ovale: from the American society of echocardiography and society for cardiac angiography and interventions. *J Am Soc Echocardiogr* 2015; 28:910-58.
 83. Gulati M, Levy PD, Mukherjee D, et al. 2021 AHA/ACC/ASE/CHEST/SAEM/SCCT/SCMR guideline for the evaluation and diagnosis of chest pain: executive summary: a report of the American College of cardiology/American heart association joint committee on clinical practice guidelines. *J Am Coll Cardiol* 2021;78:2218-61.
 84. Petersen SE, Friedrich MG, Leiner T, et al. Cardiovascular magnetic resonance for patients with COVID-19. *JACC Cardiovasc Imaging* 2022;15:685-99.
 85. Samimisedeh P, Jafari Afshar E, et al. Cardiac MRI findings in COVID-19 vaccine-related myocarditis: a pooled analysis of 468 patients. *J Magn Reson Imaging* 2022;56:971-82.
 86. Lancellotti P, Pellikka PA, Budts W, et al. The clinical use of stress echocardiography in non-ischaemic heart disease: recommendations from the European Association of Cardiovascular Imaging and the American Society of Echocardiography. *J Am Soc Echocardiogr* 2017;30:101-38.
 87. Shen WK, Sheldon RS, Benditt DG, et al. 2017 ACC/AHA/HRS guideline for the evaluation and management of patients with syncope: a report of the American College of cardiology/American heart association Task Force on clinical practice guidelines and the heart Rhythm society. *J Am Coll Cardiol* 2017;70:e39-110. Erratum in: *J Am Coll Cardiol*. 2017 Oct 17;70(16):2102-2104.
 88. American College of Surgeons. COVID-19: guidance for triage of non-emergent surgical procedures. elective surgery acuity scale (ESAS). <https://www.facs.org/covid-19/clinical-guidance/triage>. Accessed June 29, 2023.



- Acquire valuable information**
- Share experiences**
- Engage all over the world**
- Contribute to the conversation**
- Hear from top echo experts**
- Obtain connections**



Appendix 1

Guidance for triage of non-emergent outpatient transthoracic echocardiograms during the Covid-19 pandemic (March 2020) Thomas Jefferson University, Philadelphia, PA

Tiers	Definition	Effect on treatment	Examples	Action
Tier 1a	Low acuity/asymptomatic patient Not life threatening	Results will not affect short-term treatment or outcome	<ul style="list-style-type: none"> • All routine surveillance without change in clinical status, e.g., severe valve disease, prosthetic valves, aortic disease, or cardiomyopathy • Asymptomatic, abnormal ECG 	Postpone study
Tier 1b	Low acuity/symptomatic patient Not life threatening	Results will not affect short-term treatment or outcome	<ul style="list-style-type: none"> • Syncope, low suspicion cardiac cause • New onset atrial fibrillation, asymptomatic • Pre-solid organ (non-urgent) transplant 	Postpone study
Tier 2a	Intermediate acuity/asymptomatic patient Not life threatening but potential for future morbidity and mortality	Results will affect medium-term treatment or outcome	<ul style="list-style-type: none"> • Newly discovered murmur with need for urgent non-cardiac surgery • Follow-up severe valvular heart disease without symptoms • Follow-up RV function post pulmonary embolism; LV function post takotsubo; pericardial effusion 	Expert consultation*/consider need for study vs. postpone
Tier 2b	Intermediate acuity/symptomatic patient Not life threatening but potential for future morbidity and mortality	Results will affect medium-term treatment or outcome	<ul style="list-style-type: none"> • Known heart or lung disease with new symptoms • HFrEF where EF determines medical or device therapy 	Expert consultation*/do not postpone study

			<ul style="list-style-type: none"> • Evaluation post OHT e.g., rejection 	
Tier 3	High acuity/symptomatic or asymptomatic patient Potentially life threatening	Results will affect short-term treatment or outcome	<ul style="list-style-type: none"> • New symptoms consistent with significant cardiopulmonary disease • Echo needed for continuation of chemotherapy • Concern for significant pericardial effusion/tamponade 	Do not postpone





ECG, electrocardiogram; EF, ejection fraction; HFrEF, heart failure with reduced ejection fraction; LV, left ventricle; OHT, orthotopic heart transplant; RV, right ventricular.

*Expert consultation refers to review by an echocardiography attending physician and discussion with the referring health care professional if needed.

Adapted from the American College of Surgeons Elective Surgery Acuity Scale (ESAS) ref 89.

Appendix 2

Guidance for triage of non-emergent outpatient transthoracic echocardiograms during the Covid-19 pandemic (April 2020) Lyndon B. Johnson General Hospital/University of Texas Health

Level of urgency	Clinical situations and diagnoses
<p>I: Do not delay, or schedule sooner</p> <p> Green Dot</p>	<p>Intermediate acuity symptomatic patient, high acuity symptomatic or asymptomatic patient, potentially life threatening, results may affect outcomes in <30 days.</p> <p>Examples:</p> <ul style="list-style-type: none"> • Severe symptomatic valvular or myocardial disease • New symptoms c/w significant cardiopulmonary disease • Concern for significant pericardial effusion/tamponade • New HFrEF with EF <35% and where decision for ICD is needed. • Recent MI or cardiac arrest when follow-up TTE is indicated
<p>IIA: Delay, but should be future scheduling priority (message ordering physician in Epic, could potentially become urgent)</p> <p> Yellow Dot</p>	<p>Intermediate acuity asymptomatic patient, results may affect medium to long term outcomes, potentially higher level of urgency depending on non-cardiac factors.</p> <p>Examples:</p> <ul style="list-style-type: none"> • Cardio-oncology patients (chemo) not meeting criteria in I • Pregnant patients not meeting criteria in I • Severe valvular or myocardial disease, symptoms unclear • Preop for urgent surgery (discuss with ordering)
<p>IIB: Delay, but should be future scheduling priority</p> <p> Orange Dot</p>	<p>Intermediate acuity asymptomatic patient, results may affect medium to long term outcomes, level of urgency appears fairly clear from chart review.</p> <ul style="list-style-type: none"> • Severe valvular or myocardial disease, clearly asymptomatic per chart review, no echo <1 year • Moderate valvular or myocardial disease, no echo <2 years • Follow-up RV function, PAH in patients with no echo <1 year
<p>III: Ok to delay for at least 60 days</p> <p> Red Dot</p>	<p>Low acuity TTE, potentially inappropriate or uncertain indications, results unlikely to affect medium to long term outcomes.</p> <p>Examples:</p> <ul style="list-style-type: none"> • Syncope, low suspicion for cardiac cause • New murmur, asymptomatic • Mild valvular disease • Arrhythmias, asymptomatic • HTN, DM, “preop” for clearly elective surgery

DM, diabetes mellitus; EF, ejection fraction; HF_rEF, heart failure with reduced ejection fraction; HTN, hypertension; ICD, implantable cardioverter-defibrillator; MI, myocardial infarction; PAH, pulmonary arterial hypertension; RV, right ventricular; TTE, transthoracic echocardiography.

Appendix 3

Triaging of echocardiography procedure orders (January 2022)

University of Washington, Seattle, WA

Question	If yes
1. Is the indication considered “rarely appropriate” or “inappropriate” by appropriate use criteria?	Cancel
2. Even if appropriate, is the indication “routine”?	Postpone, unless there are extenuating circumstances (e.g., travel from distance or other patient hardships)
3. Can the echocardiogram wait until the patient is out of COVID quarantine?	Postpone
4. Is the order “stat”, “emergent”, or “urgent”?	Performed with appropriate PPE, limited protocol
5. Is the patient at risk of an adverse event (morbidity, mortality, including ED visit and hospitalization) in the next 2-6 weeks if: <ul style="list-style-type: none"> • Echocardiographic <u>detection of suspected pathology</u> does not occur? • Echocardiographic <u>diagnosis of the cause of symptoms</u> is not made? • Echocardiographic <u>characterization of known pathology</u> does not occur? • Echocardiographic <u>follow-up of known lesion(s) to assess for worsening</u> is not performed? 	Perform
6. Is the exam necessary for the patient to receive a <u>life-sustaining or significant morbidity-reducing intervention</u> in the next 6 weeks (e.g., stress echo prior to organ transplant)?	Perform

COVID, coronavirus disease; ED, emergency department; PPE, personal protective equipment.

Note: TEEs, TEE-DCCV and stress testing will be performed for patients without known or suspected COVID, with appropriate pre-procedure screening and testing.

Note: For patients who are known to have COVID, current guidelines for return to ambulatory care will be applied to outpatient echocardiograms